

NEOBIOTECH

USER'S
CLINICAL
CASES

**Neo
Biotech**
Satisfaction to Dentists

Publications

Surgical

GBR (Vertical & Lateral)	6
Sinus Lift	24
Immediate / Early / AnyTime Loading	40
Implant Placement in the esthetic zone	48
Soft tissue graft / Management	60

Restorative

SCRIP	80
Anterior esthetic restoration	92
Posterior zirconia restoration	106
Full mouth rehabilitation	122
Over denture	134

Implant complications

Prevention of peri-implantitis	142
Atraumatic implant removal	154
Fractured screw removal	162

Digital implantology

Custom abutment / Intraoral scanning	170
Surgical Guide	182



Surgical

GBR (Vertical & Lateral)

Sinus Lift

Immediate / Early / AnyTime Loading

Implant Placement in the esthetic zone

Soft tissue graft / Management

Reduction Crestal- Alveoloplasty with Sinus Graft

Dr. Young-Ku Heo
DDS, MSD, Ph.D



QR Code by Case

Patient information

A 33-year-old, medically healthy patient.

Treatment Plan

1. Left side sinus graft with lateral approach and an 8 month waiting period for healing.
2. Sinus graft and implant placement #26 #27.
3. Implant placement #22, #35, #37, #45, #46, #47.
4. Implant placement after reduction of inferior part of the residual bone.
5. Restore all then teeth except #41, #42, #43.

Tool that used in surgery

IS-II active, Sinus All Kit, Trepine Drill

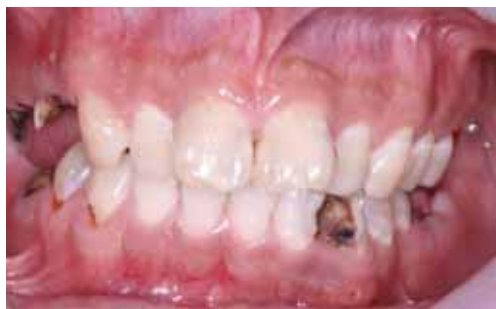

Fig.1 Front view in occlusion.

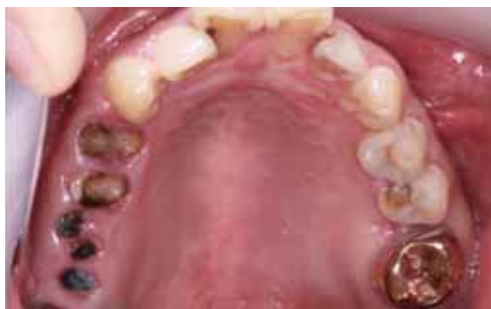

Fig.2 On the occlusal view, rampant caries were observed.

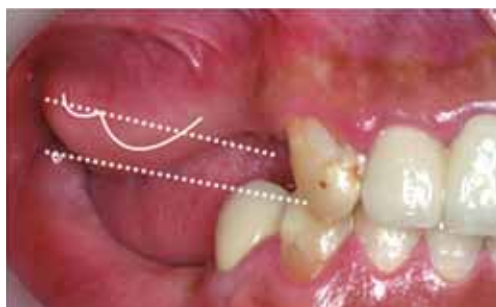


Fig.3 Lateral view of the right side in occlusion. Because of down growth of the maxillary posterior edentulous ridge (mostly from pneumatization of the maxillary sinus) and overgrowth of mandibular posterior edentulous area, inter-occlusal clearance was insufficient for any type of restorations in the maxilla and mandible. Reduction alveoloplasty of the maxilla was planned after sinus graft.

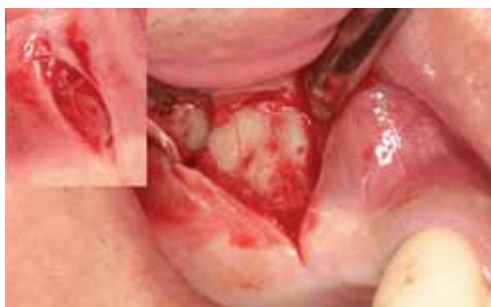

Fig.4 A small vertical incision was made and the periosteum was raised so that the sinus lateral wall can be seen.

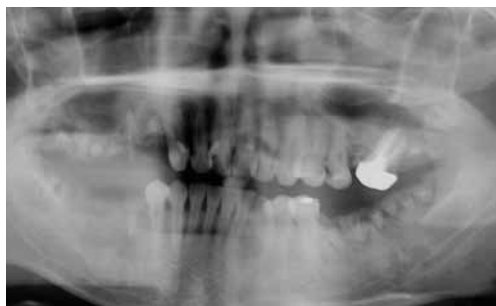

Fig.5 Initial panoramic radiograph 4 years before starting the treatment. Many root rests were seen.

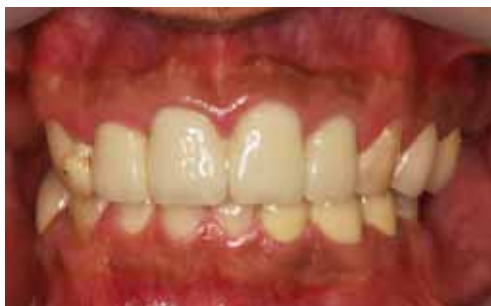

Fig.6 Clinical photograph 4 years later. Dental caries on #13 and 23 were observed due to the patient's poor oral hygiene. Maxillary anterior teeth also had secondary caries underneath the crowns.

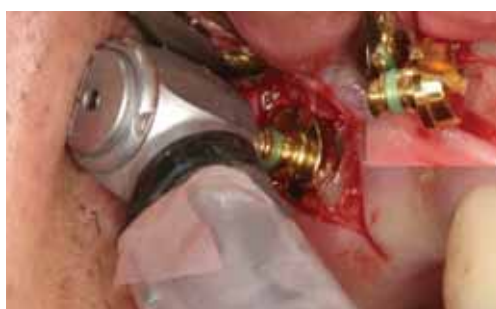

Fig.7 The LS-reamer was used to make a lateral hole. The reamer should be tilted side to side for depth control while the operator should watch carefully the osteotomy site. When it gets closer to the sinus membrane, the color becomes bluish or dark.

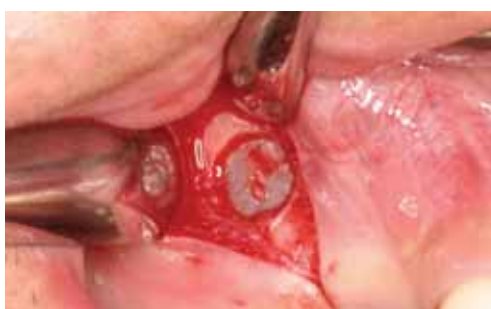

Fig.8 A lateral window was made in 30 seconds. In this case, the sinus membrane was exposed without a thin bony disk. If one wants to make a thin bony disk above the sinus membrane, he/ she should push the reamer a little harder during the drilling.

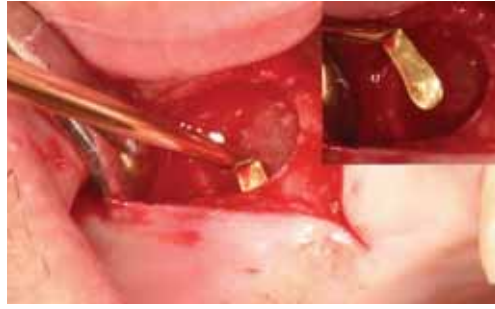

Fig.9 Using the 90 angle part of the #02 elevator, the sinus membrane on the inferior part of the lateral wall was detached.

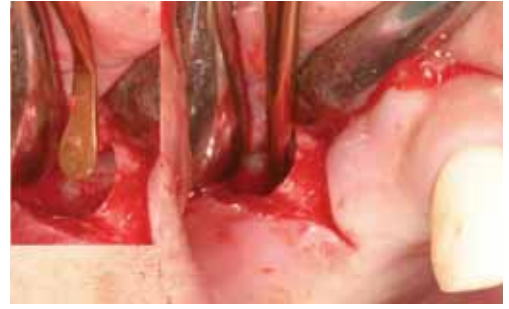

Fig.10 The membrane over the sinus floor was detached with the 30 degree angle part of the #02 elevator.

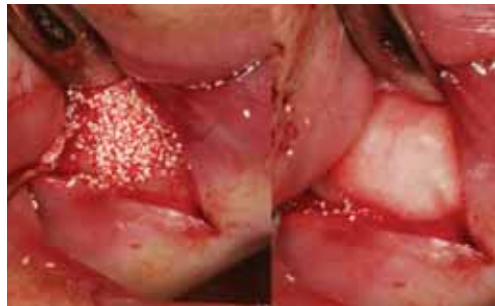

Fig.11 Two kinds of alloplastic graft materials (DM bone made of 2cc coral and 2cc Calpore) were added to the sinus graft. (Left)
The lateral window was covered with a resorbable collagen membrane. (Lyoplast) (Right)

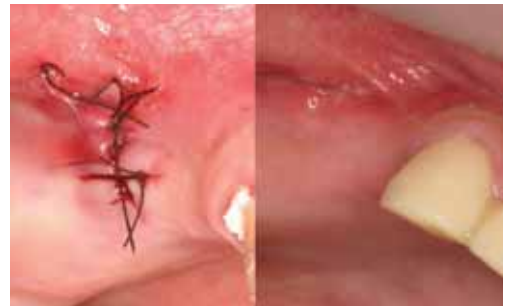

Fig.12 Simple interrupted sutures were made along the vertical incision. (Left)
The incision site was completely healed in 10 days without pain and swelling. (Right)

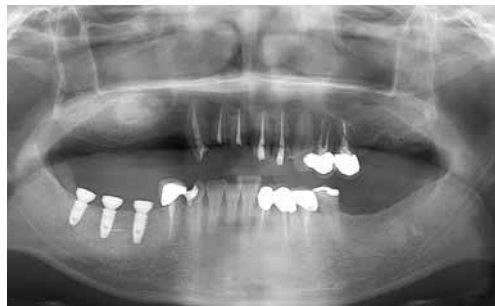


Fig.13 A panoramic radiograph after the sinus graft. The remaining bone height was only 1mm. The lower part of the yellow line will be cut off after 8-9 months for creating interocclusal space.

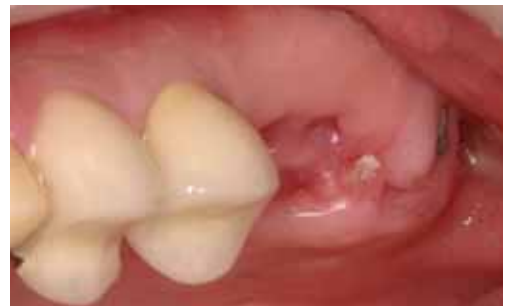

Fig.14 Occlusal view of left maxillary posterior area. Root rests were extracted 3 weeks previously.

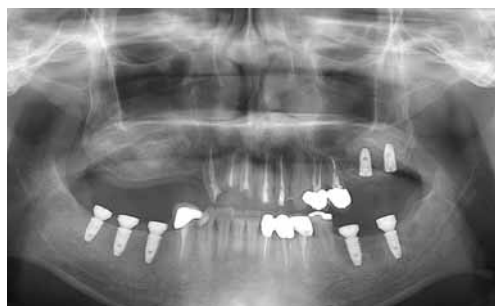

Fig.15 Panoramic radiograph after sinus graft and simultaneous implant placement. From only 1-2mm remaining bone 15 and 25 Ncm insertion torque for #26 and 27 implants, respectively, were obtained. Seven to eight months healing time was planned.

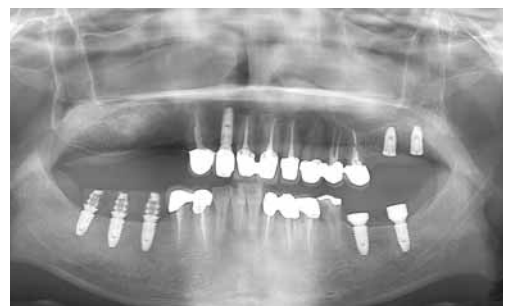

Fig.16 A panoramic view seven months after the sinus graft on the left side.

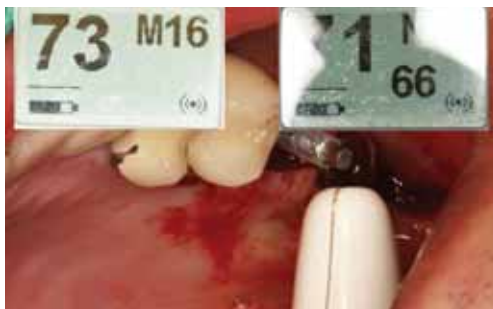

Fig.17 #26 and 27 was uncovered in seven months. Implant stabilities were measured with Ostell Mentor. ISQs were 73 and 71 for #26 and 27, respectively.

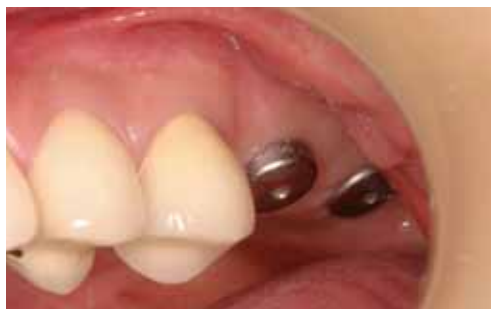

Fig.18 One month after the 2nd surgery.

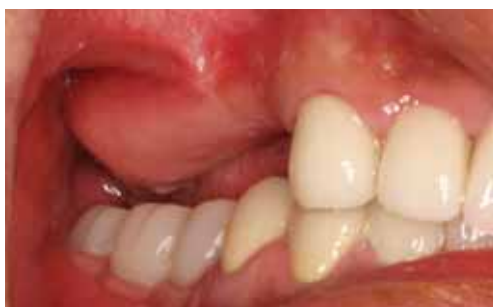

Fig.19 A 3 unit-provisional restoration on implants #45, 46 and 47 was delivered to see how much inter-occlusal space was needed.

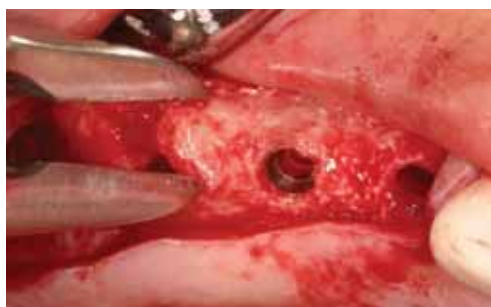

Fig.20 9 months after the sinus graft in the left sinus. Some part of the alveolar ridge was removed to increase interocclusal space with bone rongeur.

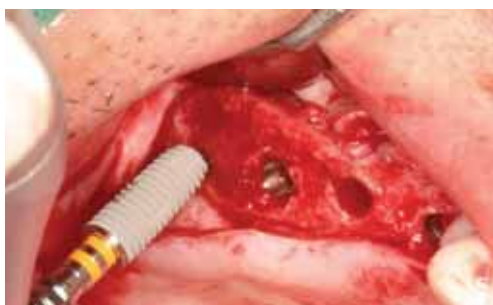

Fig.21 5.0x13mm long and wide implants were placed in the only grafted site. There was no original residual bone left.

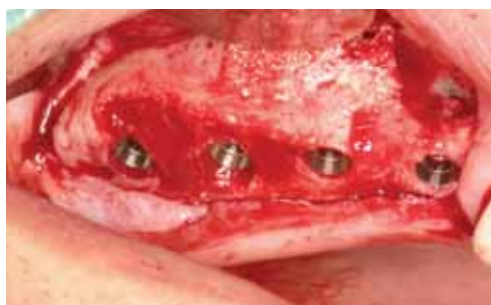

Fig.22 4 implants were placed successfully. The lateral wall where the bone graft was performed was completely filled with new bone-like material. The apical area of the #14 implant had severe concavity, so a bone graft was performed.

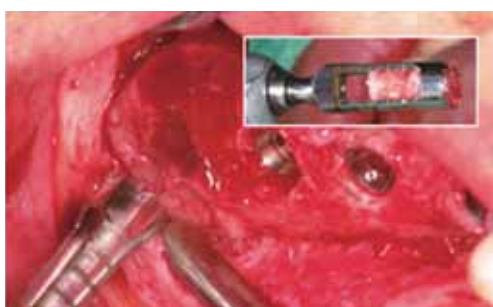


Fig.23 A trephine drill was used to harvest some grafted bone in the 3rd molar area. Inset: Harvested bone with a trephine drill. The bone density was D3-2.

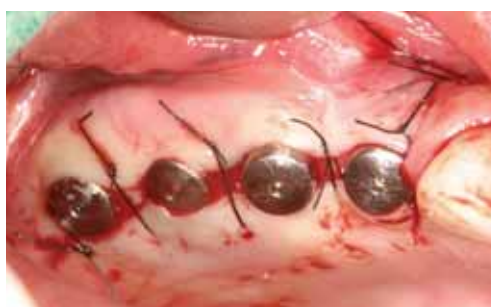

Fig.24 The one stage approach was applied. The implant fixation was charted as ' D322 with 40 Ncm, D333 with 25 Ncm, D334 with 25 Ncm and D334 with 25 Ncm for implant #14, 15, 16, and 17, respectively.

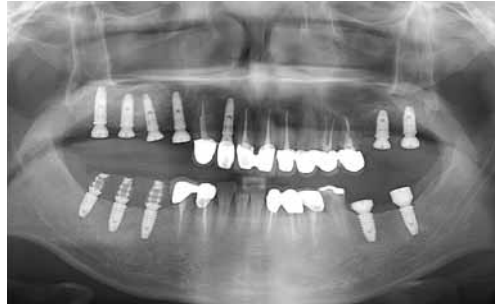

Fig.25 Panoramic view after the implants were placed in the right posterior maxilla 9 months after the graft. The crestal bone level was corrected, and the interocclusal space was secured.

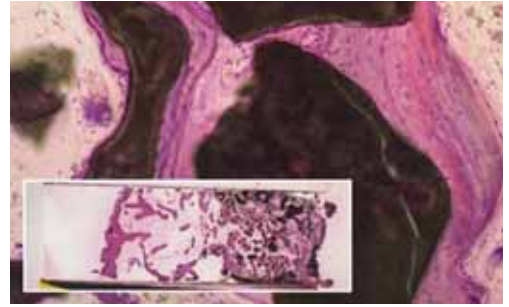


Fig.26 A histology of the biopsy shows favorable bony remodelling around the graft material.

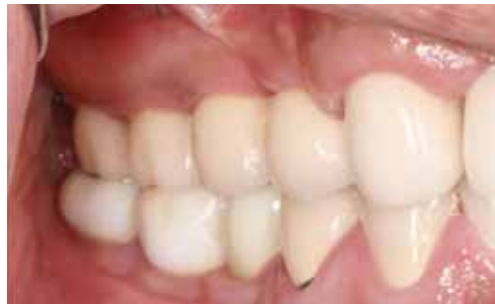

Fig.27 Buccal view of the right side. Favorable occlusal plane and interocclusal spaces were provided.

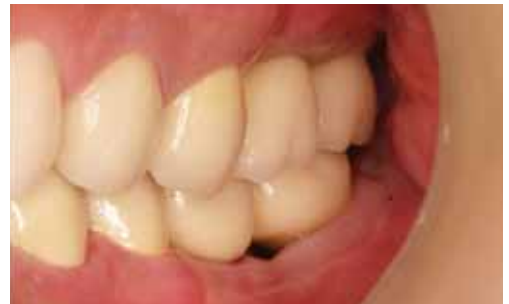

Fig.28 Buccal view of the left molar area.

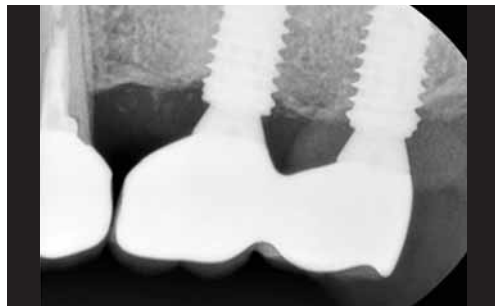


Fig.29 Delivery of the restorations.

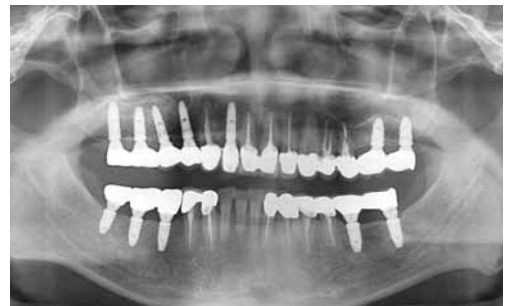

Fig.30 2 year follow-up panoramic x-ray reveals well maintained marginal bone levels around implants. In the maxillary right posterior area, the implants have functioned well for 2 years in spite of grafted bone only.

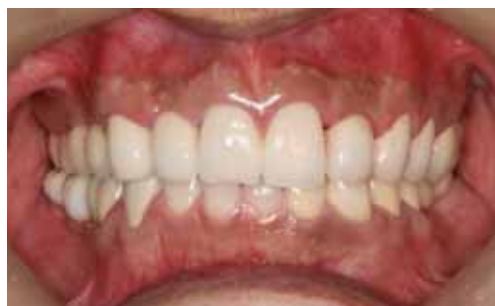

Fig.31 Final result of the treatment. It took about 14 months to finish.




Fig.32 Delivery of the restorations.

Immediate Placement with Sinus Class IV CM/C Fixation Using SLA Technique

Dr. Chonghwa Kim
DDS, MS



QR Code by Case

Patient Information

A 64-year-old male hypertension, diabetes, and previous myocardial infarction. Hypertension and diabetes were controlled with exercise and diet, but he had a stent in his heart, and had taken aspirin. He had poor oral hygiene and generalized periodontitis.

Treatment Plan

1. General periodontal treatment before surgery.
2. Sinus bone augmentation with SLA technique.
3. Implant placement in #16 and 17 right after extraction of #17 at the time of sinus graft. (Class IV CM/C fixation)

Tool that used in surgery

EB fixture, Neo Surgical Kit, SLA Kit

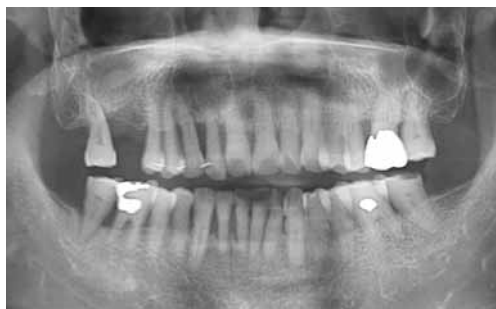

Fig.1 Initial panoramic view: severe pneumatization of right maxillary sinus and periodontally compromised teeth #17, 12, 46 and 47 were observed.

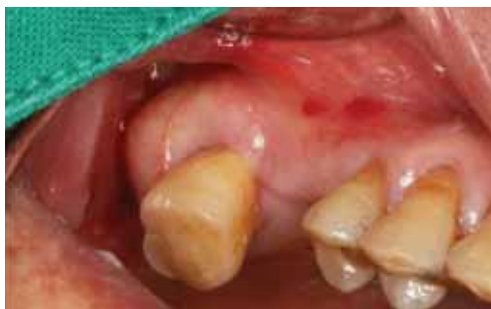

Fig.2 A picture before surgery (after anesthesia). It shows abundant keratinized gingiva. Deep periodontal pockets existed in the buccal (7mm) and lingual (8mm) sides.

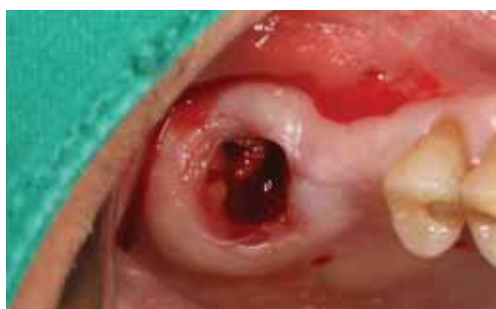

Fig.3 #17 was extracted and thoroughly cleaned up.

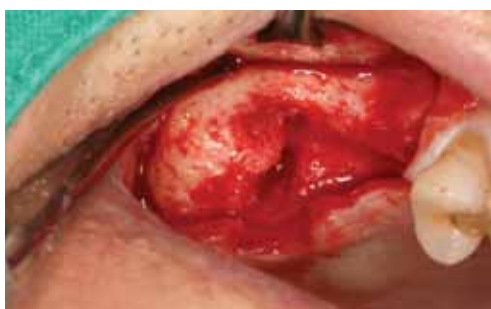

Fig.4 Full thickness flap with papilla preserving incision was made. For autogenous bone collection from maxillary tuberosity, flap was extended to the posterior part with No. 12 blade. Horizontal incision was slightly inclined to the palatal side so as not to disturb drilling.

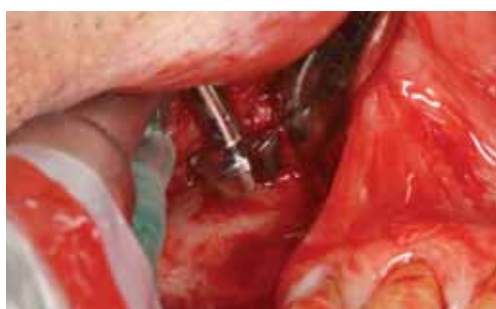

Fig.5 Ø6.5mm LS-reamer was located at the lowest area of the sinus floor between #16 and #17 so that it was easy to elevate the membrane from the bottom of the sinus. It is better to hold the hand piece firmly as the reamer tends to wobble during drilling.

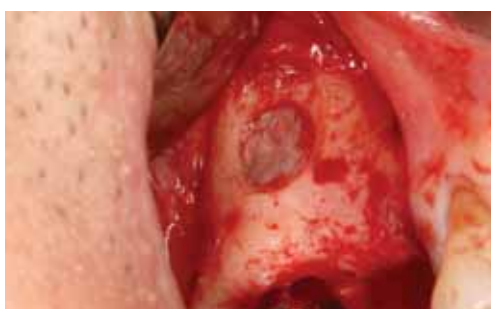

Fig.6 A bony window was made about 5mm superior to the crestal part of #16,17. The Schneiderian membrane was clearly seen with some piece of thin bony wall. Even though the membrane was contacted by the reamer directly during drilling with more than 2000 rpm, it was still safe from membrane tearing. The membrane was elevated with microelevators from the SLA kit.

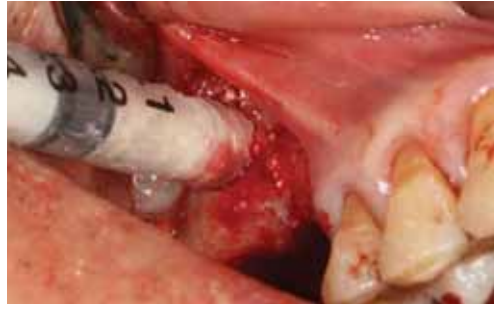

Fig.7 Sufficiently hydrated syringe type RegenOss (Cellumed, Seoul Korea) was grafted under the elevated membrane. The posterior area of the sinus was filled first, the anterior part second, and the center last. There can be a void at the anterior part because the patient is in a supine position. It can be helpful to push the bone graft material to the anterior direction to prevent void formation.

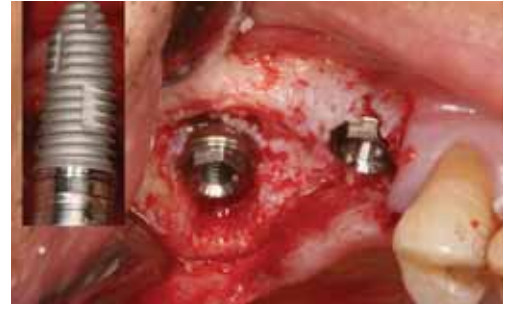

Fig.8 Initial stability of #16 and 17 implant was about 40 Ncm. The bone defect around implant #17 is observed.

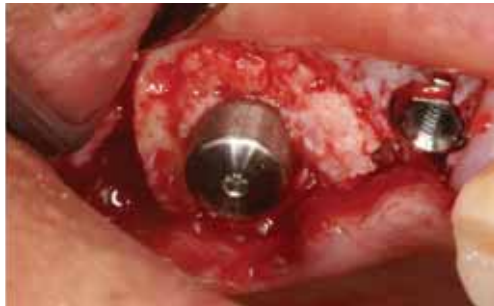

Fig.9 Autogenous bone collected from a maxillary tuberosity was filled between extraction socket and implant after healing abutment connection.

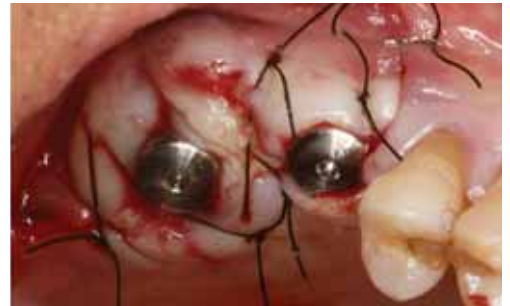

Fig.10 A clinical view after surgery. The one-stage approach was performed. The extraction socket was completely closed by management of soft tissue.

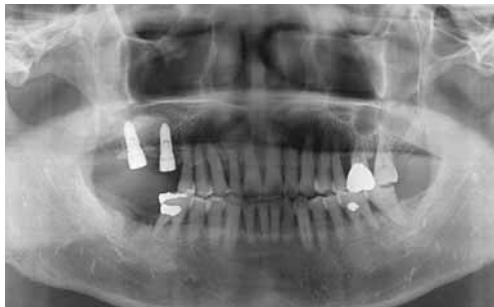

Fig.11 A panoramic x-ray after surgery. Well-grafted, dome-shape bone graft material around #16 and #17 implant can be observed.

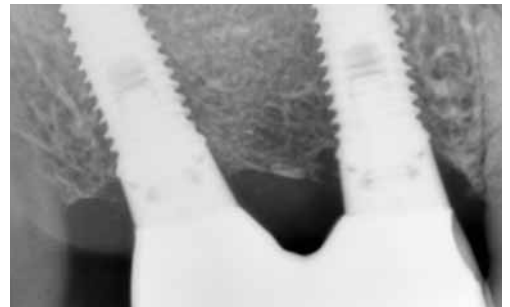


Fig.12 A periapical x-ray at the delivery of a definitive prosthesis (2 unit PFM SCR) 4 months after the surgery.

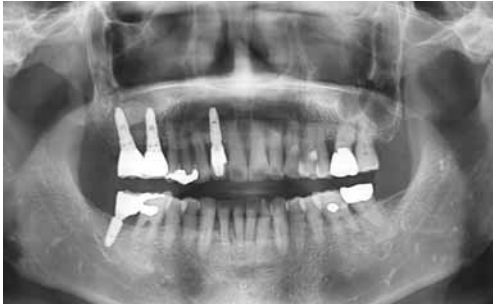

Fig.13 While waiting for the healing time, implants in the #12 and 47 area were placed and delivered at the same time. A panoramic x-ray at the delivery of a definitive prosthesis. (2 unit PFM SCRPs)

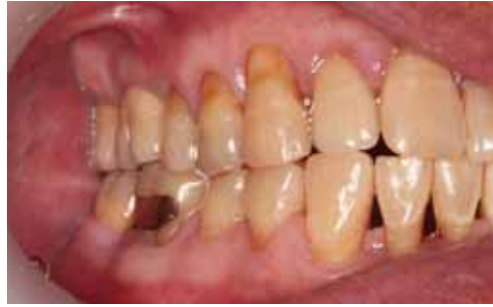

Fig.14 Buccal view of left side in centric occlusion.

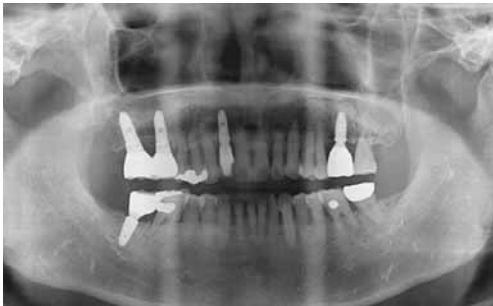

Fig.15 Radiograph after 2 years. Bone graft material seemed to have matured well, and remodeling of the sinus floor is clearly seen.

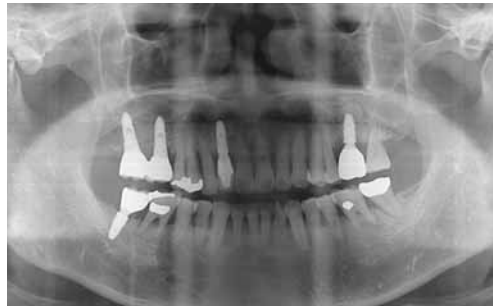


Fig.16 8 year follow-up radiograph after the surgery. The sinus floor has been modified by remodeling. No other specific change can be seen.

GBR and simultaneous implant placement in the narrow alveolar ridge



Dr. Nam Yoon Kim
DDS, MSD, Ph.D



QR Code by Case

Patient Information

A 53-year-old female patient had a fixed bridge on site 23-26 and presented with secondary caries on #26.

Treatment Plan

1. Extraction of the tooth #26 8-week prior to implant surgery.
2. #26 Class III Sinus augmentation by the crestal approach using SCA kit. (Neobiotech)
3. Implant placement of #24, 25 and 26 with simultaneous guided bone regeneration using CTi-memb + Xenograft.
4. Uncovering at 4 months after the implant placement.
5. Delivery of final prosthesis with pre-fabricated abutment & a 3-unit PFM FPD.

Tool that used in surgery

IS-II active, Neo Surgical Kit, SCA Kit, CTi-mem, CTi-spacer, Fixing Screw

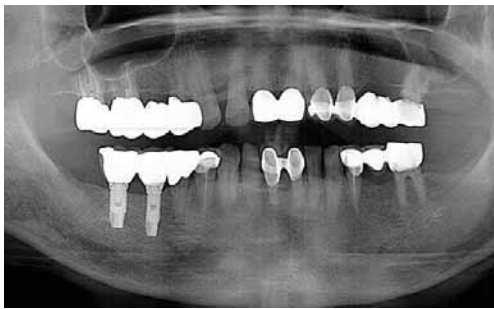


Fig.1 A 53-year-old female patient had a fixed bridge on site #23-26 and presented with secondary caries on #26.

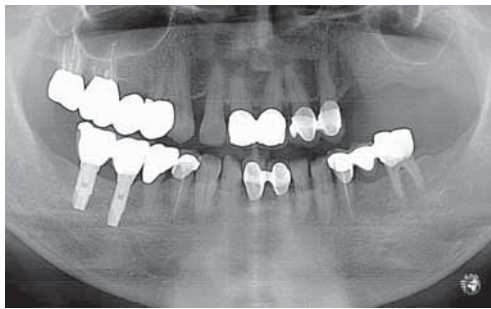


Fig.2 The treatment plan provided for a 8-week period to allow the extraction socket to heal.

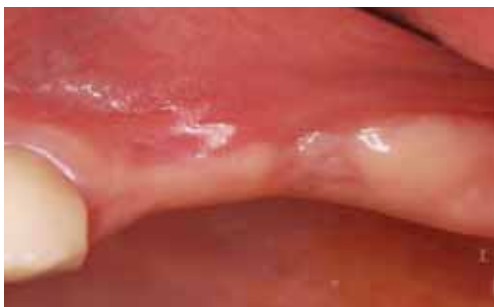

Fig.3 Buccal view of the edentulous narrow ridge 8 months after the extraction.

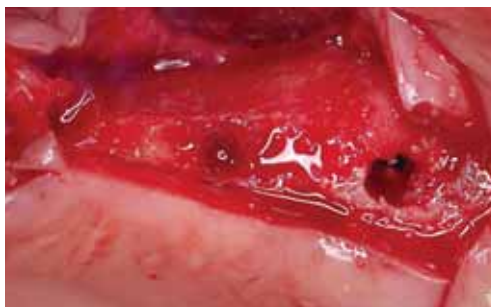


Fig.4 Extremely narrow ridge was found. The implant-beds were prepared after reduction of the alveolar ridge.

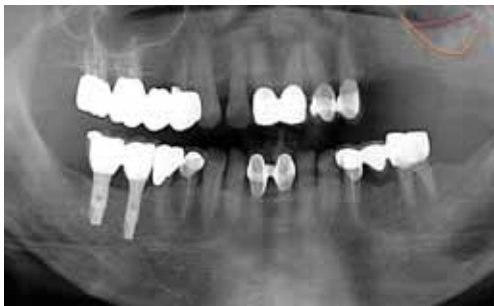

Fig.5 The sinus floor on site #26 was augmented by the crestal approach using SCA kit.

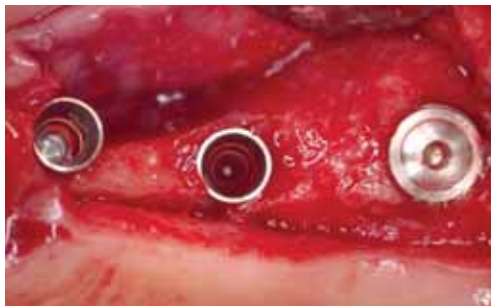

Fig.6 3.5X13mm and 4.5X10mm implants were placed on site #24 and #25 respectively. CMI fixation with 35Ncm of initial stability was achieved on #26 through inferior cortical fixation. A severe buccal dehiscence was present on site #24.

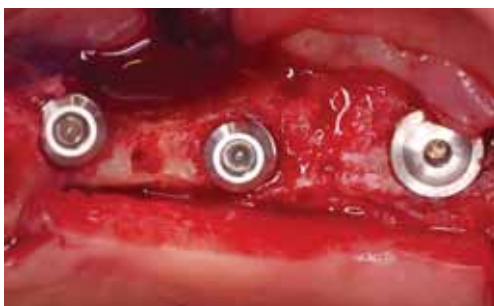

Fig.7 1mm CTI-spacers were placed on site #24 and #25.

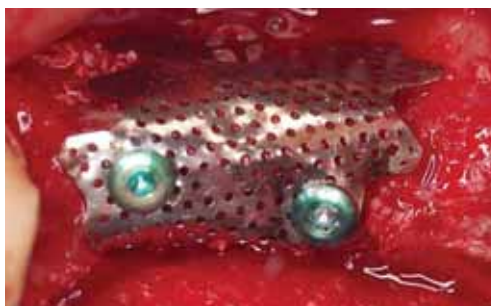

Fig.8 A combination of autogenous bone and allograft was applied to the defect. E2 type of CTI-mem was placed and 3 point fixation was made using two cover screws and one fixing screw over the graft.

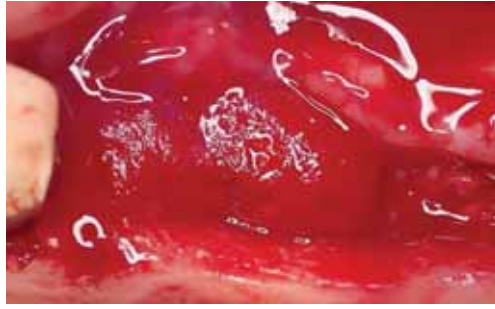


Fig.9 A sheet of Collatape was placed over the CTi-mem.

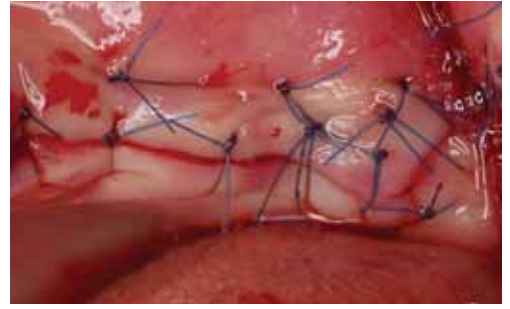


Fig.10 The flap was secured with horizontal mattress and interrupted technique.

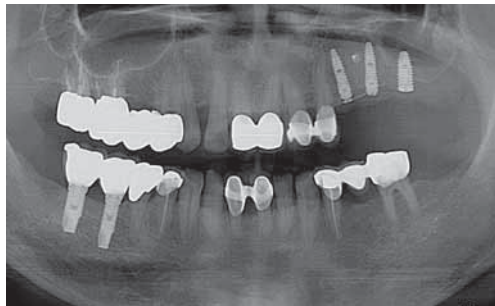


Fig.11 Postoperative radiographic view.

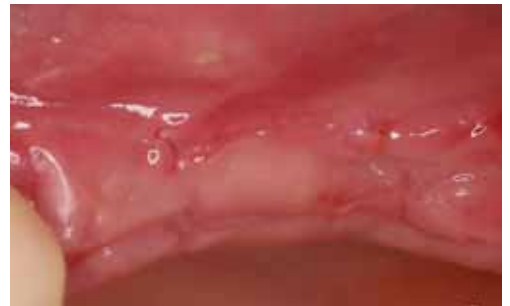

Fig.12 Incision line has healed 2 weeks after the surgery.

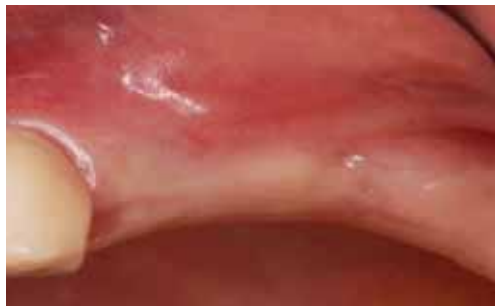

Fig.13 No CTi-mem exposure was observed at 16 weeks after the surgery. It would be due to the ideal fixation of the CTi-mem.



Fig.14 4 months later, CTi-mem was uncovered and it was verified that new bone formation has been made on the buccal and the lingual side.

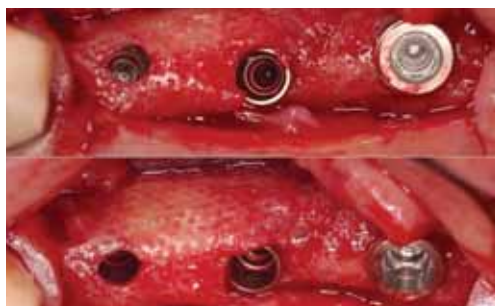

Fig.15 Complete bone regeneration was observed following the spacer removal.

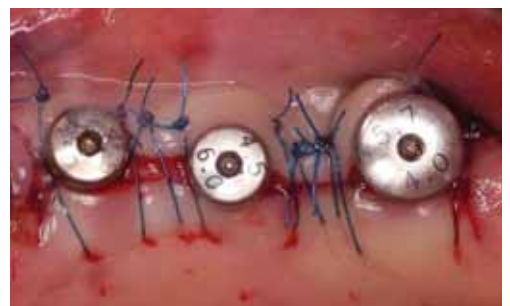

Fig.16 Healing abutments are in place. The flap was apically positioned to achieve keratinized gingiva.

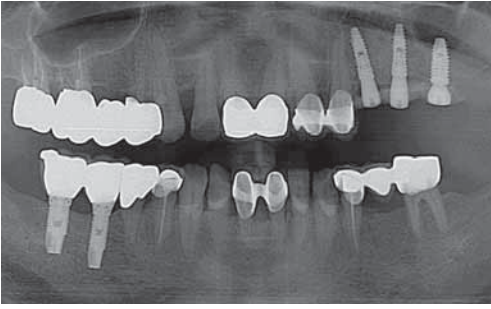

Fig.17 Panoramic radiograph taken after stage II surgery.

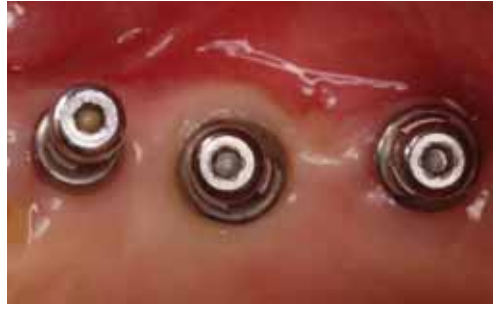

Fig.18 Impression was made a month after stage II surgery.

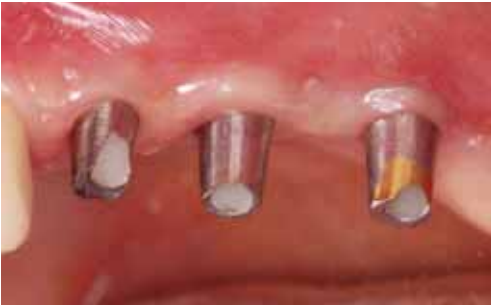

Fig.19 Cemented abutments in place.

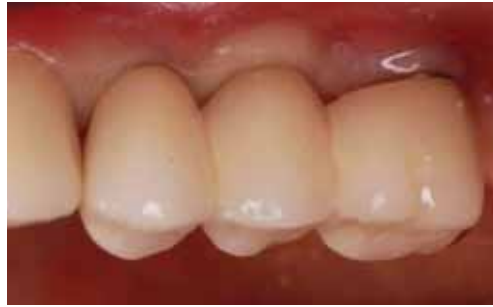

Fig.20 A 3 unit cement retained PFM FPD was delivered.

Simultaneous Implant Placement with C-reamer and Full Thickness Flap: 5 Year Follow-up



Dr. Jongyub Kim
DDS, MS, Ph.D



QR Code by Case

Patient Information

A 67-year-old female medically healthy and had limited masticatory ability due to missing posterior teeth in the maxilla.

Situation

Multiple septa are seen in both right and left sinuses. Due to the amount of bone graft required, crestal approach for the anterior part and lateral approach for the posterior part of the sinus are preferred. In the posterior region, the number of implants required should match the number of missing teeth.

Tool that used in surgery

IS-II active, Sinus All Kit

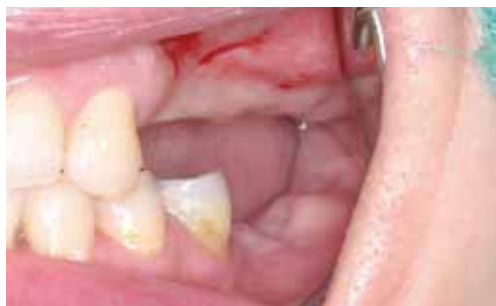

Fig.1 Lateral view of the maxillary left edentulous ridge before surgery. Vertical space is adequate but lateral deficiency on the buccal side of the edentulous ridge is shown.

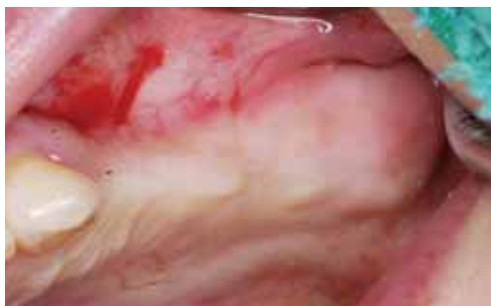

Fig.2 On the occlusal view, the lateral deficiency can be better visualized.

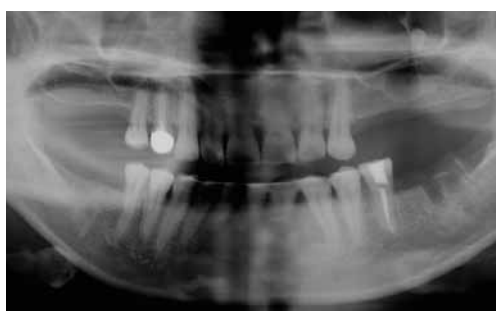

Fig.3 Panoramic x-ray : Multiple septa are seen in both right and left sinuses. Due to the amount of bone graft required, crestal approach for the anterior part and lateral approach for the posterior part of the sinus are preferred. In the posterior region, the number of implants required should match the number of missing teeth.

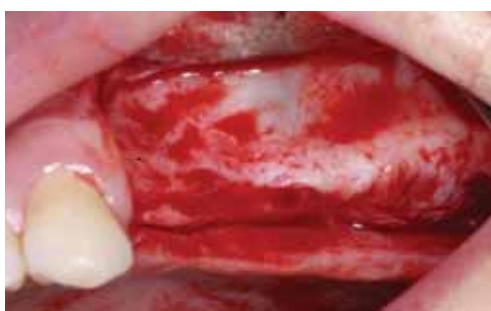

Fig.4 After the flap is reflected, it turned out the buccal bony deficiency did not require advanced buccal bone augmentation. The dark shadow shown on the buccal side implies the lateral wall of the sinus is very thin.

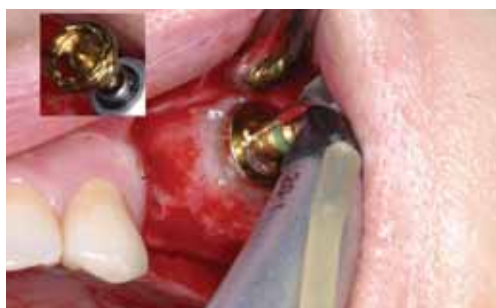

Fig.5 The C-reamer was used for lateral sinus graft. Drilling with 2000 rpm or faster is recommended for the C-reamer.

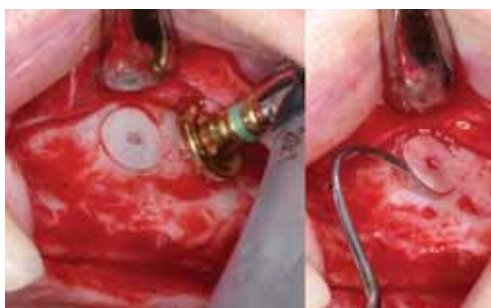

Fig.6 A dark shadow is seen under the outline of the C-reamer. During window preparation with the C-reamer, the reamer should not touch the sinus membrane directly. To avoid membrane perforation, osteotomy should not be performed in full depth and the bone core should be removed by green stick fracture. When the shadow becomes darker, it implies that the reamer is getting closer to the membrane (Left). The cut-out bone core is detached from the membrane by an explorer after fracture by tapping. (Right)

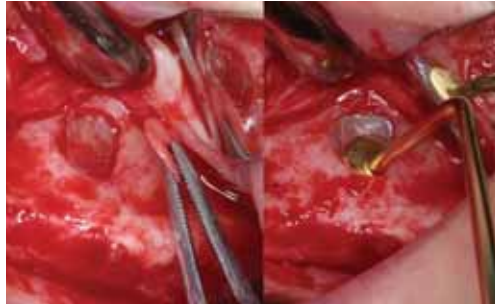

Fig.7 Note the bone core is very thin and the sinus membrane is now visible through the window. This membrane was detached by a mushroom elevator all around the window hole but it can tear the membrane if the sinus wall has an irregular or sharp surface, or septum. In that case, the other #01micro-elevator should be used.

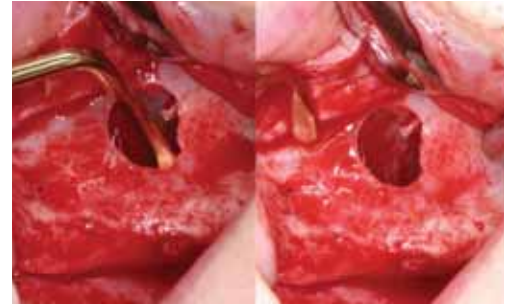


Fig.8 A #03 elevator is used to detach sinus membrane meticulously. A septum is seen after detaching the sinus membrane. Small size elevators are convenient in a case like this (Left). The membrane is completely detached and lifted away from the bone. (Right)

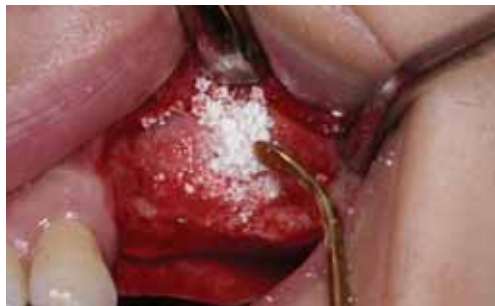

Fig.9 A genograft was used for the sinus. After bone grafting, 4 implants were placed simultaneously. Approximately 40 Ncm of insertion torque was obtained for each implant, even in the area of 2-3mm available bone. A bone core was repositioned without any fixation. Bone healing is better and faster with the repositioned bone core, which is one of the advantages of the C-reamer. The lateral and lingual bone of #25 was augmented by autogenous bone harvested from the tuberosity mixed with an allogenic bone.

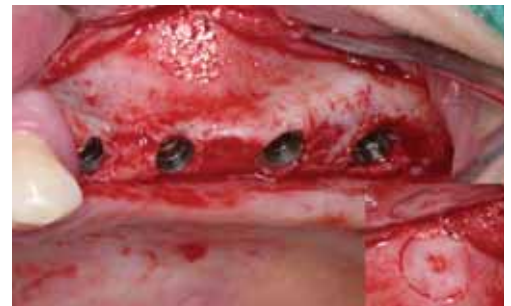

Fig.10 A genograft was used for the sinus. After bone grafting, 4 implants were placed simultaneously. Approximately 40 Ncm of insertion torque was obtained for each implant, even in the area of 2-3mm available bone. A bone core was repositioned without any fixation. Bone healing is better and faster with the repositioned bone core, which is one of the advantages of the C-reamer. The lateral and lingual bone of #25 was augmented by autogenous bone harvested from the tuberosity mixed with an allogenic bone.

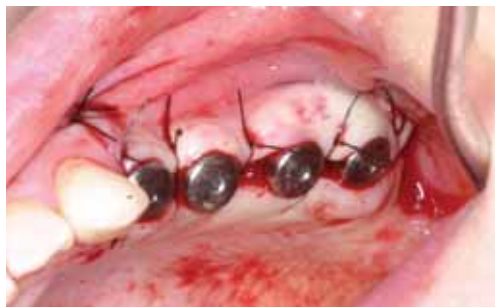

Fig.11 Healing abutments were connected and simple interrupted sutures were made in between healing abutments.

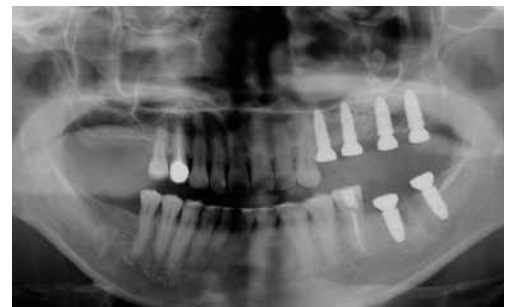


Fig.12 Panoramic x-ray after sinus graft and placement of implants.

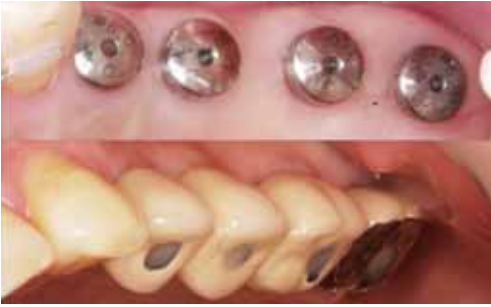

Fig.13 Soft tissue healing is completed after 2 months. Sufficient keratinized gingiva is created on the buccal aspect of the ridge. A 4-unit PFM FPD (SCRP) was delivered 4 months after implant placement.

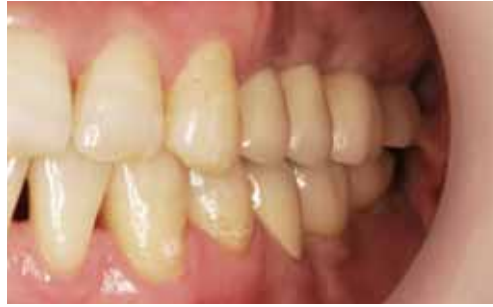

Fig.14 Buccal view of the final prostheses.

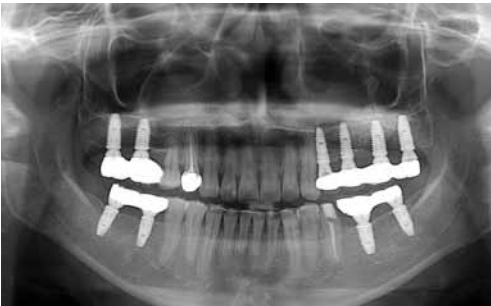


Fig.15 2 year follow-up on the final prosthesis.

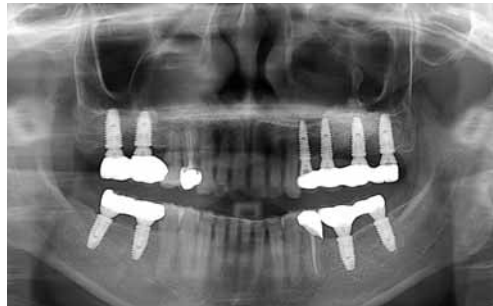

Fig.16 Panoramic x-ray. (5 year follow-up)

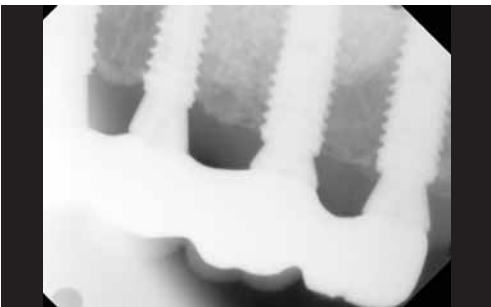


Fig.17 Periapical x-ray after 5 years. Minimal bone loss around implants is observed.

Sinus Membrane Elevation of a Complicated Sinus Septum Area with Vertical Bone Augmentation in Severe Defect Area



Dr. Nam Yoon Kim
DDS, MSD, Ph.D



QR Code by Case

Patient Information

A 58-year-old female patient.
No significant health history except for slight xerostomia.

Treatment Plan

1. Extraction of the tooth #27 due to severe caries.
2. After 6 weeks, #27 area guided bone regeneration with CTi-memb + synthetic bone (DM bone, Metabiomed) with sinus floor augmentation.
3. Implant placement of #26 after Class III Sinus augmentation by the crestal approach using SCA kit (Neobiotech) and #27 at 6 months later.
4. Delivery of final prosthesis.

Tool that used in surgery

IS-II active, EB Fixture, Neo Surgical Kit, SCA Kit, CTi-membrane, EZ-GBR kit

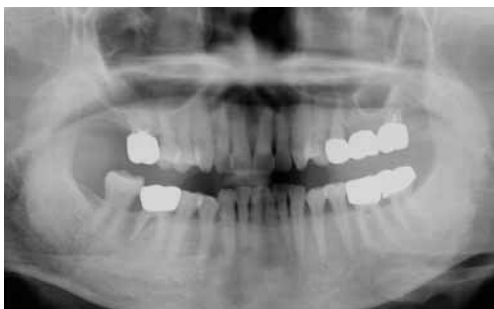

Fig.1 Panoramic x-ray at the first visit. A complicated sinus septum was present between #25 and #26. the height of the remaining bone was about 2-3mm at #26 site. It appears that only thin cortical bone covers the root of #27 which invades into the sinus cavity.

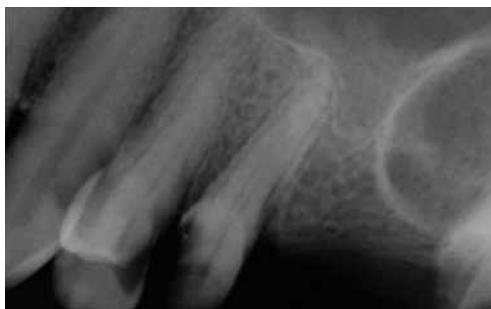

Fig.2 Periapical x-ray after removal of the previous prosthesis. #27 was extracted due to severe caries. Near the root apex of #25, pneumatization of the sinus inferior wall was observed.

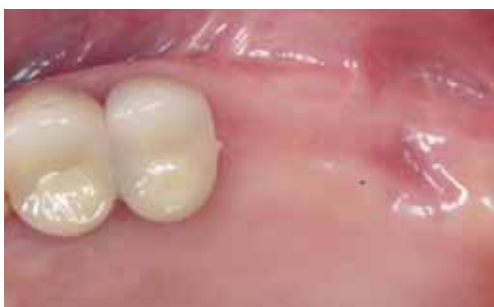

Fig.3 #26 & #27 are missing. #27 was extracted 6 weeks previously.

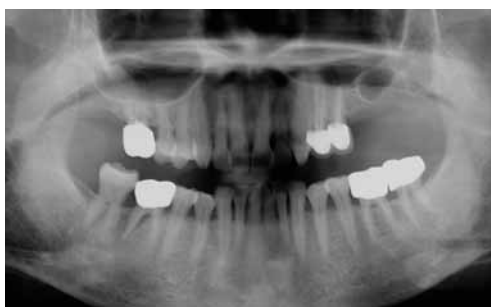

Fig.4 6 weeks after the extraction of #27. There seemed to be some remaining bone at #27 site. #26 site was planned to obtain a Class II/III fixation by passing through the mesial slope of the sinus and septum with the S-reamer.

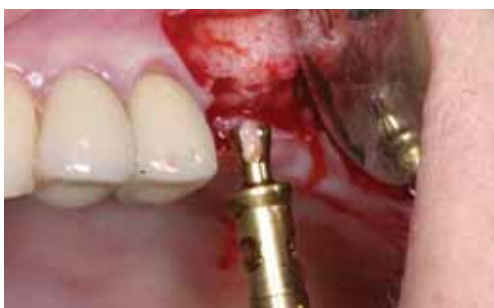

Fig.5 After the initial osteotomy up to the depth just short of the final depth with initial straight drill, the last part of the osteotomy to penetrate the sinus septum was performed with the S-reamer of 3.2mm diameter with a 5mm stopper. Drilling at 1000-2000 rpm with copious irrigation is recommended for this procedure.

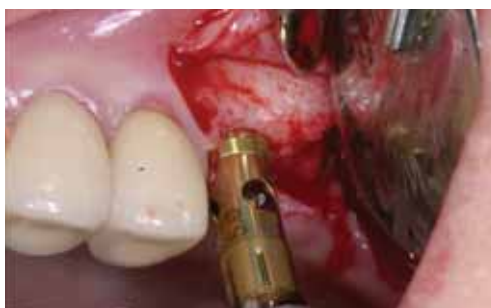

Fig.6 The S-reamer in the SCA kit was used to drill into the sinus cavity to achieve Class III CM fixation. Based on the radiographic analysis, residual bone height was expected to be 4-5mm.

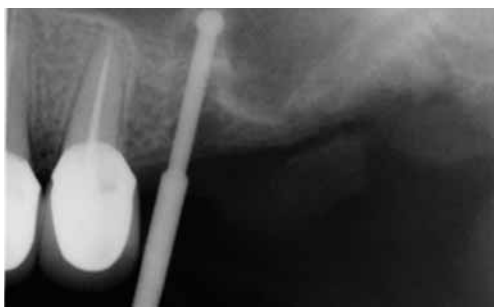

Fig.7 On periapical x-ray, the drilling path is shown by the depth gauge inserted into the osteotomy site. When drilling with the S-reamer, one does not perforate or tear the sinus membrane as long as the drill does not go beyond the peak of the septum. Good initial fixation can be obtained by engagement of the implant into the cortical bone of the septum.

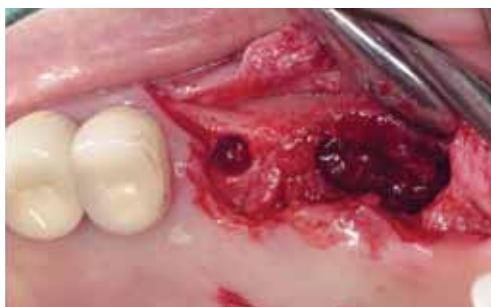

Fig.8 The cortical wall of the sinus septum of #26 area was eventually opened at 7mm drilling. In the #27 and #28 area a large defect was observed. The membrane fused to the soft tissue of the gingiva was cut, separated and detached from the sinus bony wall.

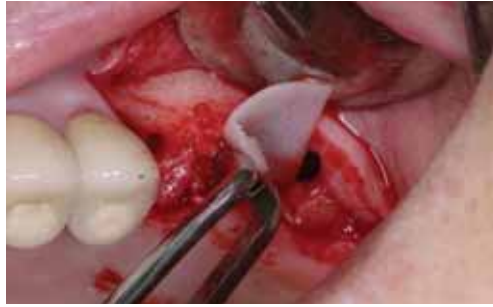

Fig.9 A collagen membrane (Lyoplant) was placed to cover the soft tissue layer, to separate the membrane from grafted bone and to prevent the downgrowth of soft tissue.

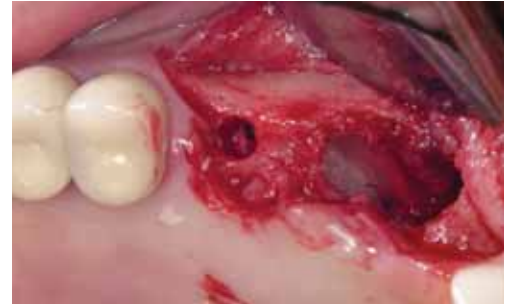

Fig.10 The collagen membrane cover underneath the soft layer is seen. The sinus membrane at the mesial part of the septum was detached with the S-reamer, and the membrane at the distal side of the septum was detached by the #03 elevator.

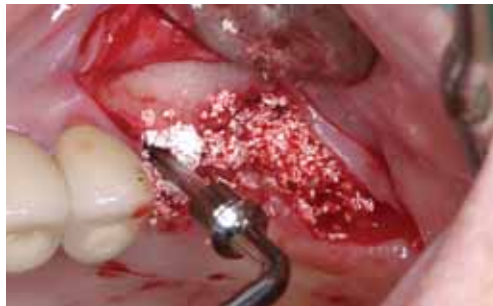

Fig.11 Alloplastic bone material (DM bone, Metabiomed) was inserted into the sinus cavity crestally.

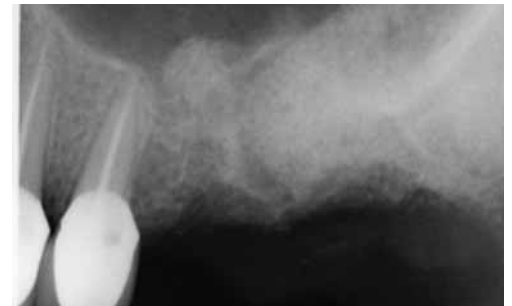

Fig.12 The mesial side of the membrane was elevated by the S-reamer and crestal bone graft, and the rest of the sinus was elevated by the micro-elevators in the SLA kit and grafted through the large crestal opening.

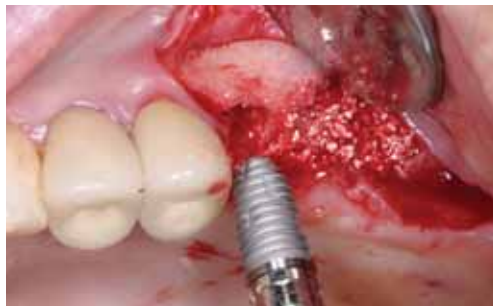

Fig.13 A 5.0x10mm CMI EB fixture was inserted at #16 site. ITV was 40 Ncm which was probably obtained from thick inferior cortical layer engagement.

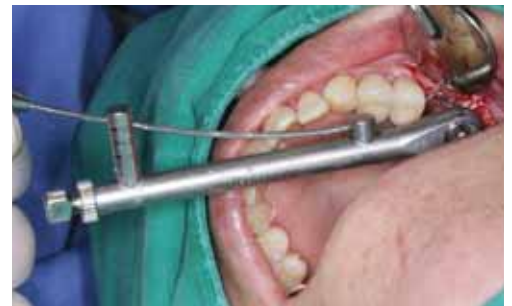

Fig.14

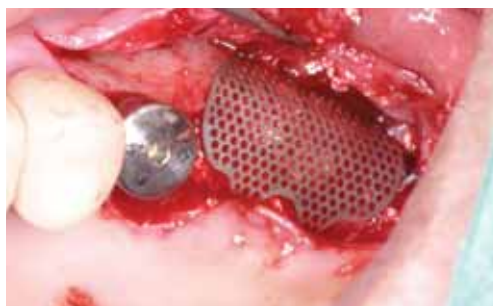

Fig.15 A titanium mesh (CTi-mem, E3) was adapted and placed on the grafted site. The Ti mesh was fixed by suture material. It is critical to cover CTi-mem with a collagen membrane to reduce exposure rate.

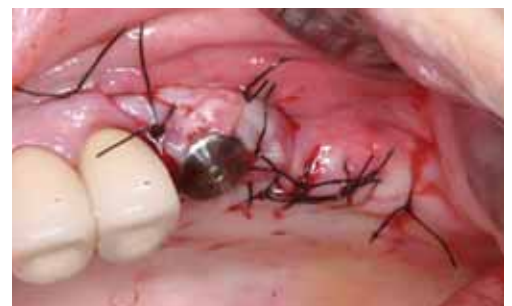

Fig.16 The #16 implant was non-submerged and a healing abutment was connected after implant placement. Mattress suture is usually recommended for adequate eversion of the flap. In this case, simple interrupted and modified mattress sutures were done due to the thick gingiva.

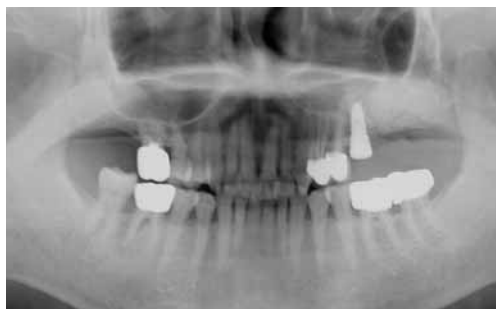

Fig.17 Panoramic x-ray after surgery. The distinct outline of the grafted bone is visible. The #26 implant was loaded in 3 months by a provisional crown.

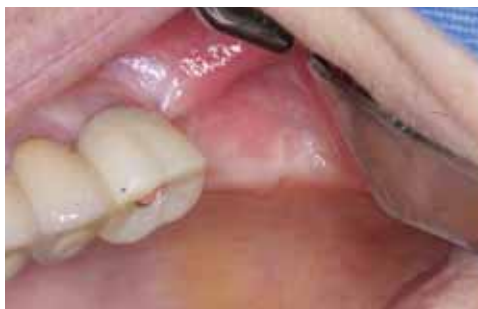

Fig.18 6 months after surgery. Soft tissue is healed without any Ti mesh exposure.

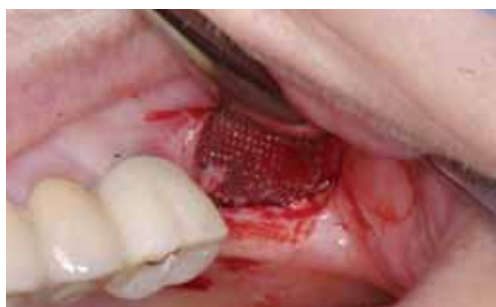

Fig.19 At the time of the Ti mesh removal, the mesh was well adopted and there was no sign of infection. The volume of the grafted bone was maintained.

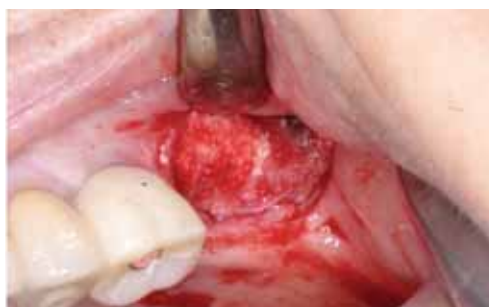

Fig.20 The removal of the CTi-mem is easier than other Titanium meshes. Underneath the Ti mesh, a solid bone mass was observed.

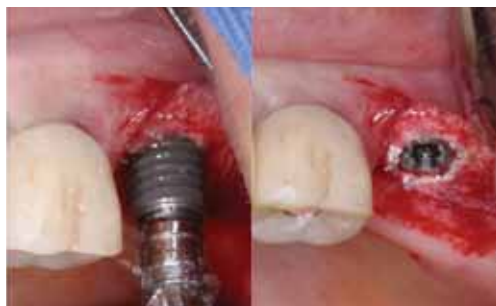

Fig.21 A 5.0x10mm CMI IS-II active fixture was placed 1mm subcrestally in the grafted bone only. The bone density and ITV were D333 and 20 Ncm.

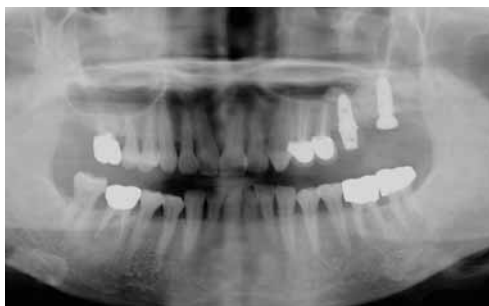

Fig.22 Panoramic x-ray after the placement of implant #27. The delivery of the final prosthesis is scheduled four months after implant placement.

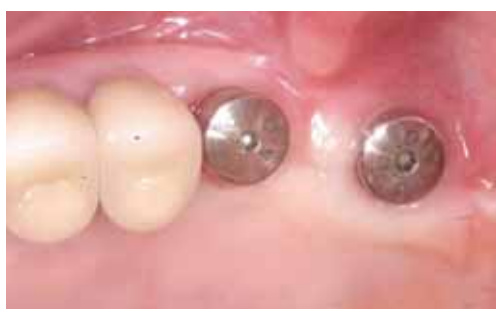

Fig.23 Occlusal view (4 months post-op) : Adequate amount of attached gingiva is present around #26, but not on the buccal aspect of #27.

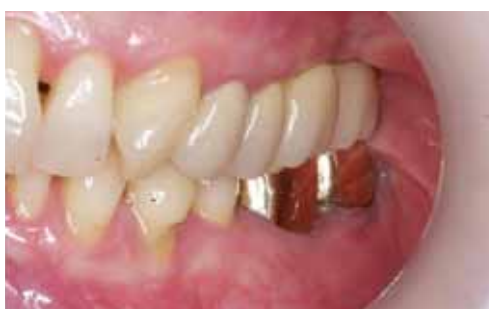

Fig.24 Upon light biting, a piece of shimstock should loosely pass through the two opposing occlusal surfaces. Heavy biting, however, should hold the shimstock between upper and lower teeth.

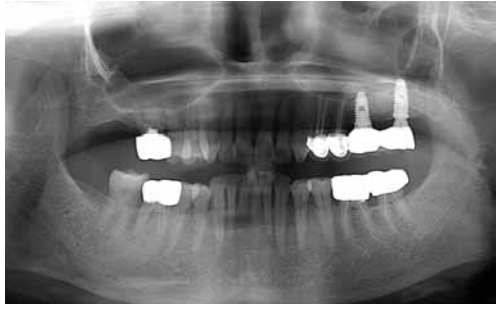

Fig.25 Panoramic x-ray after the delivery of final prosthesis.

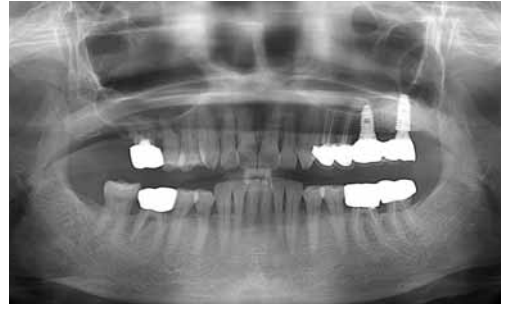

Fig.26 Panoramic x-ray (5 year follow-up) : No marginal bone loss is observed around implants, specially in the #27 grafted area.

Management of Perforated and Maxillary Sinusitis for Implant Treatment : A Case Report



Dr. Jongyub Kim
DDS, MS, Ph.D



QR Code by Case

Patient Information

A 43-year-old female patient was referred from another dentist for management of sinus infection for sinus graft for partial edentulous area on left maxilla. Patient was healthy, in terms of medical history except para-nasal symptoms.

Treatment Plan

1. Lateral window opening with a reamer in SLA kit.
2. Careful elevation of sinus membrane including tearing area.
3. Repair of teared membrane with collagen membrane.
4. Bone grafting through lateral window and crestal opening.
5. Implant placement on tooth #26 and 27 area after 6 months.
6. Delivery of final prosthesis.
7. Periodic F/U.

Tool that used in surgery

IS-III active, Neo Surgical Kit, SLA Kit

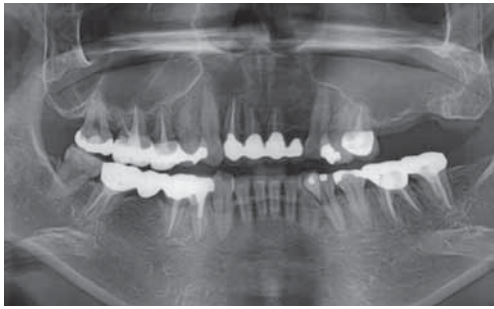

Fig.1 From the initial panoramic view, haziness on left maxillary sinus and bony opening on crestal area can be seen.

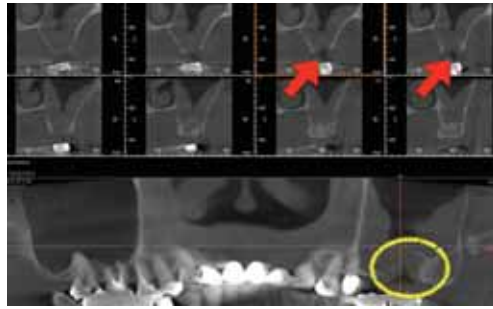


Fig.2 From the CT scan, also bony opening on #27 area and mucosal thickening on left maxillary sinus can be observed. Patient was referred to ENT specialist for examination and medication. Patient was come back after 3 weeks of antibiotics medication.

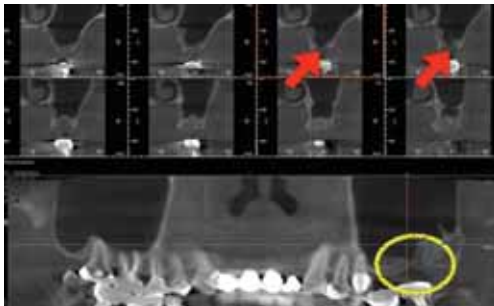


Fig.3 From the CT scan, bony opening was still there, but mucosal thickening was subsided.

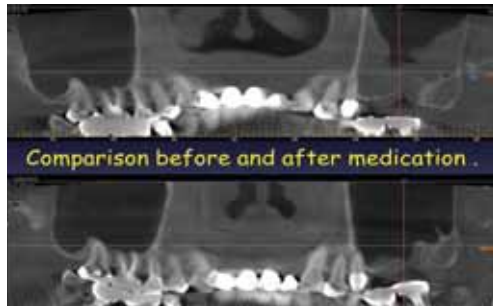


Fig.4 Comparison before and after medication.

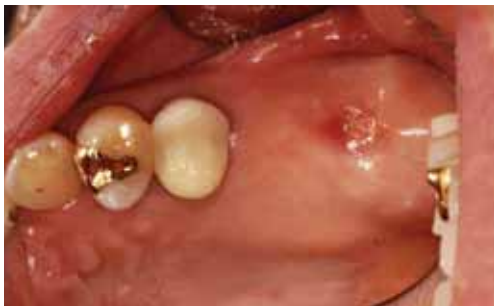

Fig.5 Occlusal photography before sinus graft.

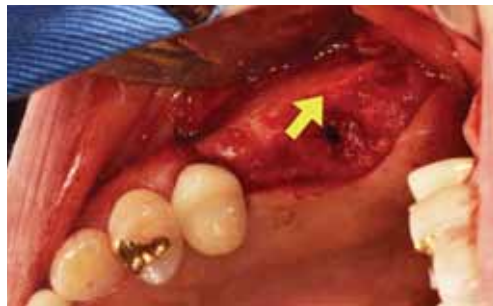

Fig.6 Clinical picture after incision and periosteal dissection. Existing bony opening can be seen.

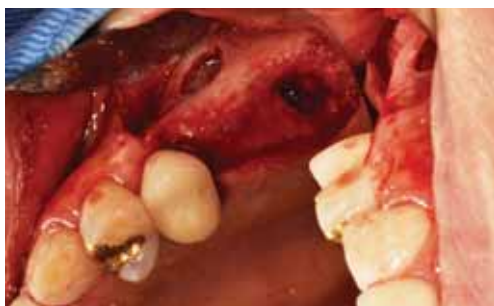

Fig.7 Small lateral window was made by reamer in SLA kit and careful elevation of maxillary sinus membrane was performed.

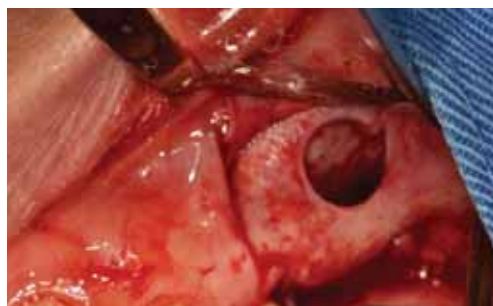

Fig.8 Small lateral window was made by reamer in SLA kit and careful elevation of maxillary sinus membrane was performed.

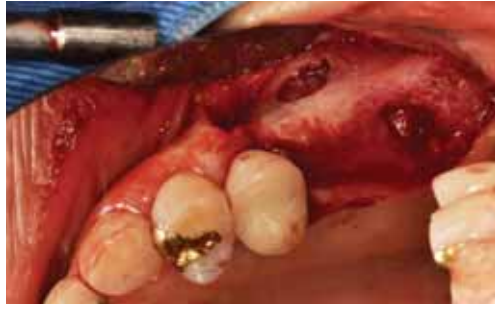

Fig.9 Collar tape was used for cover perforated area through crestal opening.

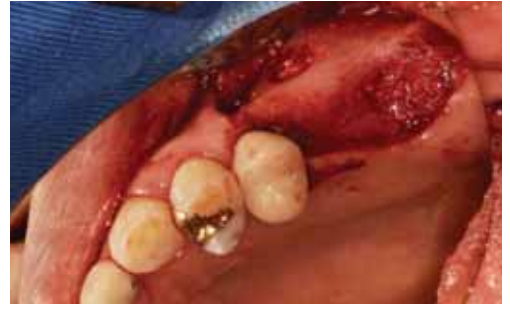

Fig.10 Bone graft was done through lateral window and crestal opening.

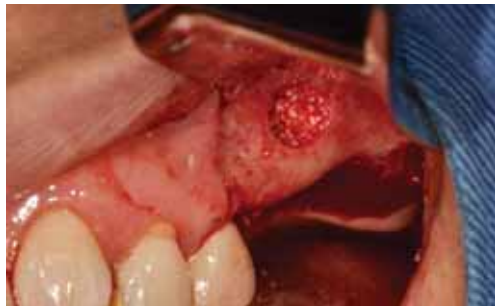

Fig.11 Bone graft was done through lateral window and crestal opening.

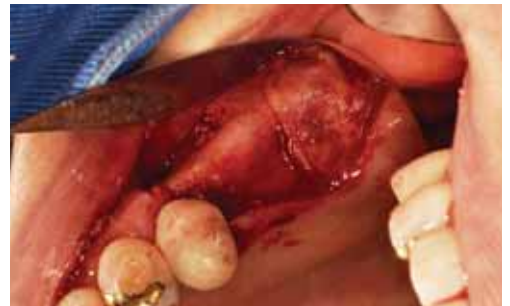

Fig.12 PRF membrane was used cover crestal bony opening area.

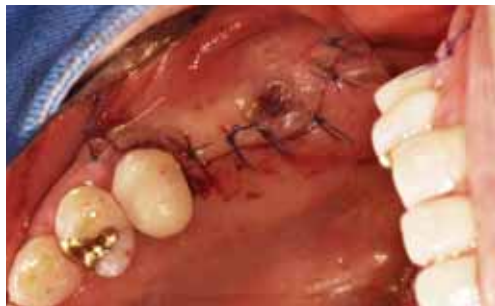

Fig.13 Clinical picture after wound closure.

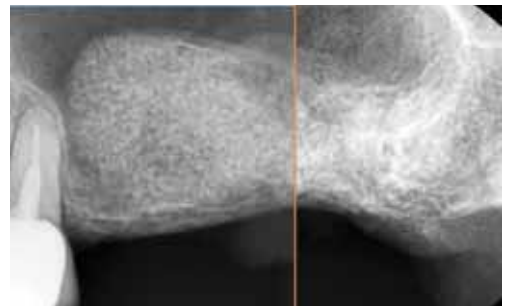


Fig.14 Periapical radiographs after sinus graft followed by repair of perforated membrane.

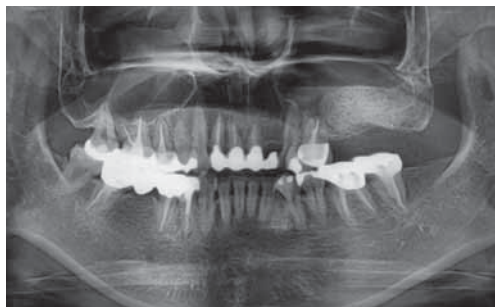

Fig.15 Panoramic view right after sinus graft.

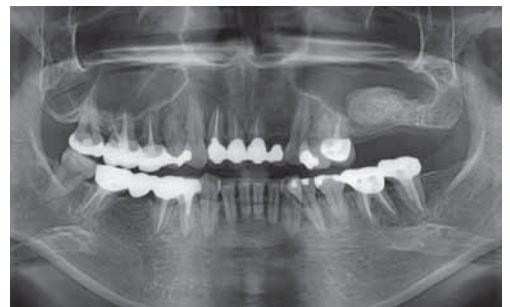

Fig.16 Panoramic view 5 months after sinus graft.

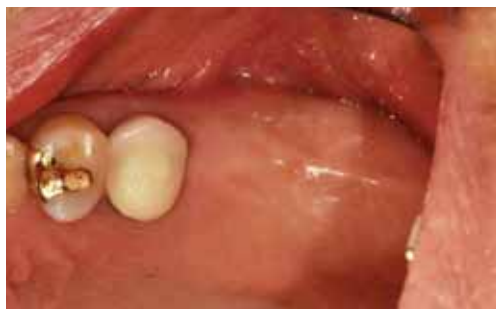

Fig.17 Clinical picture before implant placement, 5months after sinus graft.

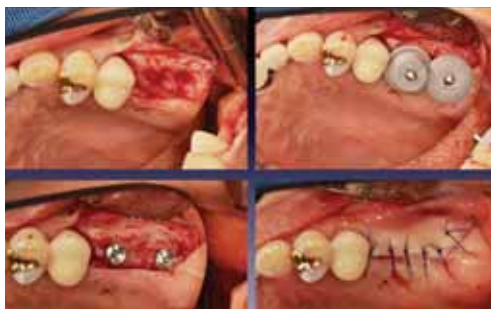

Fig.18 Implant placement. (IS-III 4.5X10, 4.5X8.5 were used)

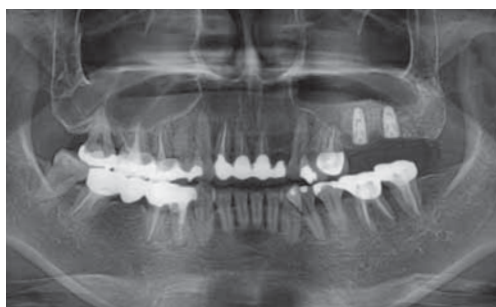

Fig.19 Panoramic view after implant placement.

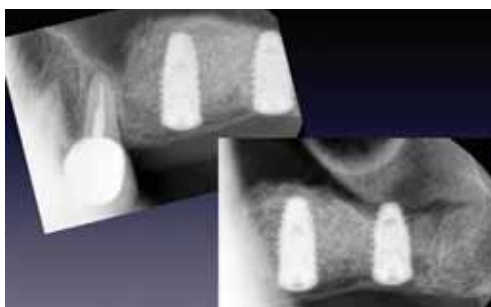


Fig.20 Periapical radiographs after implant placement.

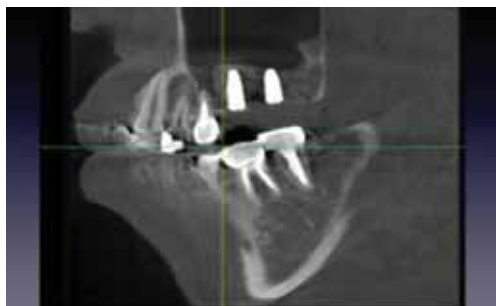


Fig.21 CT scan after implant placement.

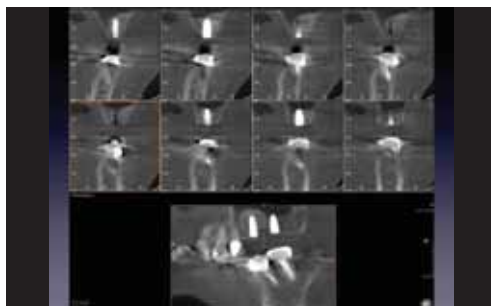


Fig.22 CT scan after implant placement.

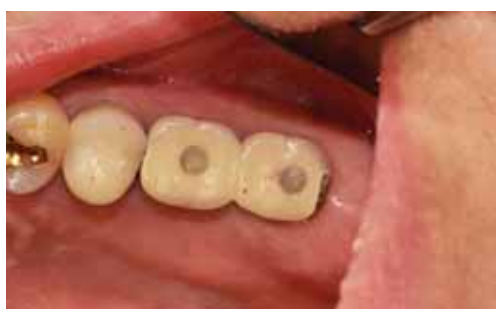

Fig.23 Clinical picture after delivery of implant restoration.

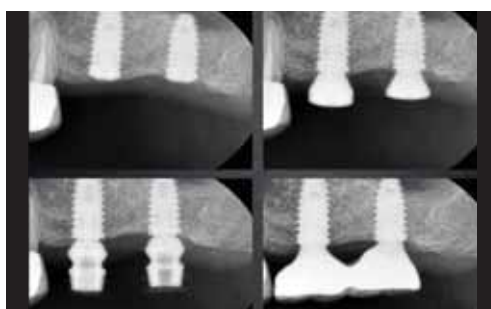
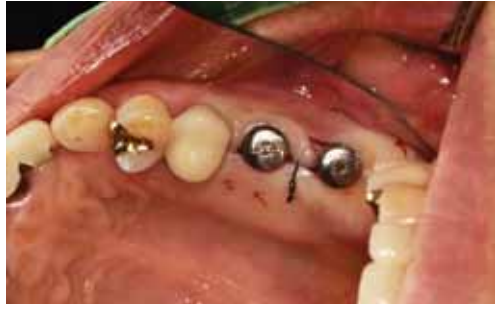
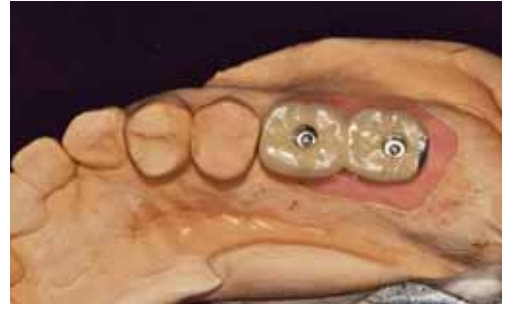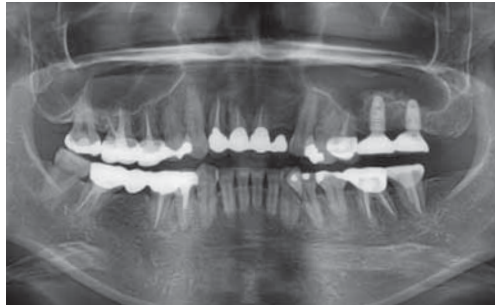
Fig.24 Series of periapical views, implant placement, 2nd surgery, impression, final restoration.



| Fig.25 Clinical picture after 2nd surgery. (uncover)



| Fig.26 Final restorations on the cast.



| Fig.27 Panoramic view after implant treatment.

Sinus lift augmentation without the use of a solid biomaterial : PRF only



Dr. Michal Jozwiak
DDS



QR Code by Case

Patient Information

Patient : 61 years old male.

Medical status : healthy.

Dental history : teeth 25 and 26 extracted due to endodontic failure.

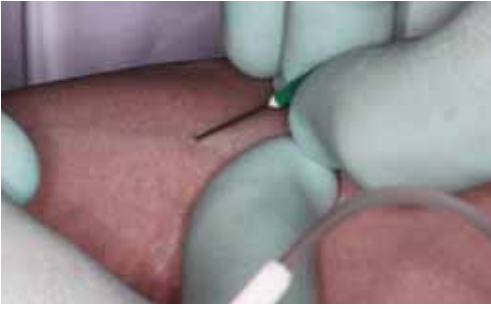
Chief complaint : esthetic and functional problems.

Treatment Plan

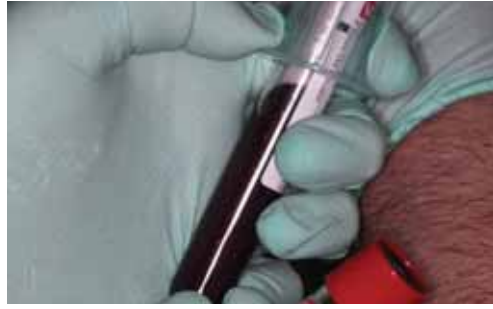1. Note that the alveolar part of the maxillary sinus is a five- wall defect which is similar to a dental socket. This type of defect heals spontaneously.
2. Implant planning : the view of the alveolar part of the maxillary sinus.

Tool that used in surgery

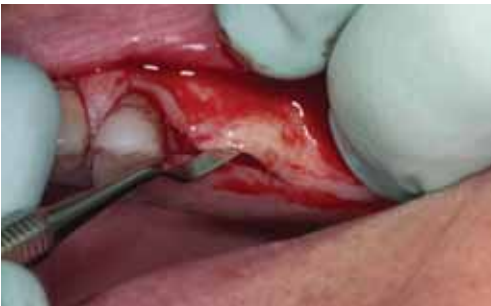IS-II active, Neo Surgical Kit, SLA Kit



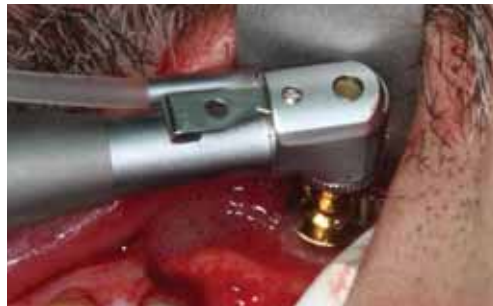| Fig.1 PRF Processing.



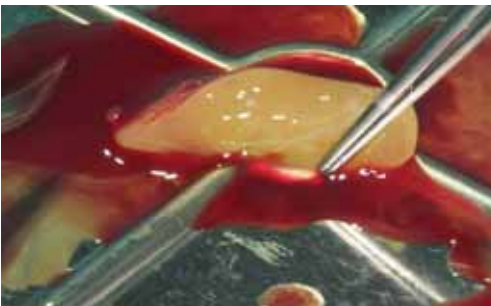
| Fig.2



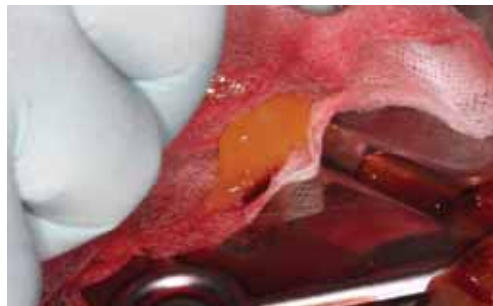
| Fig.3



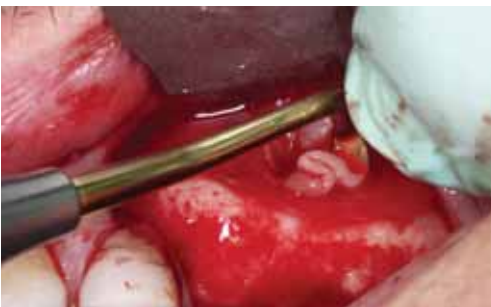| Fig.4



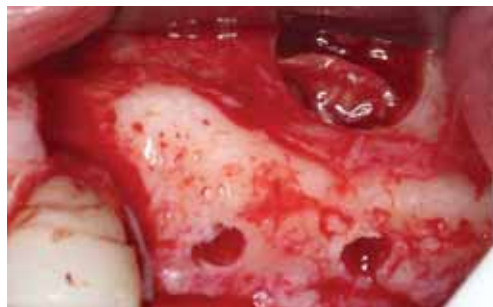| Fig.5



| Fig.6



| Fig.7



| Fig.8 PRF is only material which support Schneiderian membrane tent.

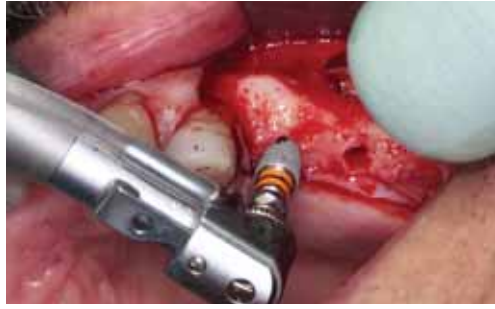

Fig.9

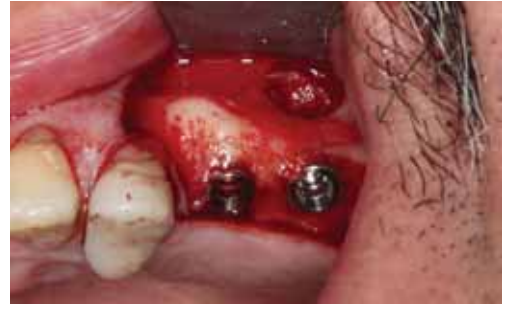

Fig.10 Implant insertion.

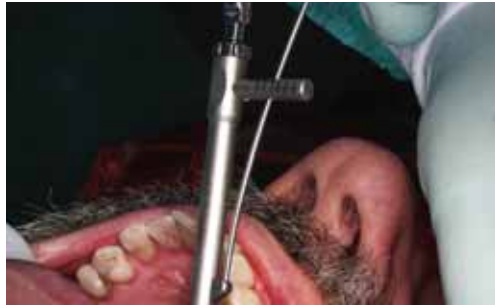

Fig.11 30-40Ncm initial stability was reached.

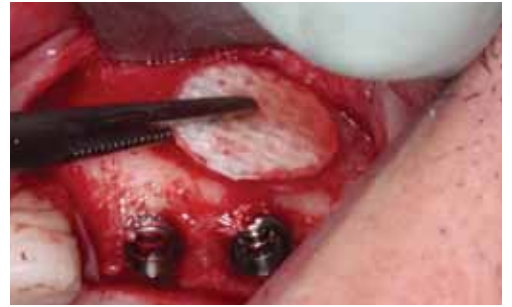

Fig.12 Sinus window is covered by a collagen membrane.

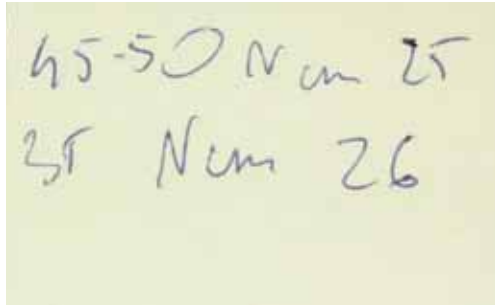


Fig.13

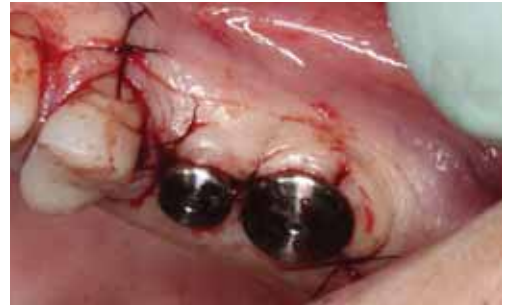

Fig.14

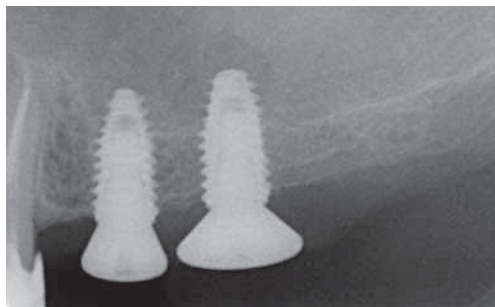


Fig.15 X-Ray after implant placement: note a small 6 mm diameter access window and lack of biomaterial.

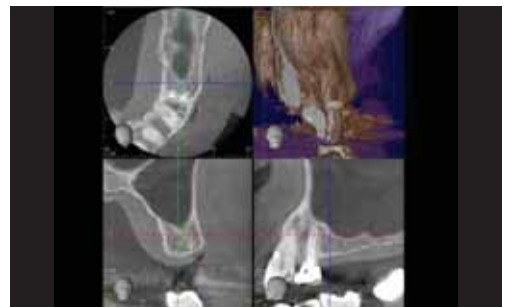

Fig.16 CBCT before the surgery.

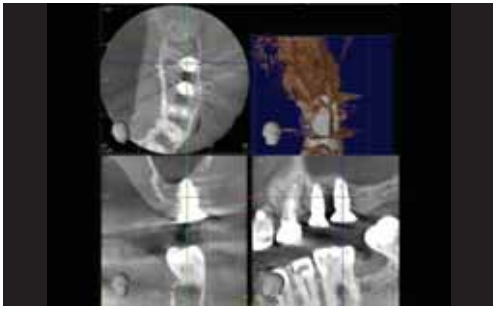


Fig.17 CBCT 3 months after the surgery.

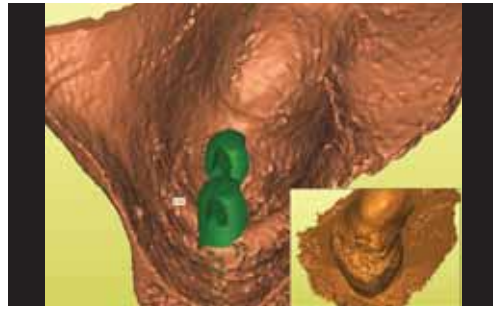


Fig.18 Comparison of Simplant view before and 3 months after treatment.

Early loading in the posterior mandible

Dr. Young-Ku Heo
DDS, MSD, Ph.D



QR Code by Case

Patient information

63 years old / Male.

Treatment Plan

1. Implant placement on tooth #44, 46, 47 area with EB implants. (Neobiotech)
2. One-stage approach.
3. Bone grafting if needed.
4. Early loading if insertion torque is over 30N/cm & ISQ value is above 70 without stability dip.
5. Delivery of 4-unit SCRIP prosthesis.

Tool that used in surgery

CMI EB , EB/IT Kit, Ridge Wider Kit

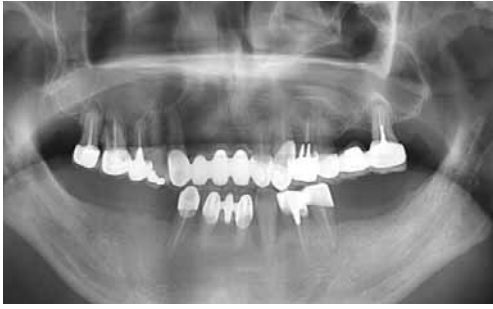

Fig.1 Pre-op panorama.

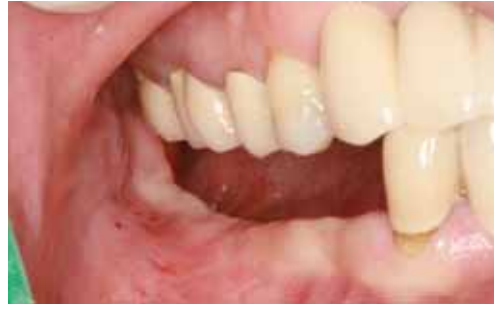

Fig.2 Intra-oral photograph.

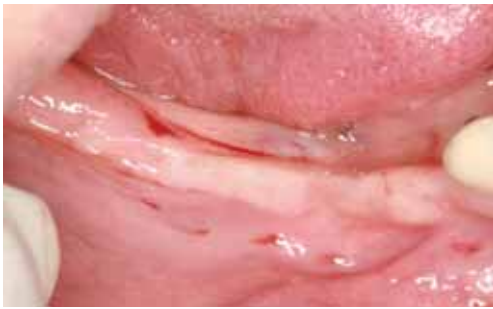

Fig.3 Incision.

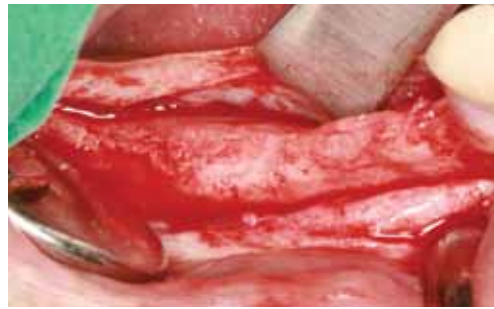

Fig.4 Flap reflection.

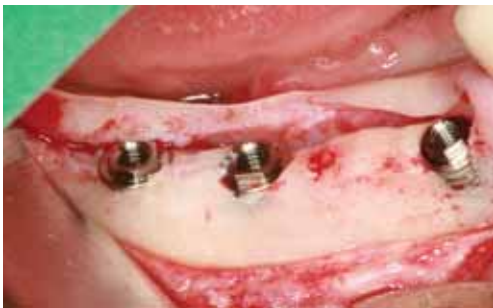

Fig.5 3 external implants (CMI EB) were placed with 40Ncm of insertion torques in that area.

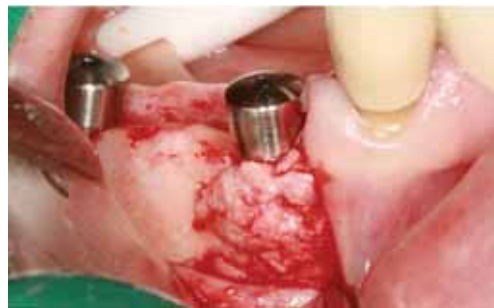

Fig.6 Healing abutments were connected to the fixtures. Autogenous bone chips harvested from the adjacent ridge area was grafted in the defect.

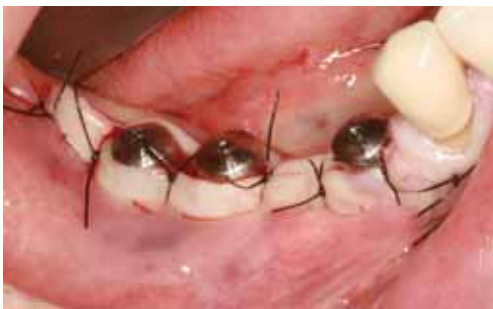

Fig.7 Non-submerged approach was done and the wound margins were closed with sutures.

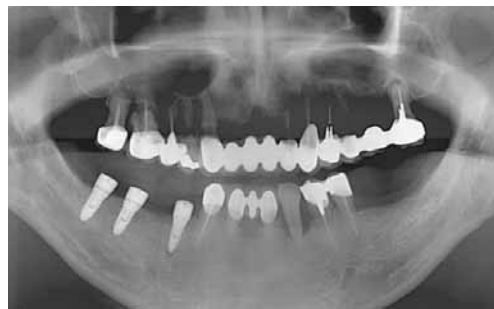

Fig.8 Postoperative panoramic radiograph showing 3 implants placed in the mandibular right posterior area.




Fig.9 An impression was made with pickup impression coping 6 weeks after the surgery.

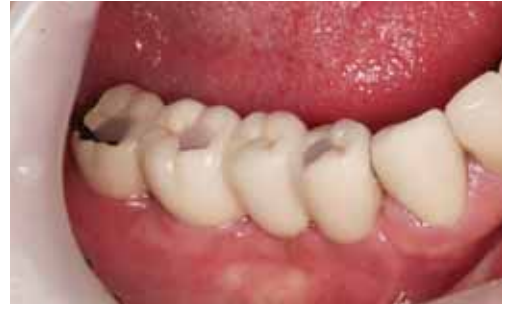

Fig.10 A definitive 4 unit SCRCP prosthesis was delivered 8 weeks after implants placement.

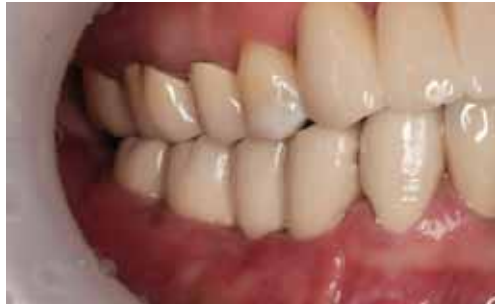

Fig.11 Lateral view of right mandible after treatment.

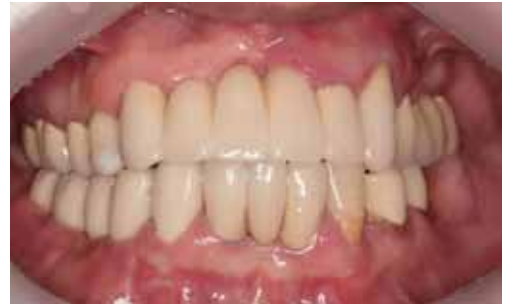

Fig.12

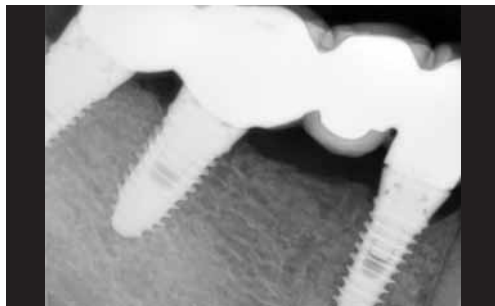

Fig.13 Radiograph taken on the day of final restoration.

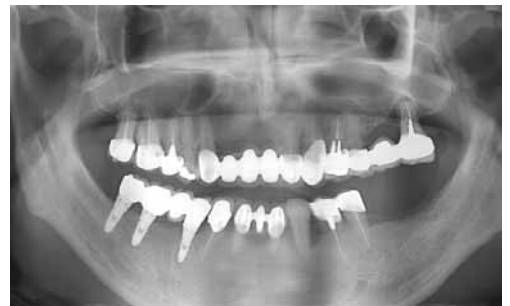

Fig.14 Panoramic view after delivery of the prosthesis.

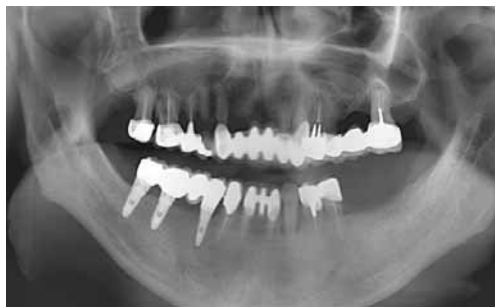

Fig.15 A month of follow-up after delivery of final prosthesis.

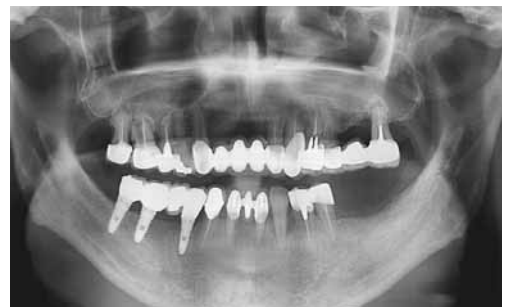

Fig.16 8 months of follow-up panoramic view.

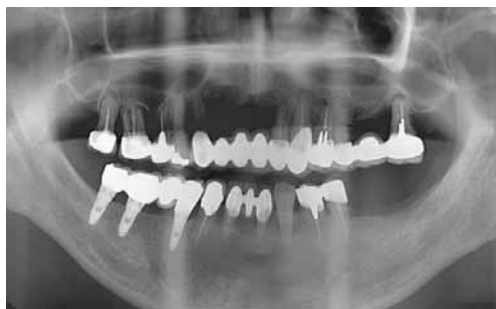

Fig.17 One and a half years of follow-up panoramic view.

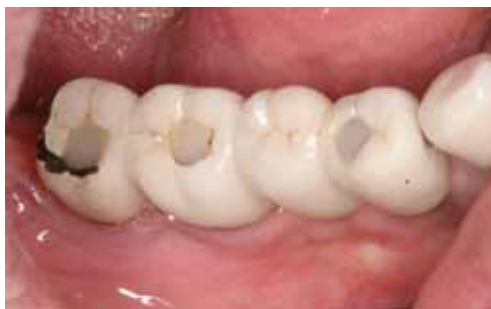

Fig.18 4 year follow-up on the final prosthesis.

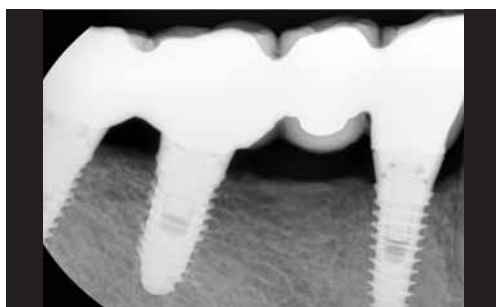


Fig.19 4 year follow-up on the final prosthesis.

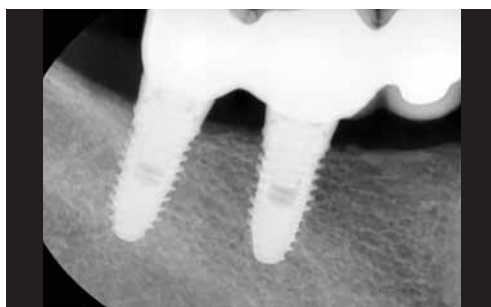

Fig.20 4 year follow-up on the final prosthesis.

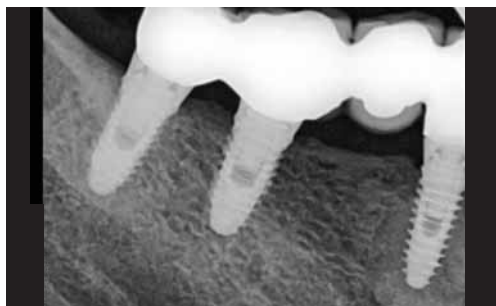


Fig.21 8 year follow-up on the final prosthesis.

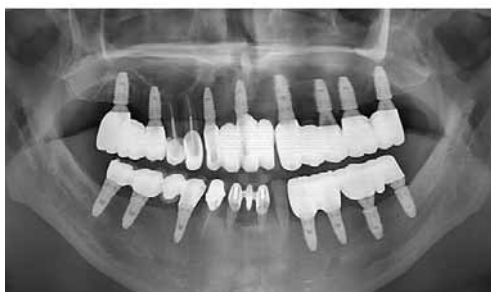

Fig.22 8 years postoperative panoramic radiograph showing well maintained implants without any noticeable bone loss.

Short Single Implant (IS-II active 4.5 X 8.5mm) Placed and Immediately Loaded in the Replacement at #44

Dr. Michele Perelli
DDS



QR Code by Case

Patient Information

65 years old, male, non smoker, good health.

Tool that used in surgery

IS-II active, Neo Surgical Kit, PickCap Impression Coping

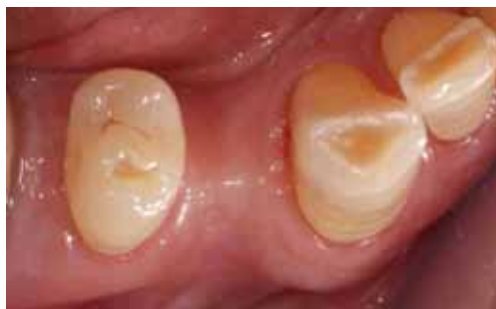

Fig.1 Pre-Operative examination

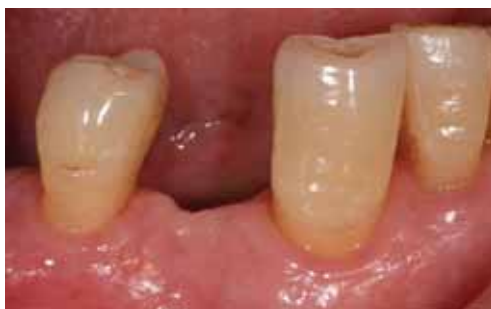

Fig.2 The edentulous site presented enough keratinized tissue, with no need of grafts

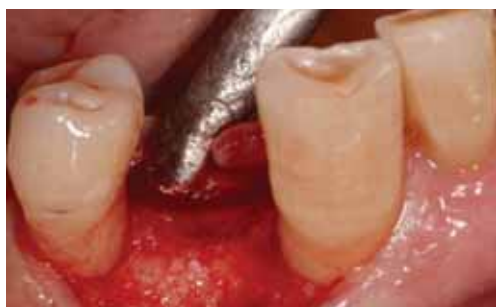

Fig.3 After the osteotomy has been prepared, the implant is placed with the smooth collar at the bone level. An adequate torque has been reached (50 Ncm) and it has been decided to immediately load the implant.

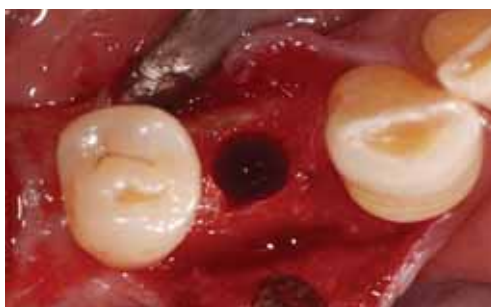

Fig.4

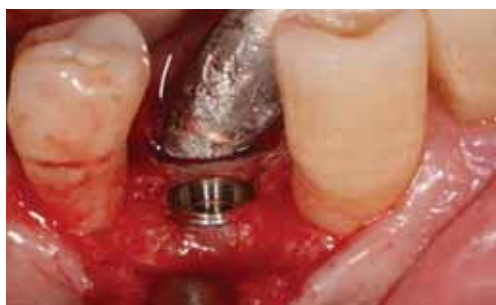

Fig.5

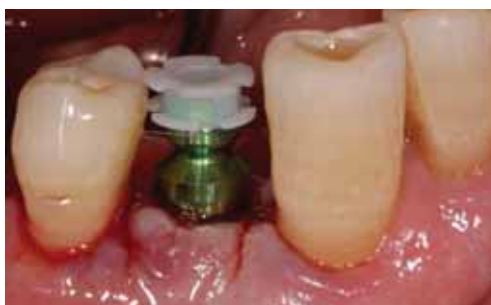

Fig.6 A short transfer and a snap-on device were immediately positioned and flaps sutured around it. After the impressions, an healing abutment was connected.

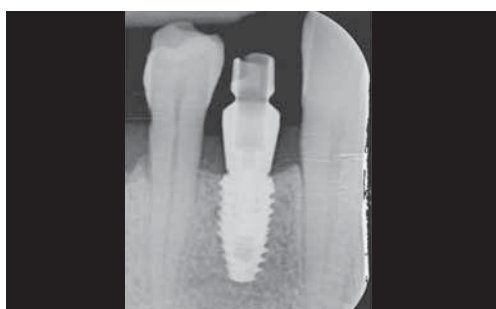

Fig.7

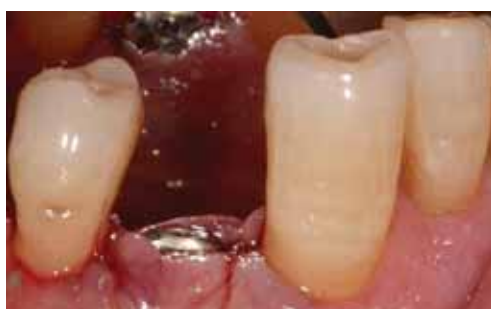

Fig.8



Fig.9 A provisional screw-retained resin crown was delivered the day after and sutures were removed after 10 days. Great attention was dedicated to occlusal control avoiding any contact.

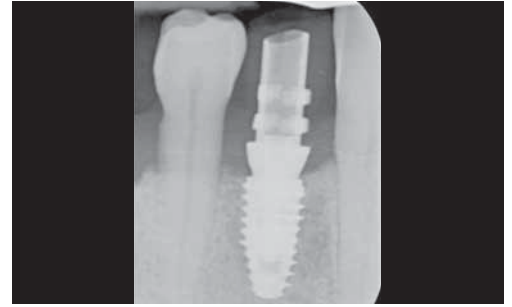

Fig.10

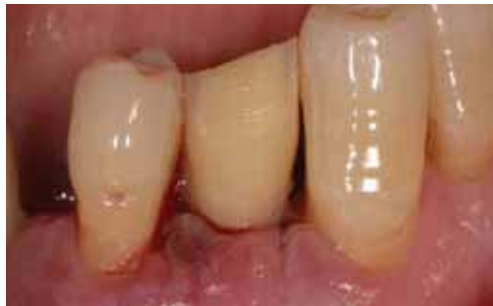

Fig.11

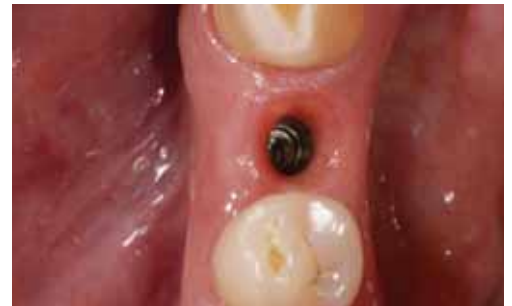

Fig.12 After 6 months soft peri-implant tissue were in good health, without inflammation and they presented good stability and thickness.

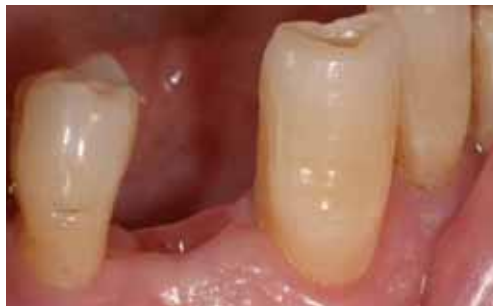

Fig.13

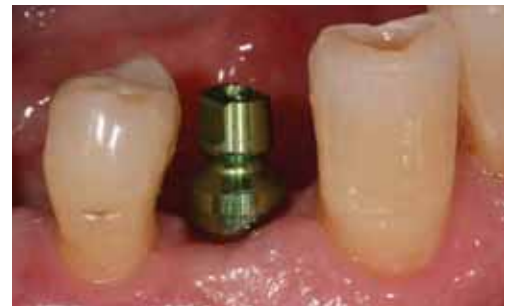

Fig.14 A new impression was taken always with the snap on easy repositioning cap.

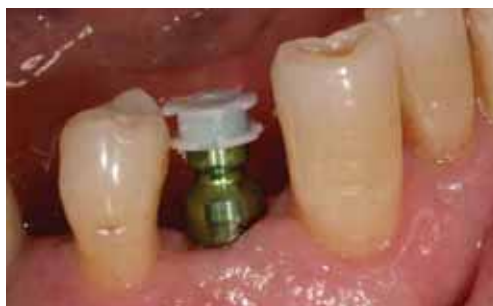

Fig.15

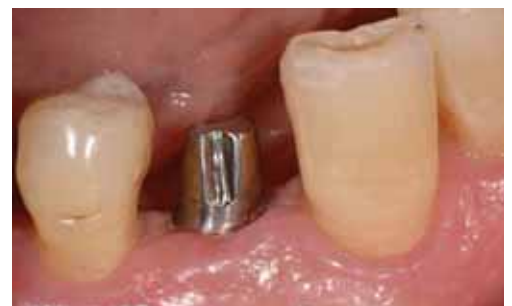
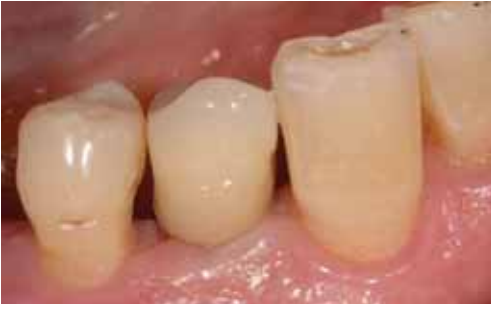
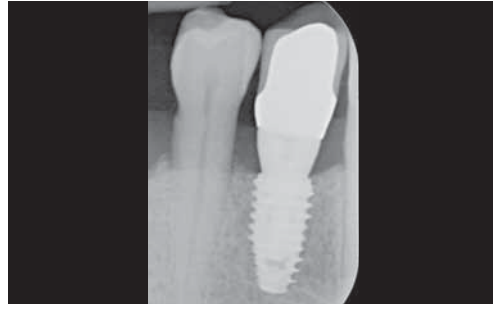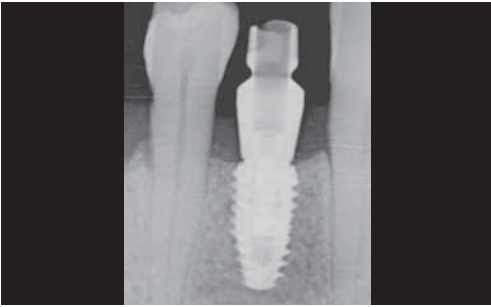Fig.16 A definitive PFM crown was cemented on a definitive abutment.



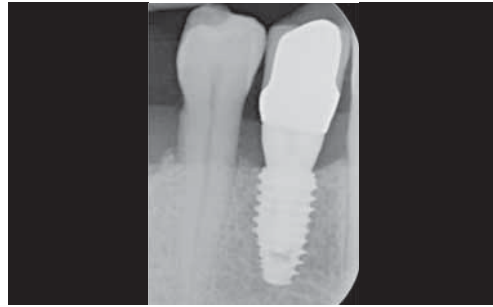| Fig.17



| Fig.18



| Fig.19 Comparison of baseline and 12 months follow-up radiographs: no bone remodeling occurred and the implant demonstrated to be stable.



| Fig.20

Single Anterior Implant with Natural Teeth Restorations



Dr. Hyunggu Im
DDS, CAGS, MSD



QR Code by Case

Patient Information

A 28-year-old, Non-smoker.

Treatment Plan

1. Re-endo treatment for teeth #11, 12, 21.
2. In case #21 is not restorable or considered to have a questionable prognosis, it will be removed and replaced by an implant.
3. Post core and crowns for #11, #12.
4. Composite restoration for #13.

Tool that used in surgery

IS-II active, Neo Surgical Kit, Pick-cap Impression Kit

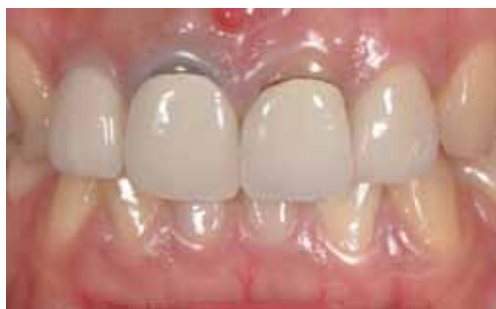

Fig.1 A sinus tract was noted on the buccal surface between #11, #12.

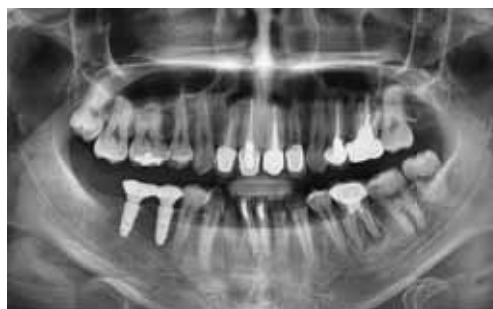

Fig.2 Pre-op Panoramic Radiograph.

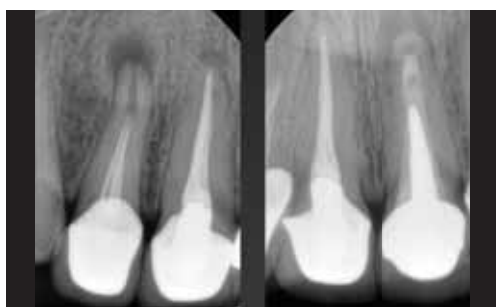


Fig.3 Peri-radicular pathoses on #11,12, 21.

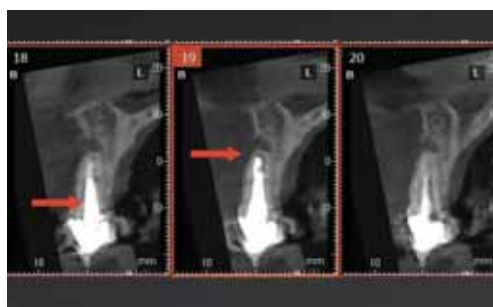

Fig.4 Pre-op CT scan of #21 shows a cast post & core and peri-radicular radiolucency that seems to penetrate the buccal bone at the apex area.

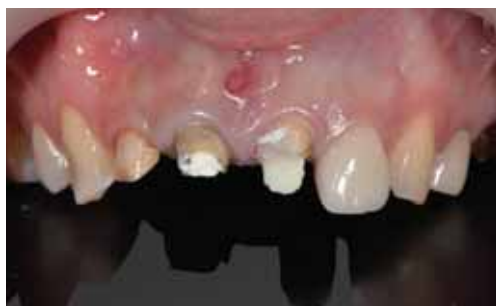

Fig.5 Crowns were removed and re-endo Tx was done for #11, 12, 21. However, the lesion was not resolved. So patient was recommended to remove #21 and place an implant immediately after extraction.

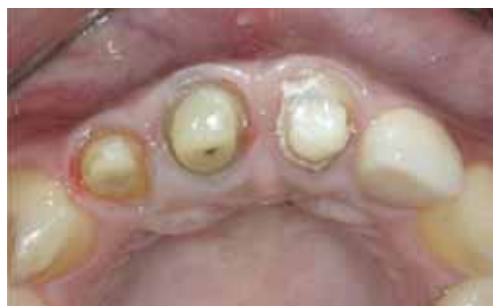

Fig.6 Post-Retreat 2 weeks.

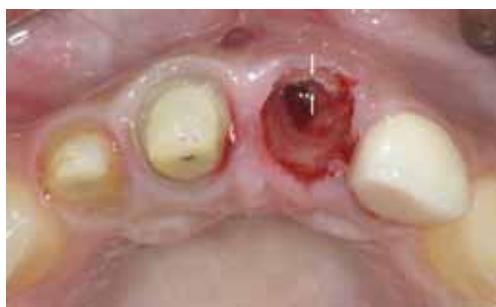

Fig.7 "Socket-shield technique" was used for #21 in an attempt to preserve maximum amount of the buccal bone. Obviously, the granulation tissue was thoroughly removed along with apical portion of the root.

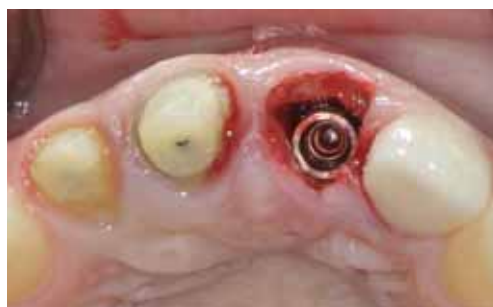

Fig.8 An implant was placed slightly towards the palatal side to make sure the screw access hole comes out at the cingulum area. Also, notice the gap between the implant and the remaining root.

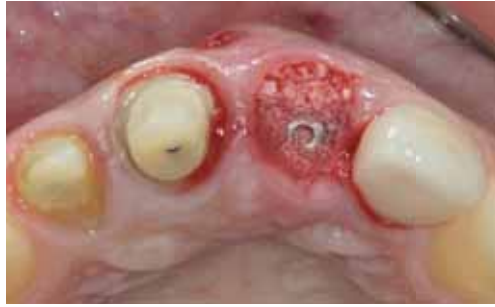

Fig.9 Bovine bone collagen was grafted in the socket .

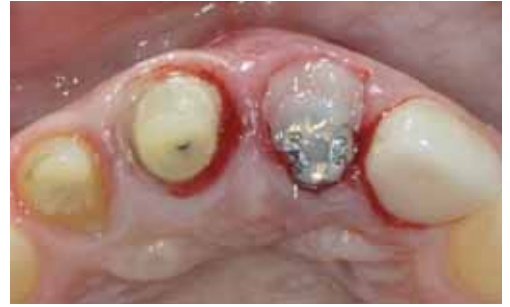

Fig.10 Healing abutment was engaged and the remaining gap was filled directly with flowable composite resin without suture.

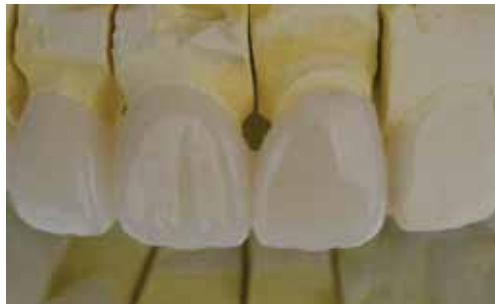

Fig.11 3-unit #11, 12 supported cantilever FPD was fabricated with CAD/CAM PMMA.

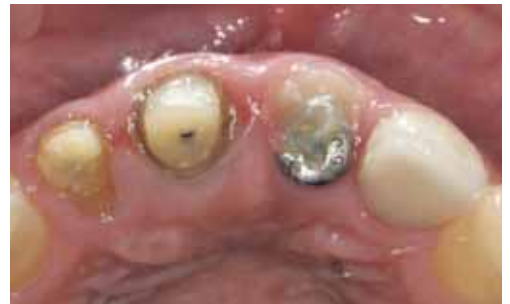

Fig.12 Post-op 10 weeks.

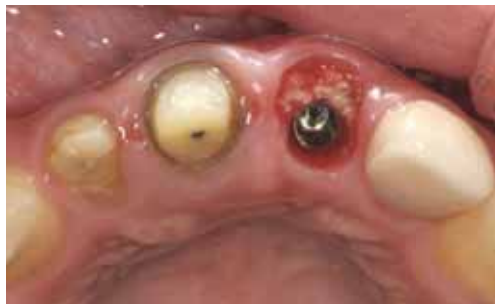

Fig.13 Soft tissue has covered the remaining root. Notice the well preserved contour of the soft tissue on the buccal aspect of #21.

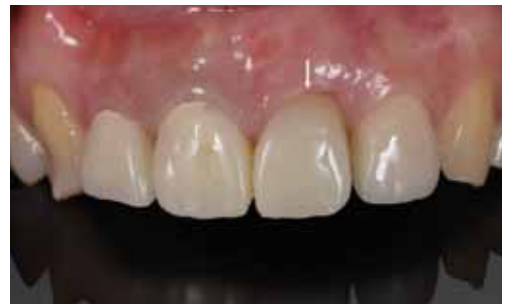

Fig.14 IMPLANT SUPPORTED PROVISIONAL CROWN 3 months after the operation, the 3-unit provisional FPD was converted to a 2 unit splinted crown and a implant supported single crown.



Fig.15 Implant supported provisional crown was adjusted to create a harmonious emergence profile as the contra-lateral natural tooth.

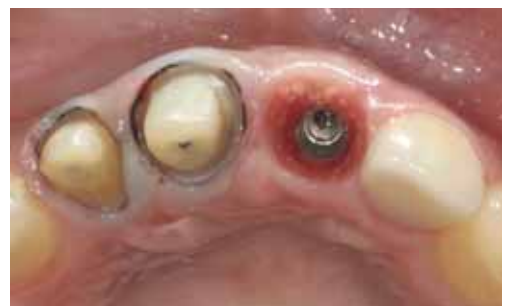

Fig.16 Definitive impression was made. Notice the well preserved architecture of the soft tissue.

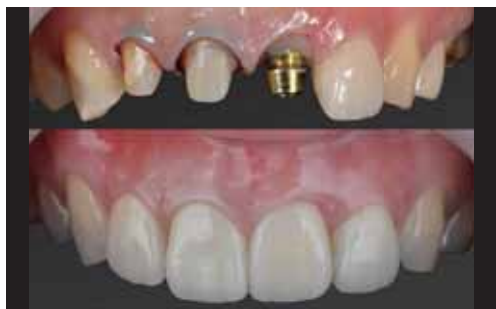

Fig.17 Pick-cap impression coping was used and flowable composite resin was injected into the socket immediately to preserve the emergence profile. PFZ single crowns for #11, 12 and a screw-retained implant supported PFZ crown for #21 were delivered.

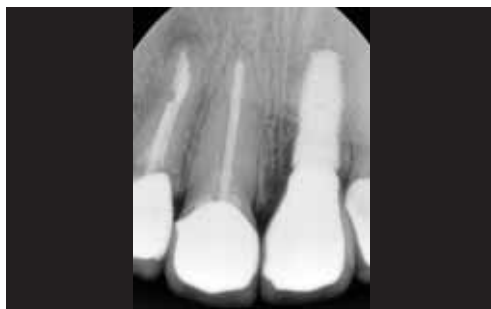

Fig.18 FINAL P/A RADIOGRAPH.

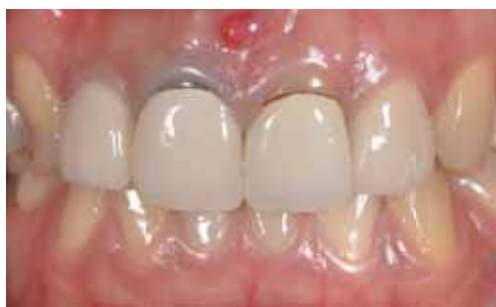

Fig.19 Before treatment.

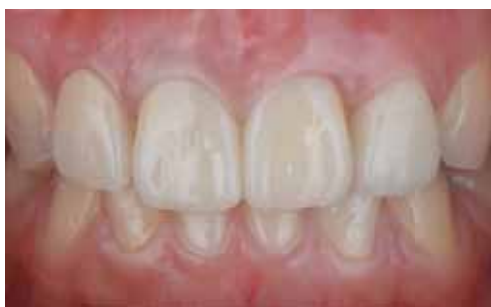

Fig.20 After treatment.

Reverse Planning for Esthetic GBR



Dr. MANUEL FEREGRINO MÉNDEZ
DDS



QR Code by Case

Patient Information

Female patient 32-year-old, with a chronic periapical lesion the reason was a car accident when she was 12 years old.

Treatment Plan

1. The first one is soft tissue augmentation.
2. The second is the implant placement and bone augmentation.

Tools that used in surgery

IS-II active, CTi-mem, EZ-GBR Kit, ACM, Neo Surgical Kit

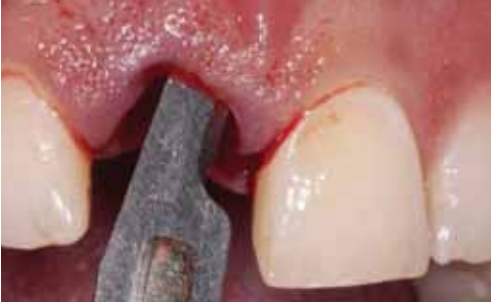

Fig.1 First procedure. Extraction central left incisor, and CTG with Plasma Rich in growth factors.

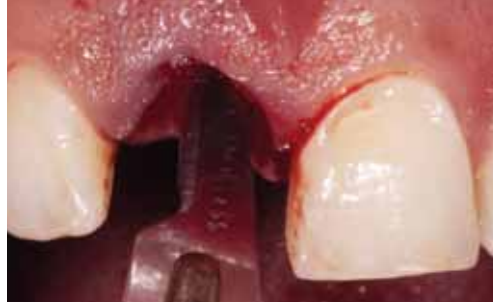

Fig.2

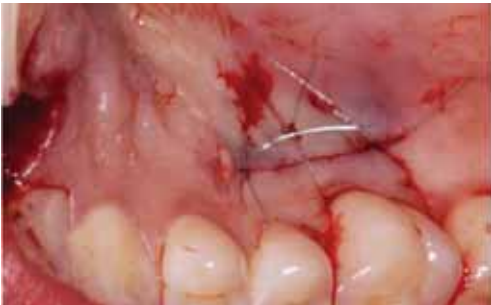

Fig.3

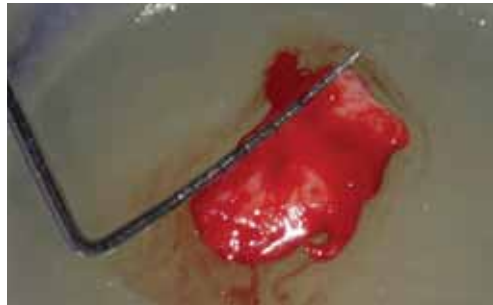

Fig.4

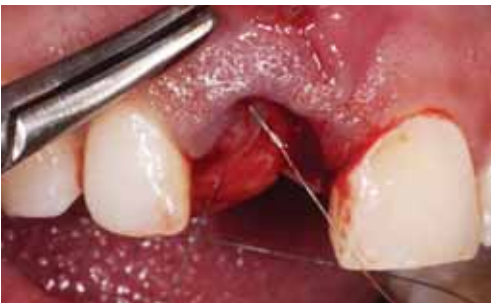

Fig.5 The suturing of the connective tissue draft with a horizontal mattress technique in order to increase the biotype thickness.

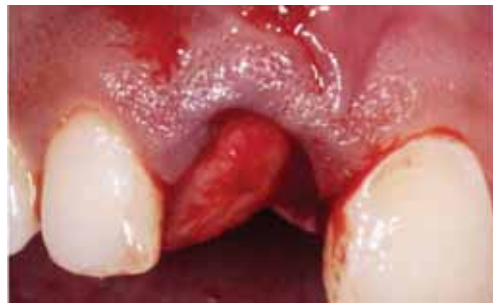

Fig.6

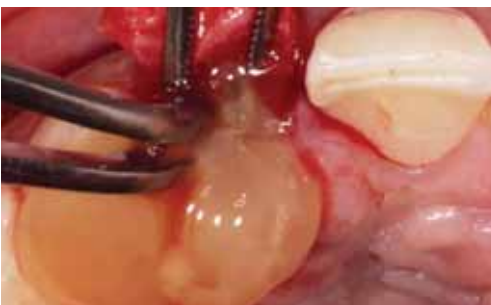

Fig.7 Placement of plasma rich in growth factors in the socket.

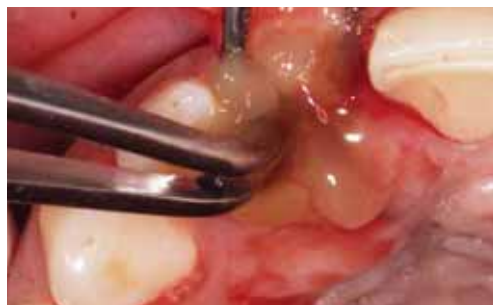
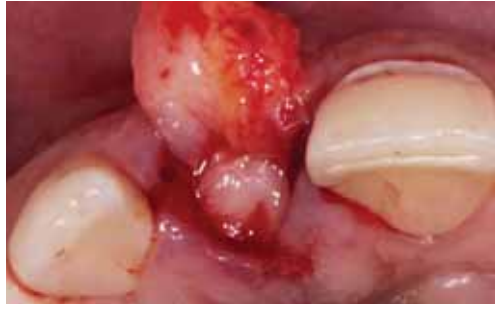
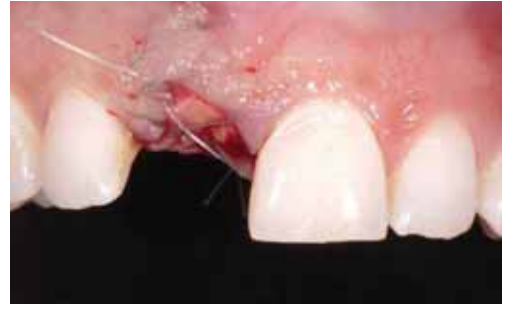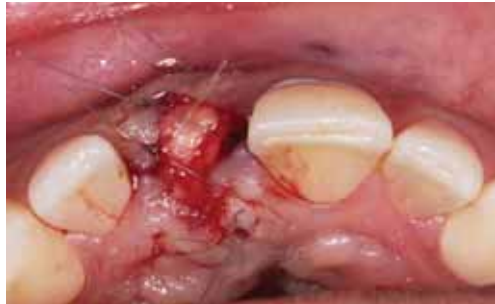Fig.8



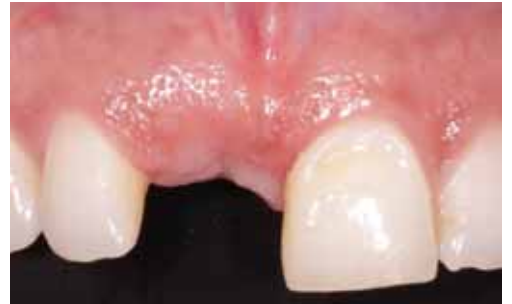| Fig.9



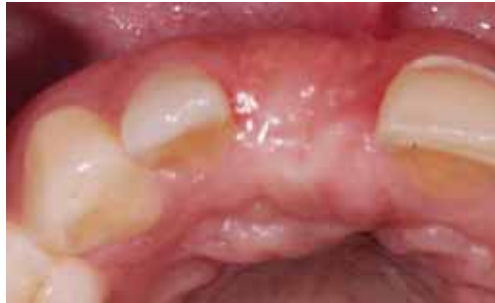| Fig.10 The suturing of the Connective Tissue draft with a horizontal mattress technique in palatal area.



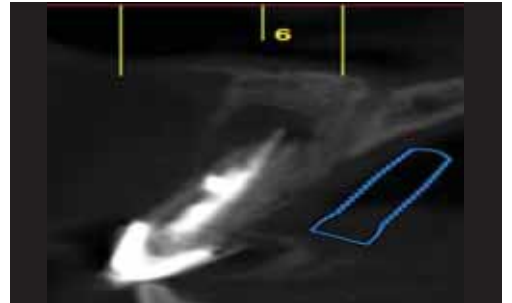
| Fig.11




| Fig.12 Second procedure. 4 months later previous Cone Beam. implant placement ISII and GBR with A3 titanium membrane and PRGF membranes.



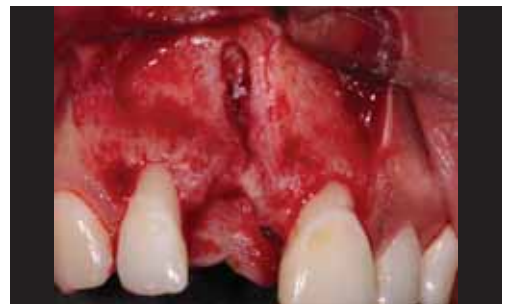| Fig.13



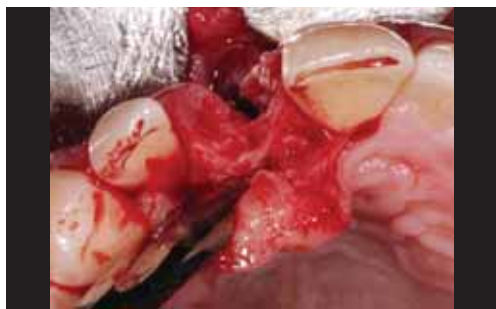| Fig.14



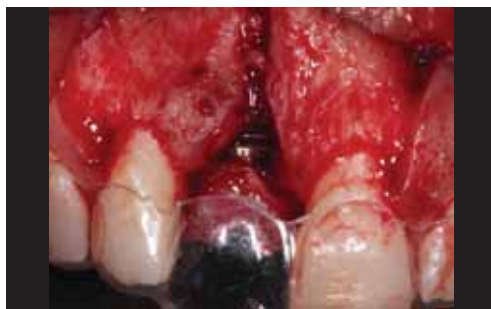| Fig.15



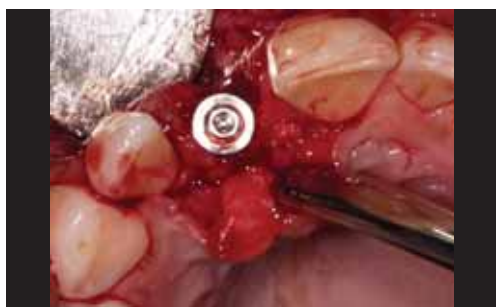| Fig.16



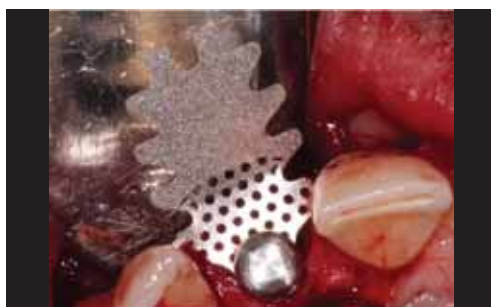| Fig.17



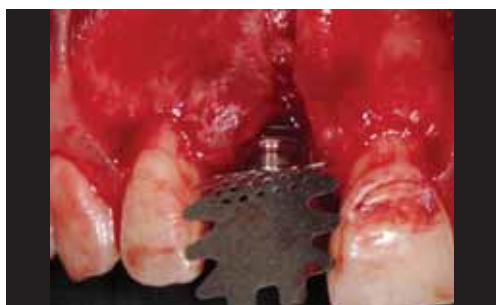| Fig.18



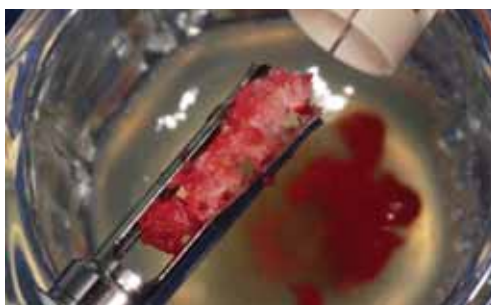
| Fig.19



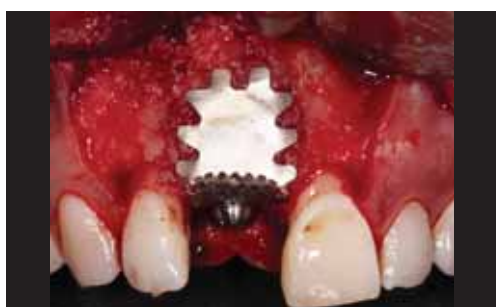| Fig.20 Placement of IS-II implant with a titanium membrane.



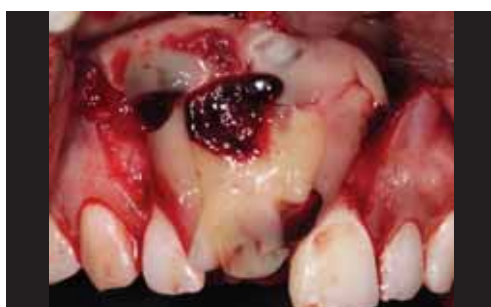| Fig.21



| Fig.22 Auto bone with ACM, CTi membrane and PRGF fibrin membrane



| Fig.23



| Fig.24

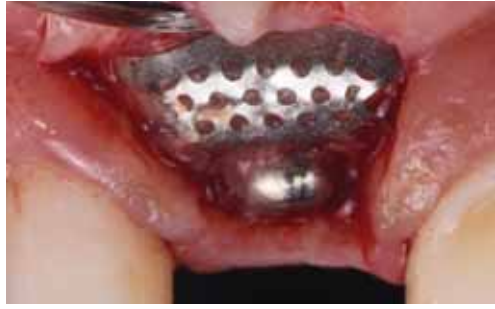

Fig.25 4 months later.

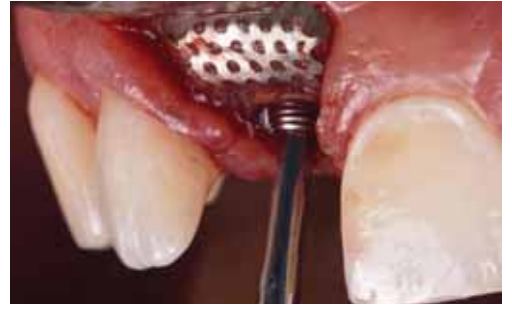

Fig.26

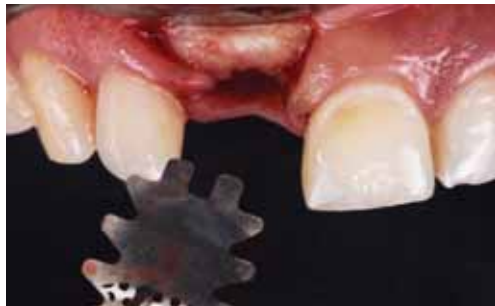


Fig.27

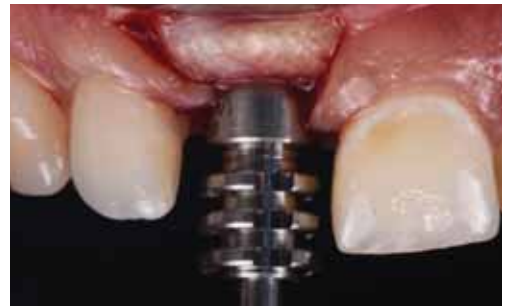

Fig.28 Take the impression during the implant uncovering in order to avoid several reconnections and bone lost.

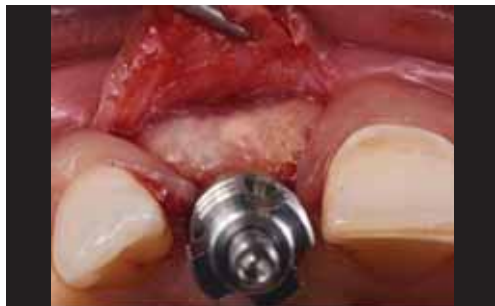

Fig.29

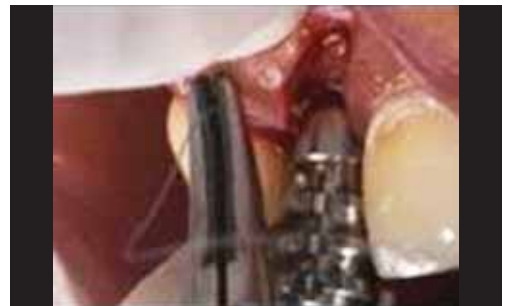

Fig.30

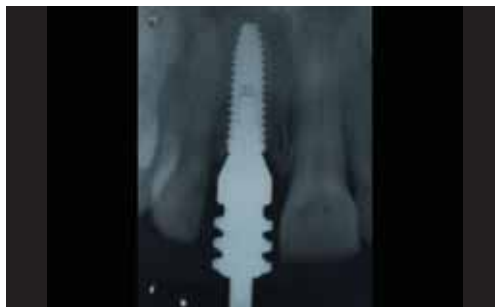

Fig.31

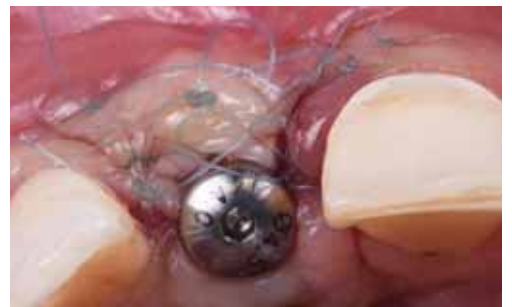

Fig.32

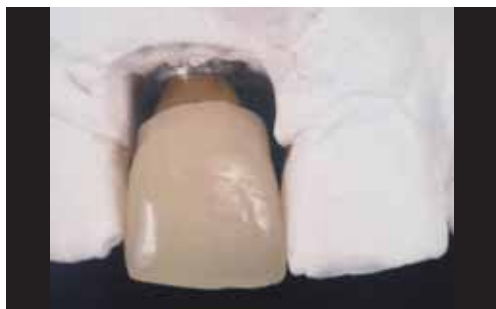

Fig.33 Uncover implant, membrane removal, impression and placement of shapeable abutment with 30 Nm torque and cemented provisional crown.

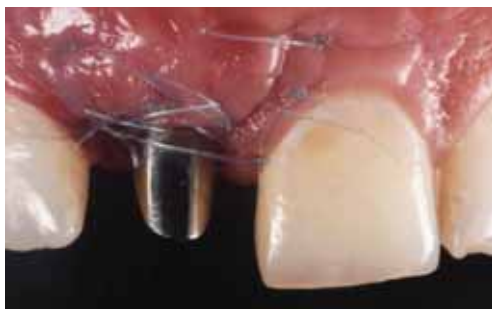

Fig.34

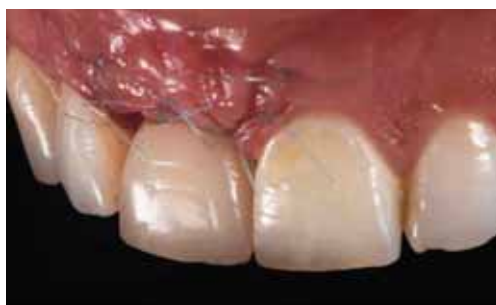

Fig.35

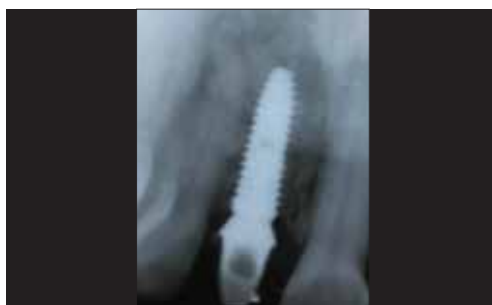

Fig.36

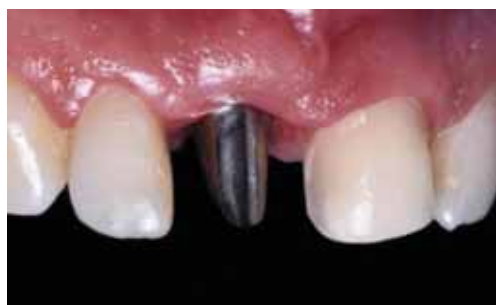

Fig.37 2 months later.

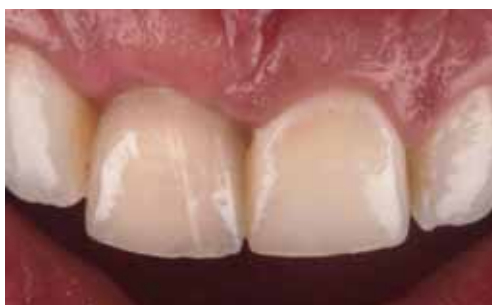

Fig.38

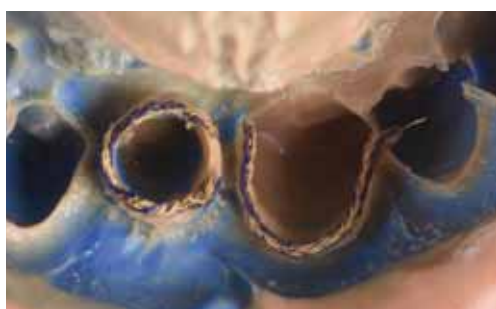

Fig.39 The abutment impression.

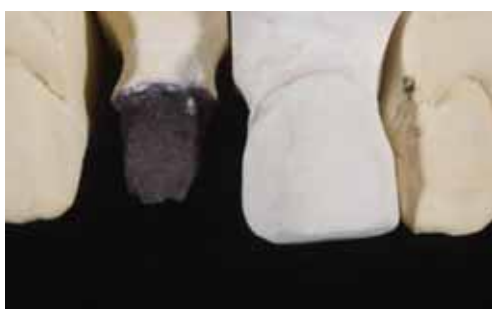
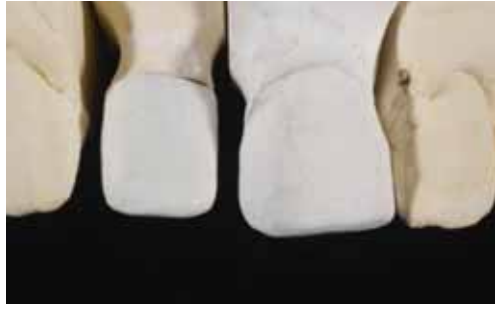
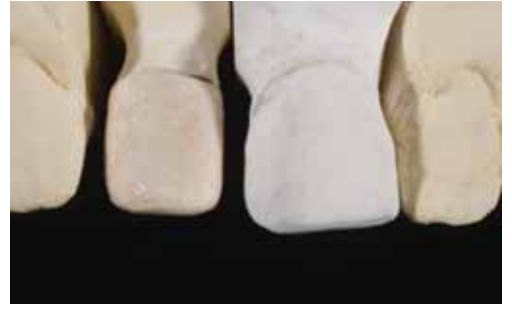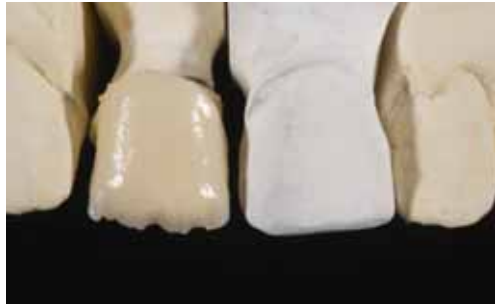Fig.40 Impression of the shapeable abutment, 2 months later and final restoration with a Zirconium crown stratified with feldespatic material.



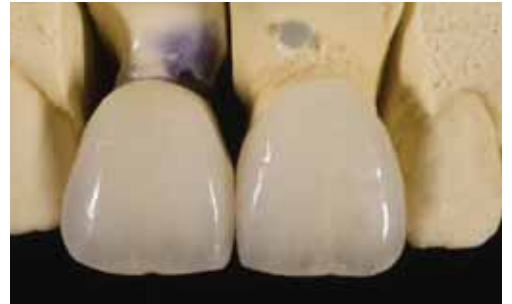| Fig.41



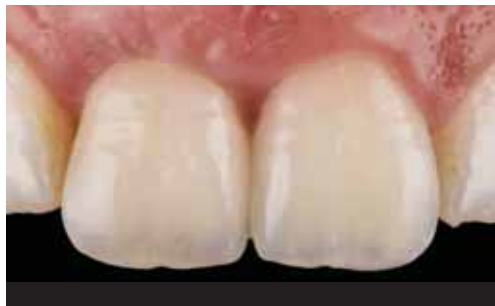| Fig.42



| Fig.43



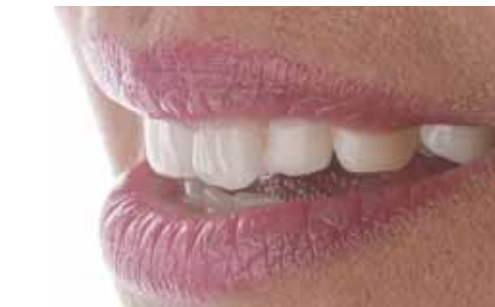| Fig.44



| Fig.45 Final crowns were placed.



| Fig.46 Post follow up 6 months.



| Fig.47

Ridge augmentation and implant placement using CTi-mem and IS II active implant



Dr. Chul-Wan Park
DDS, MSD, CAGS, FICD



QR Code by Case

Patient Information

A 30-year-old female patient had lost teeth 36 and 37 and was referred to the clinic for treatment.

Tools that used in surgery

IS-II active, Neo Surgical Kit, ACM, Tent screw, CTi-mem, GBR Kit

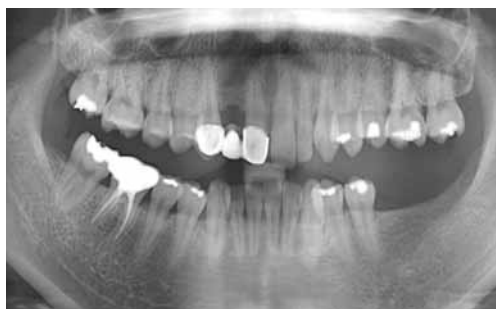

Fig.1 A 30-year-old female patient had lost teeth 36 and 37 and was referred to the clinic for treatment.

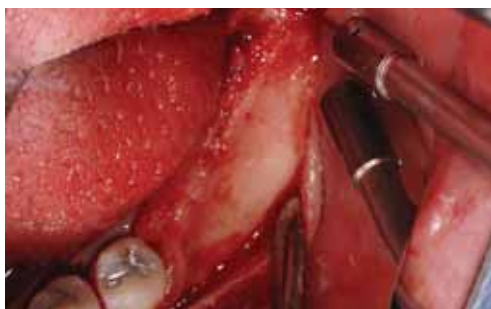

Fig.2 Ridge augmentation was first planned on the mandibular left quadrant, where the crestal width was insufficient for implant placement.

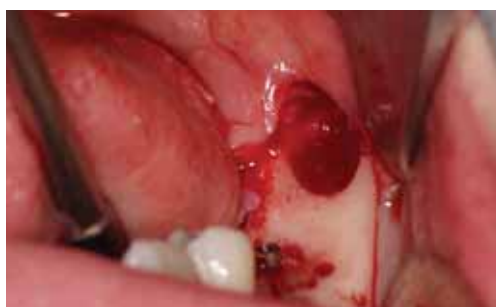

Fig.3 The autogenous bone was harvested using ACM drill.

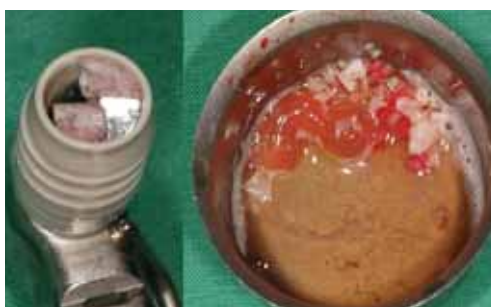

Fig.4 The autogenous bone was harvested in the ramus using the ACM drill. The harvested bone was soaked in PRF.

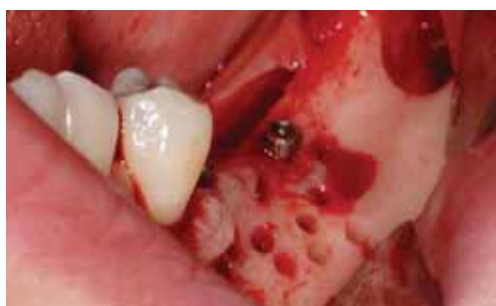

Fig.5 Tent screws were placed after the host bone decortication process.

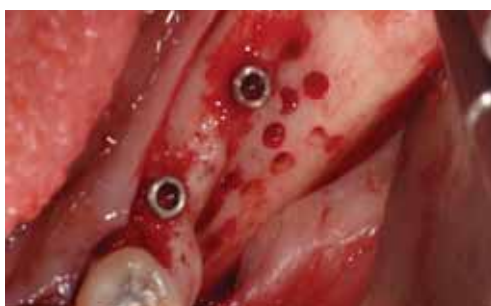

Fig.6 Two tent screws on the recipient site.

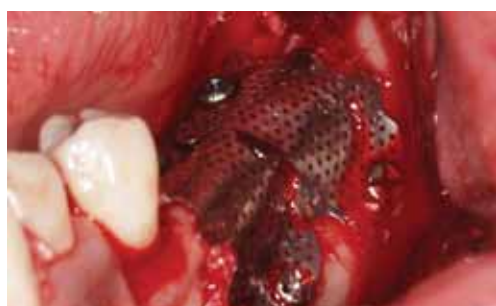

Fig.7 The narrow ridge was augmented using a combination of autogenous bone and xenograft (Bio-Oss) at 1:1 ratio. CTi-mem was fixed over the graft.

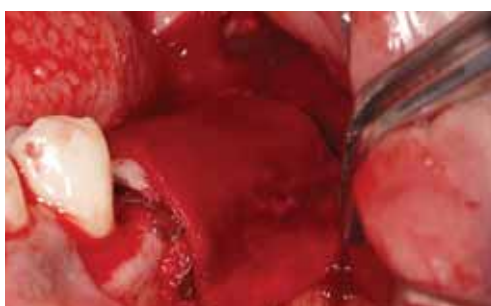

Fig.8 Collatape over the CTi-mem.

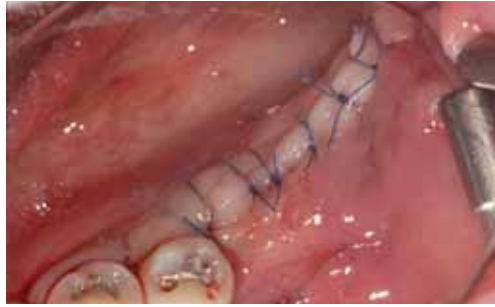

Fig.9 Primary closure was achieved.

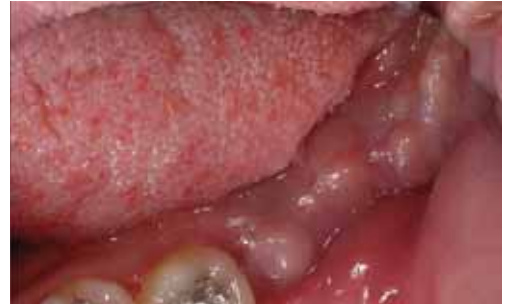

Fig.10 After 4 months of healing.

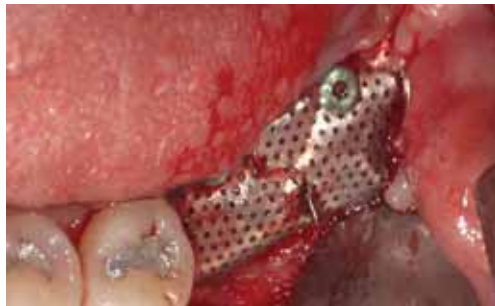

Fig.11 Uncovery was done.

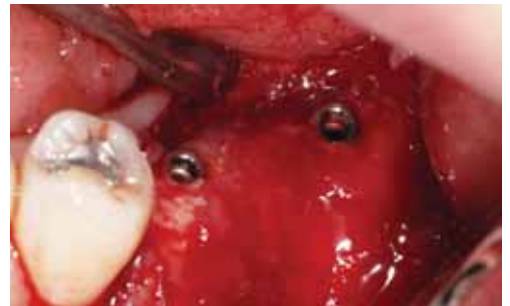

Fig.12 Complete bone regeneration around the tent screws.

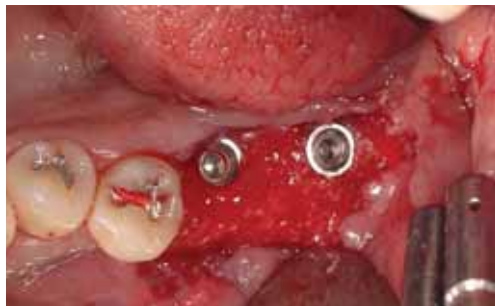

Fig.13 IS II active implants were placed after the tent screws removal.

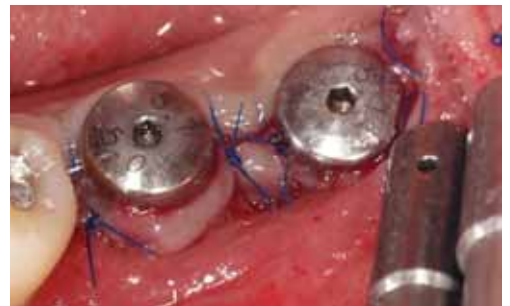

Fig.14 Healing abutments were placed with good primary stability of the implants.

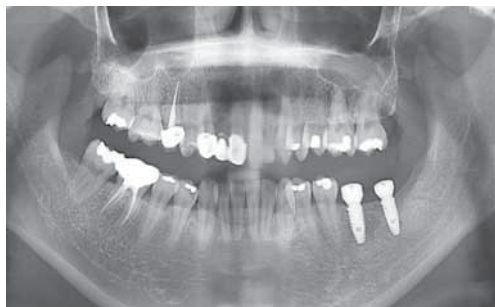

Fig.15 Postoperative panoramic view.

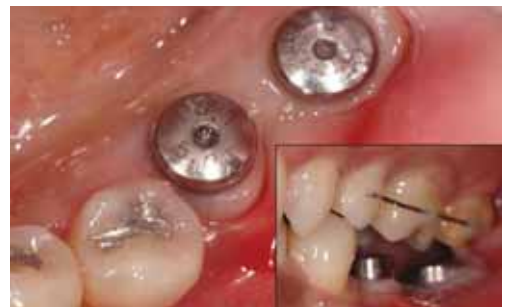

Fig.16 Buccal and occlusal view of the implant site after healing.

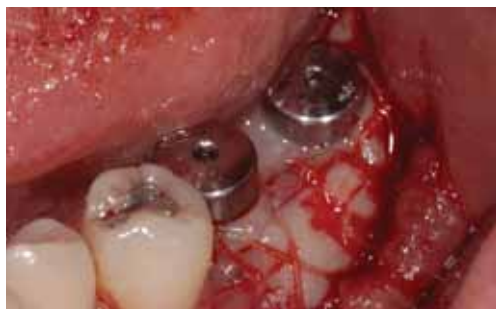

Fig.17 The ridge was exposed with the apically positioned flap and free gingival grafting was conducted for providing keratinized gingiva and deepening the vestibule.

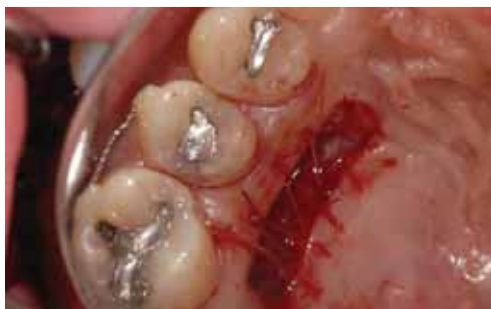

Fig.18 Donor site of free gingival grafting.

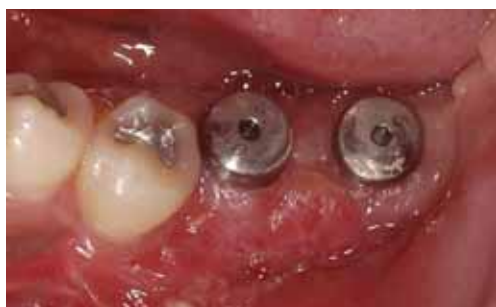

Fig.19 Healing of free gingival grafting.

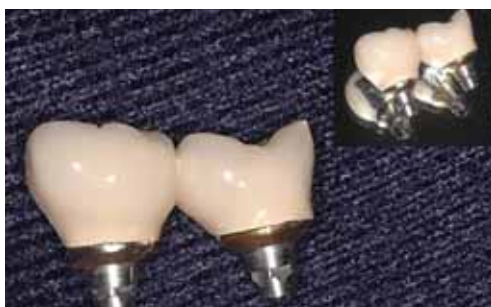

Fig.20 Final restorations were fabricated using the internal SCRPs type of abutments.

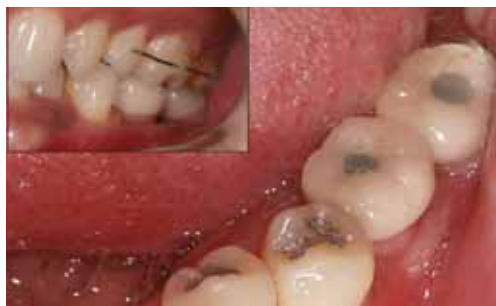

Fig.21 Prosthetic delivery.

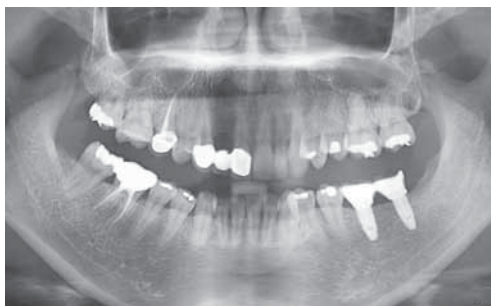



Fig.22 2 year follow-up verified bone crestal level maintenance and stability of peri-implant bone.

Early implant placement of the maxillary central incisor to overcome a thin biotype

Dr. Yong Soo Kim
DDS, CAGS, MSD



QR Code by Case

Patient Information

48 year old female presented to have dental implants on her maxillary anterior tooth and mandibular posterior teeth.

PMH : Non-contributory

No known drug allergy.

PDH : Crown on the tooth #21,#26,#44.

Root canal therapy on the #21,#26.

Missing teeth #37,#45,#46,#47.

Treatment Plan

1. Scaling and root planning.
2. Extraction of the tooth #24, 25, 26, 27, 37 and 38.
3. Root canal therapy and Crown fabrication of the tooth #36.
4. Implant placement of #24,25 and 26 at 2 month after extraction with simultaneous guided bone regeneration.
5. Uncovering at 4 months after the implant placement.
6. Final prosthesis.

Tools that used in surgery

IS-II active, Neo Surgical Kit

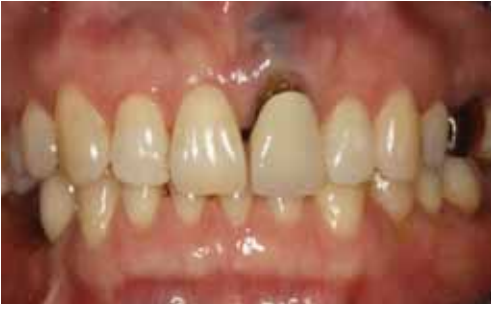

Fig.1 Facial view, gingival recession and supereruption on the tooth #21. Thin gingival biotype was observed.

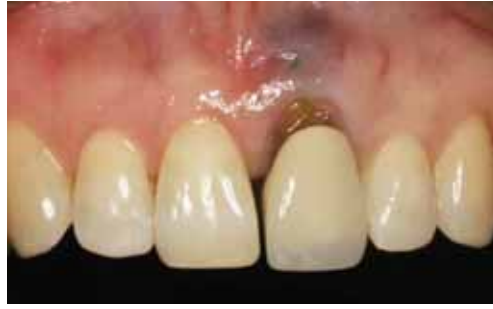

Fig.2

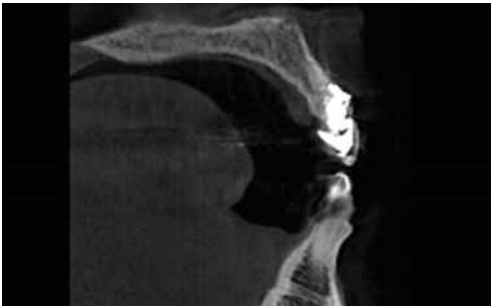

Fig.3 Pre-op CT Scan.

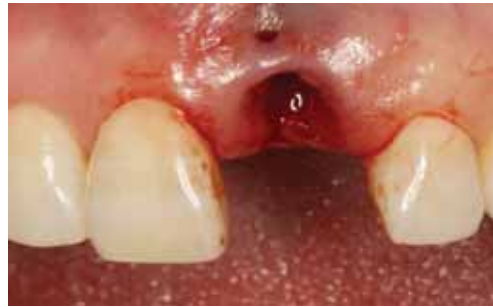

Fig.4 Extraction of the tooth #21.

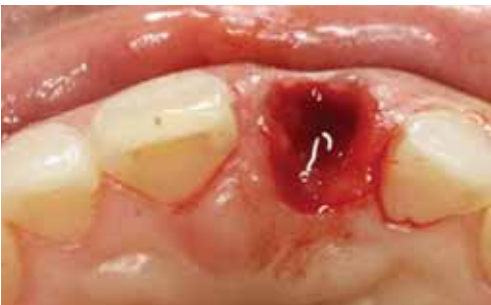

Fig.5

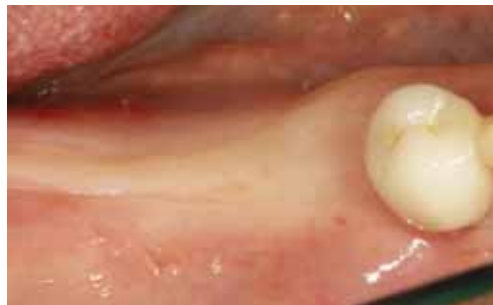

Fig.6 #45,46 implant placement.

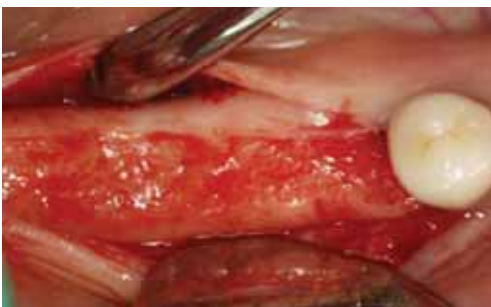

Fig.7

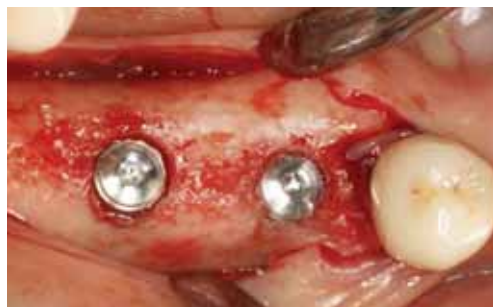

Fig.8 NeoBiotech IS-II active implants were placed on the tooth #45,46. (#45 : 4.0*10, #46 : 5.0*10)

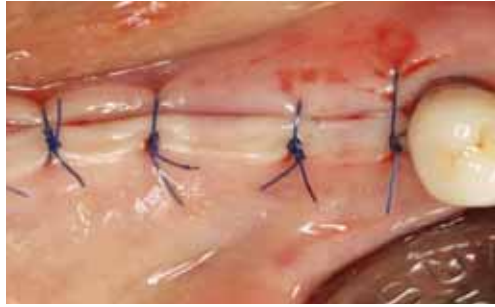


Fig.9

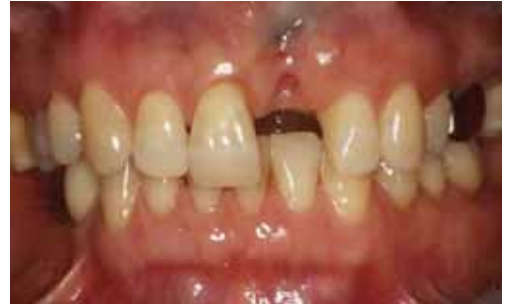

Fig.10 1.5 month of healing after extraction of the tooth #21.

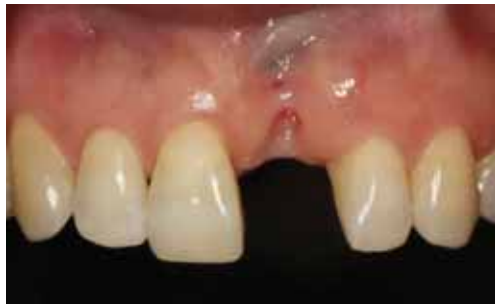

Fig.11

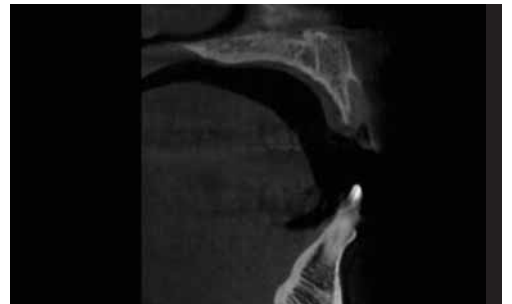

Fig.12 CT scan after soft tissue healing of the tooth #21.

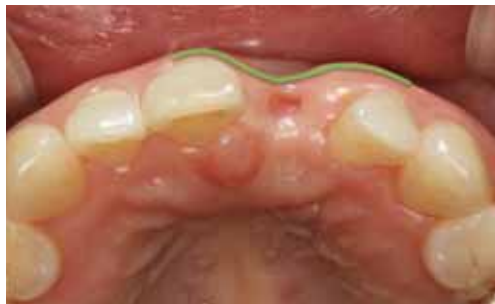

Fig.13

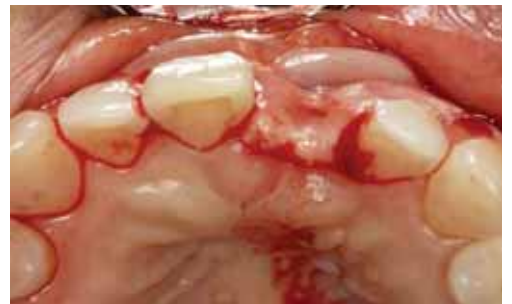

Fig.14 #21 Implant placement.

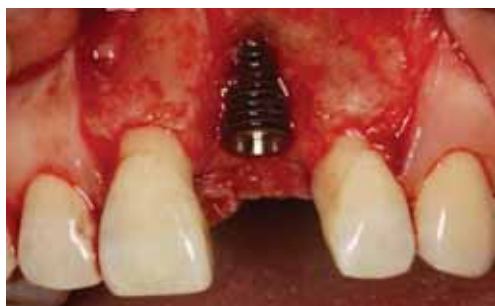

Fig.15 IS-II active 4.0*10 was placed under local anesthesia. Primary stability was achieved. Note buccal dehiscence after implant placement.

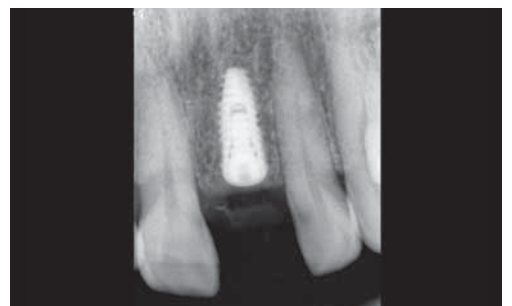

Fig.16

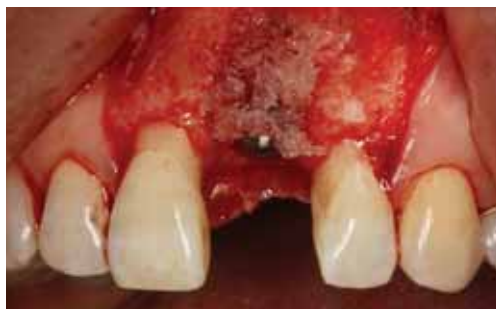

Fig.17 Allogenic bone graft (ICB cortical) was performed and covered with resorbable Collagen membrane.

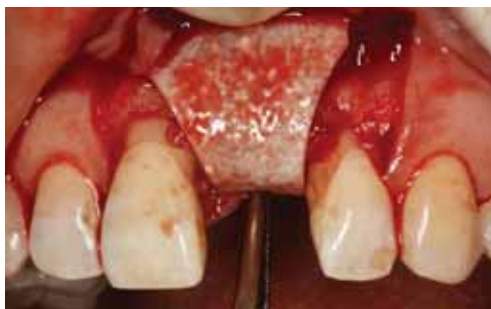

Fig.18

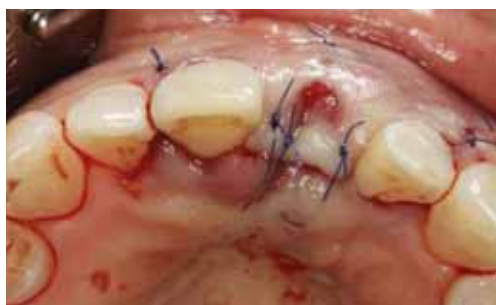

Fig.19 Flaps were sutured by 5-0 Nylon.

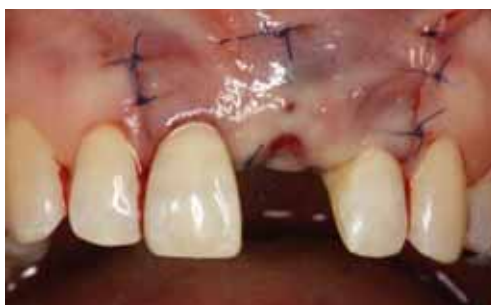

Fig.20

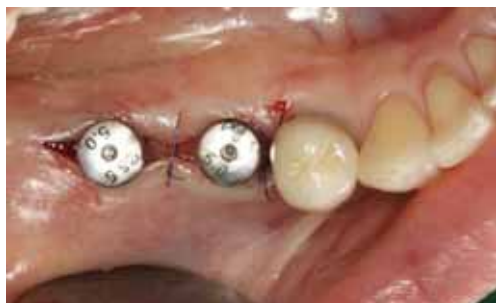

Fig.21 Uncovering of the tooth #45,46.

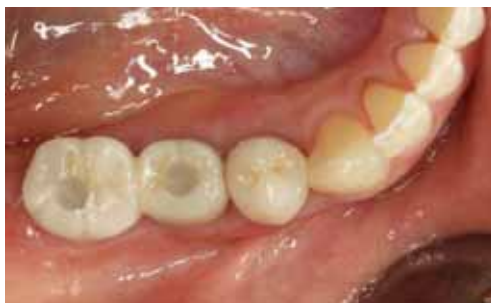

Fig.22 Final prosthesis of the tooth #45,46.

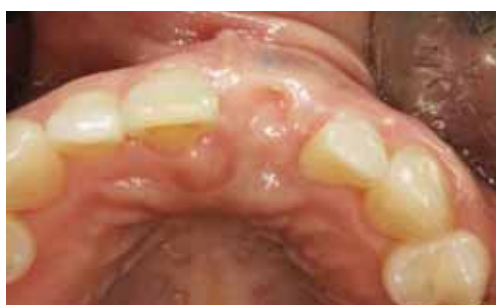

Fig.23 Healing after 4 month of #21 implant placement.

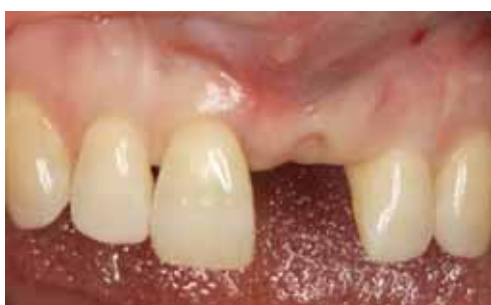

Fig.24

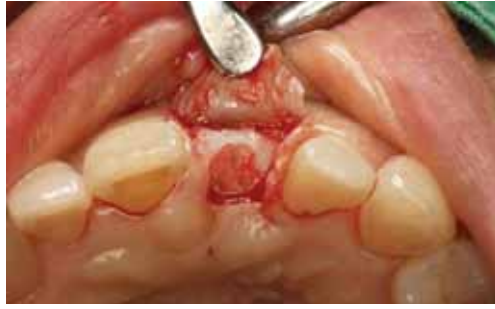

Fig.25 Facial bone regeneration was observed.

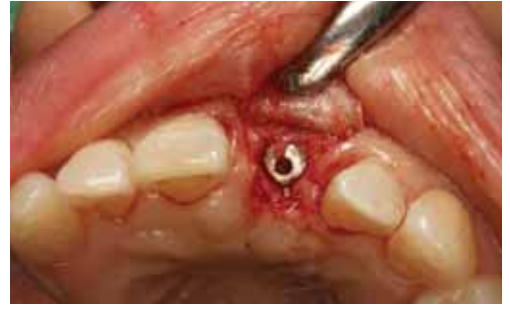

Fig.26

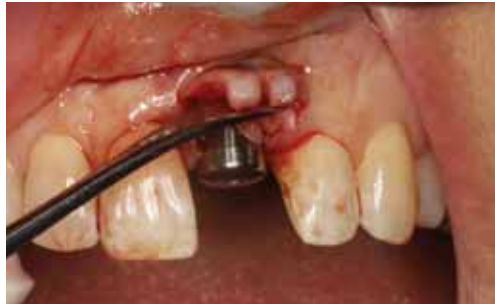

Fig.27 Connective tissue graft was inserted on the facial of side of the implant.

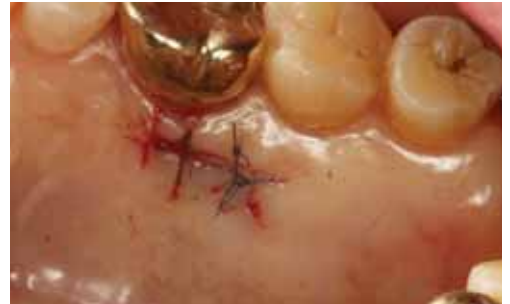

Fig.28

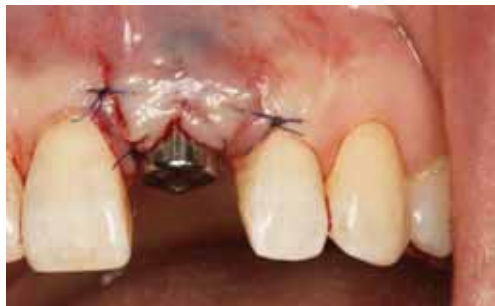

Fig.29 Uncovering of the tooth #21.

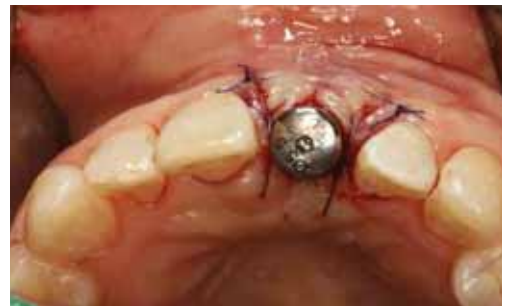

Fig.30

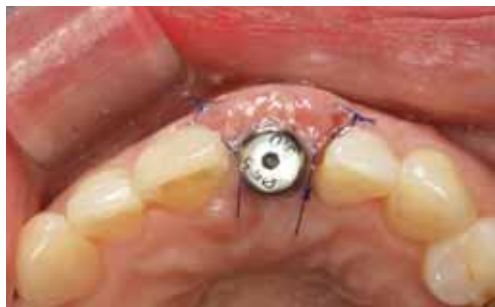

Fig.31 2 weeks follow up after uncovering of the tooth #21.

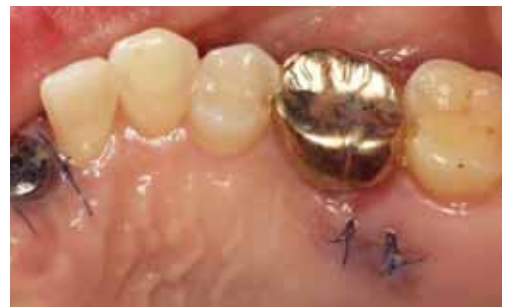
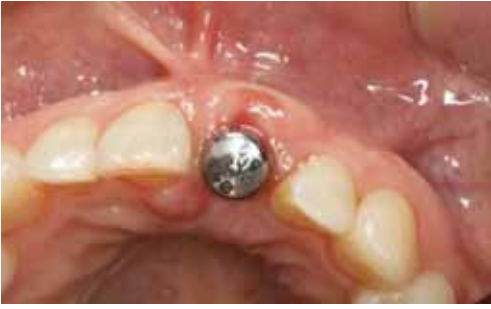
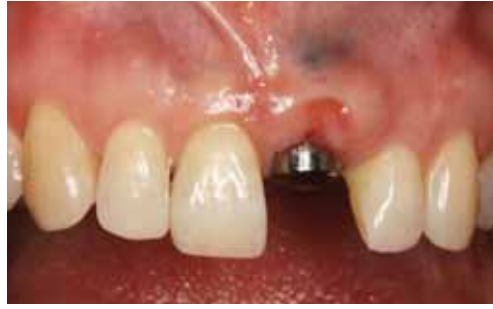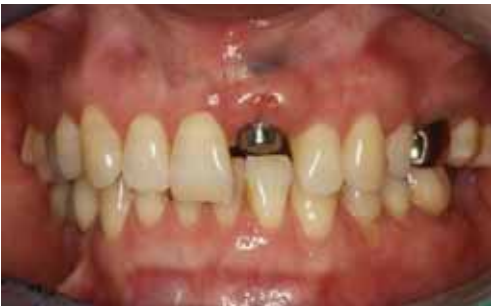Fig.32



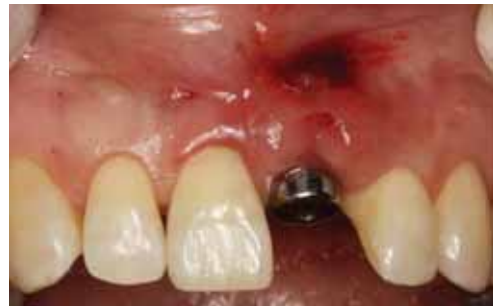| Fig.33 3 weeks after uncovering of #21.



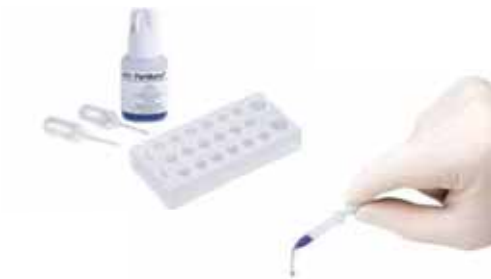| Fig.34



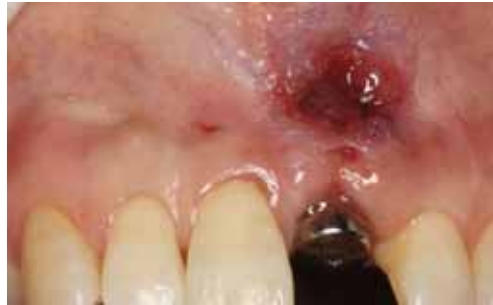| Fig.35 Amalgam pigmentation was removed utilizing #15 blade.



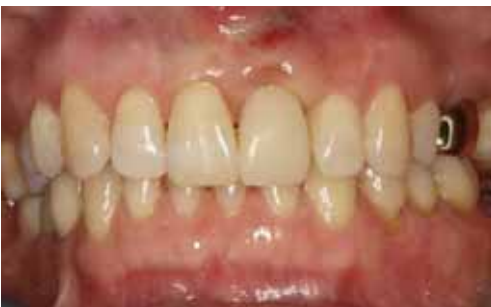| Fig.36



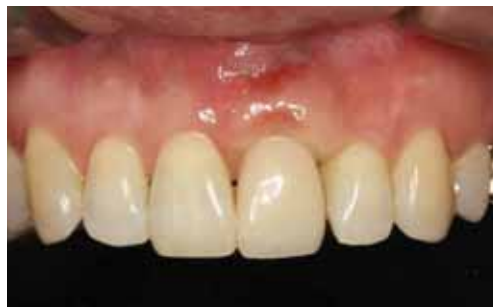| Fig.37



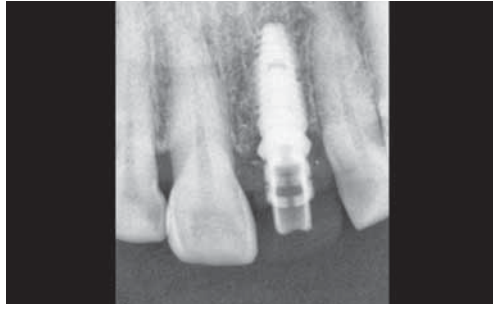| Fig.38 Periacyrl was applied. (no suture)



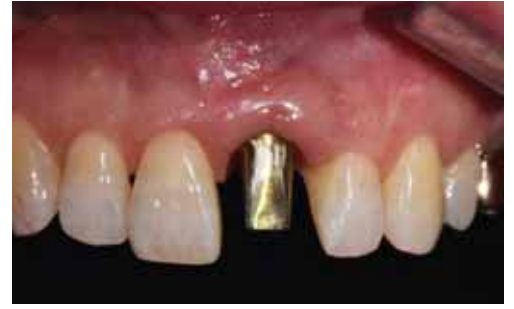| Fig.39 Provisional restoration.



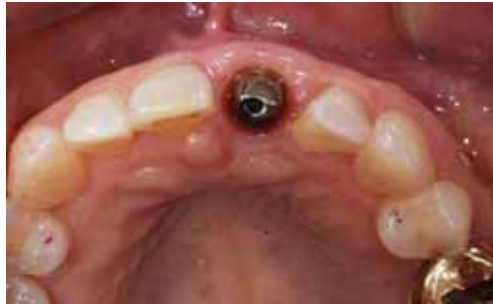| Fig.40



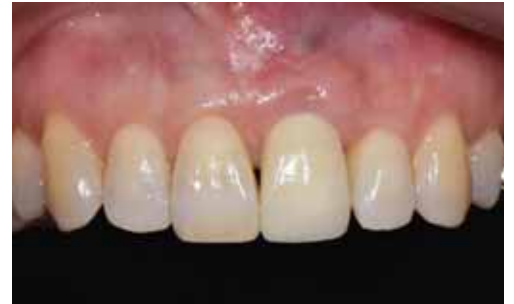| Fig.41



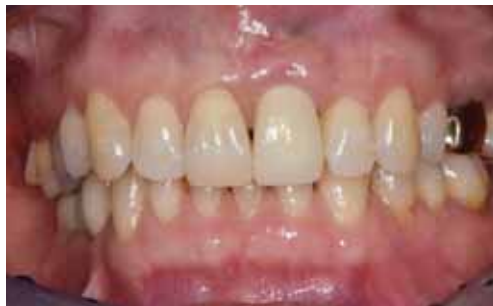| Fig.42 Abutment connection.



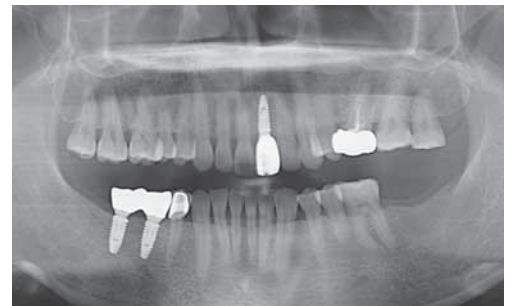| Fig.43



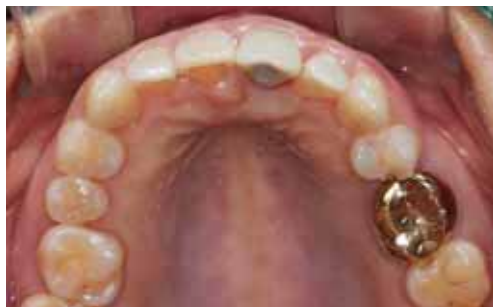| Fig.44 Final prosthesis, facial gingival recession was restored.



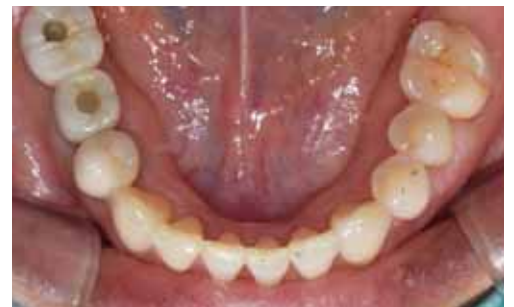| Fig.45



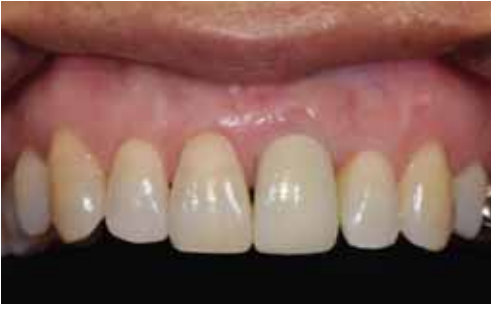| Fig.46 Final prosthesis, panoramic X-ray.



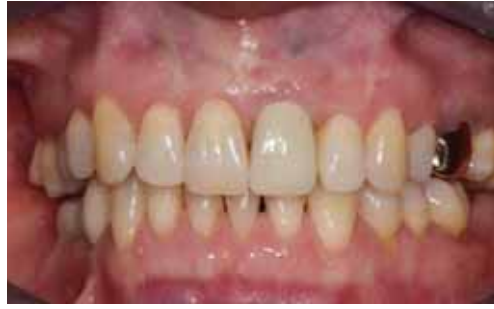| Fig.47 Final prosthesis, occlusal photo.



| Fig.48



| Fig.49 Post-op 1.5 year, stable facial gingival margin.



| Fig.50

Socket shielding immediate implant using Neobiotech IS-II active fixture



Dr. Tan Soon Teik
BDS, MFDS RCS, FICDDE



QR Code by Case

Patient Information

22 years old male.

PMH : Medically fit without any known allergies, non smoker.

PDH : Root canal treatment done on 21.

Chief complain : Fracture tooth no.11 and discoloured tooth no.21.

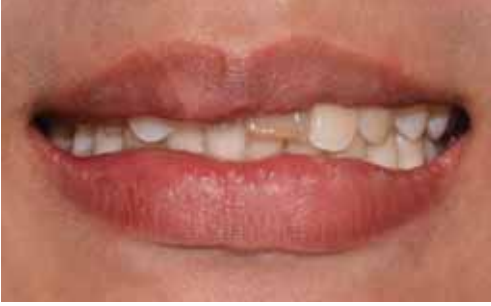Diagnosis : Carious induced fracture on 11 with lesion extending to cervical of tooth 21 internal stain after root canal treatment.

Treatment Plan

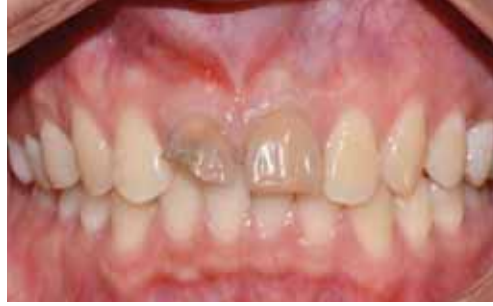1. Immediate extraction with socket shielding technique to preserve labial tissue dimension.
2. Tooth #21 to be treated with internal bleaching and full ceramic crown restoration.

Tools that are used in surgery

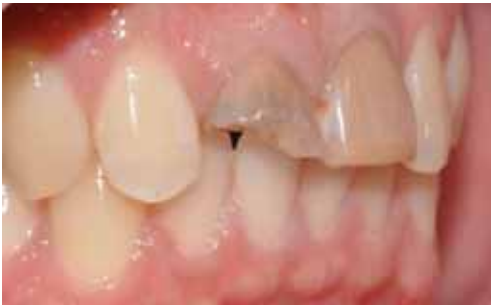IS-II Active, Neo Surgical Kit



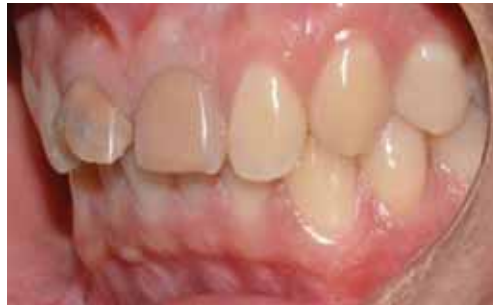| Fig.1 LOW LIP LINE SMILE.



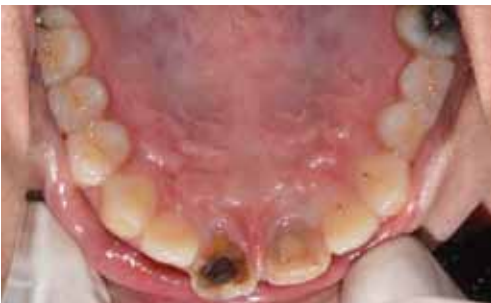| Fig.2 CLSE UP VIEW.



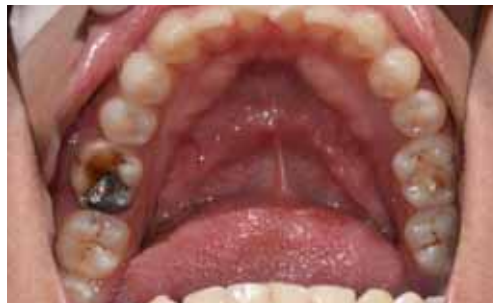| Fig.3 PRE-OPERATIVE.



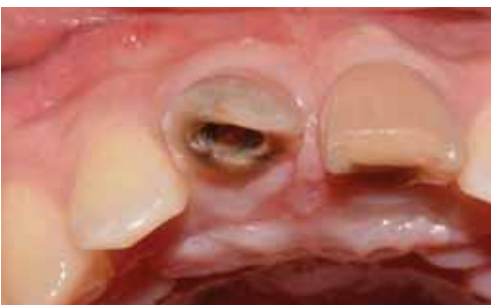| Fig.4 PRE-OPERATIVE.



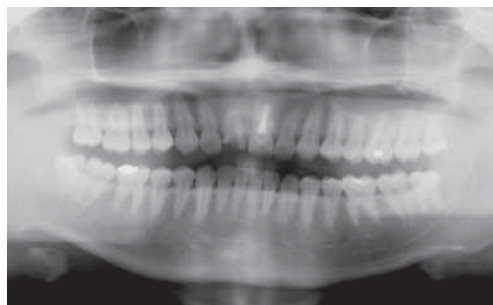
| Fig.5 PRE-OPERATIVE.



| Fig.6 PRE-OPERATIVE.



| Fig.7 PRE-OPERATIVE.



| Fig.8 OPG.

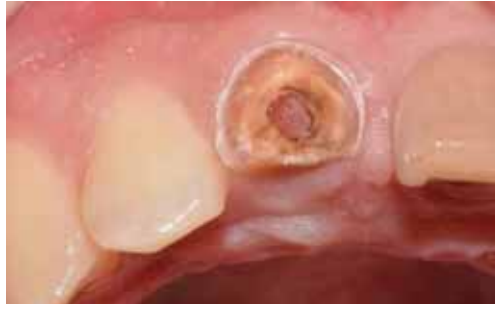

Fig.9 Decoronation of tooth and caries removal.

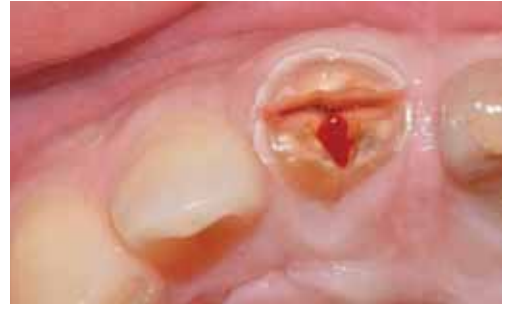

Fig.10 Tooth splited with high speed handpiece.

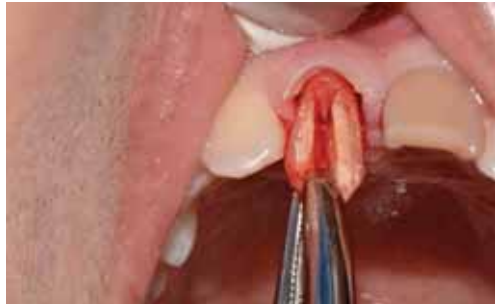

Fig.11 Palatal root fragment removed.

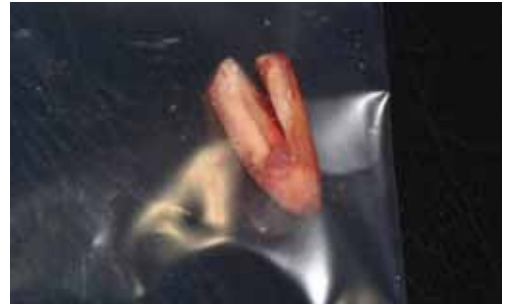

Fig.12 Extracted root.

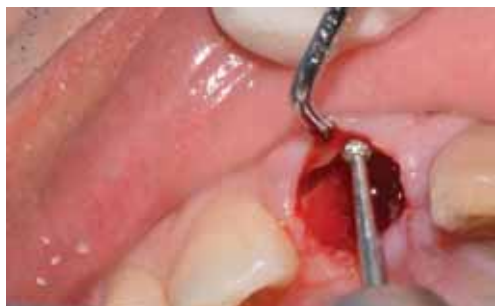

Fig.13 Re-adjust labial root height.

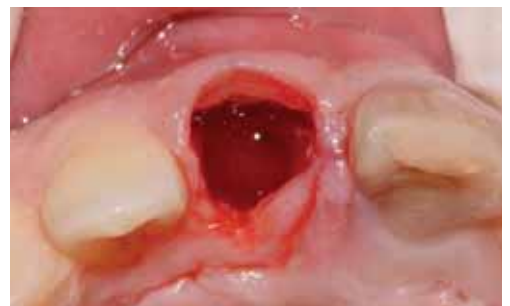

Fig.14 Final position just at crestal bone height.

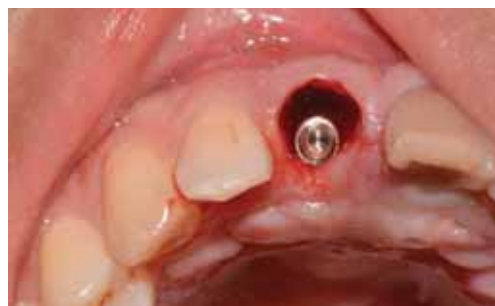

Fig.15 NEOBIOTECH IS-II Implant was placed more palatally giving sufficient jumping distance.



Fig.16 Less than 20Ncm torque was achieved. Implant was not immediately loaded.

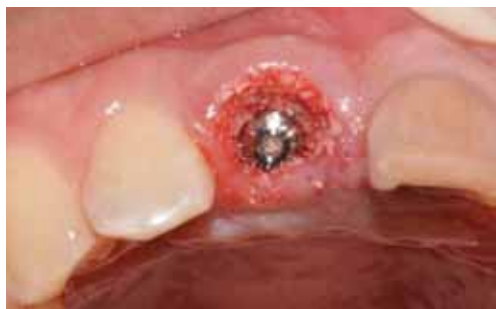

Fig.17 A small healing abutment was placed to allow more soft tissue to grow. Regenoss allograft was used to fill the jumping distance.

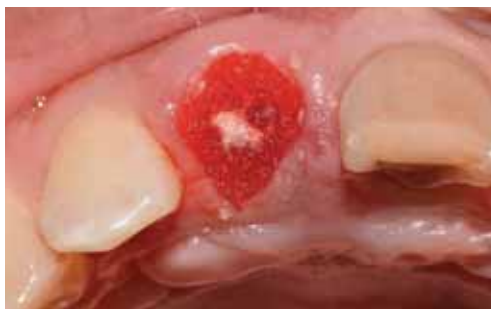

Fig.18 Collagen fleece was used to cover on top of the extraction socket.

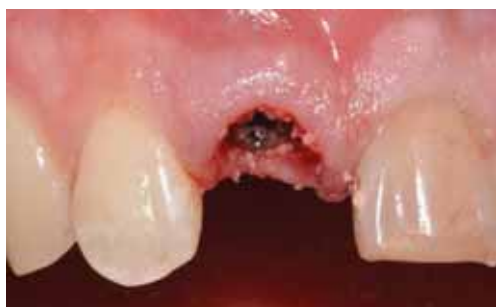

Fig.19 Frontal view.

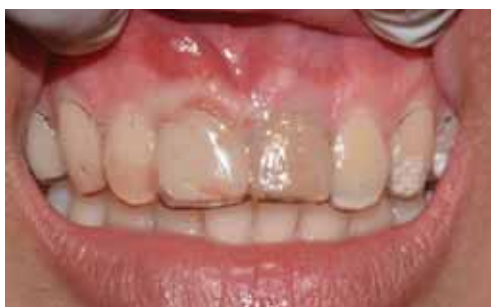

Fig.20 Provisional with Essix retainer with acrylic tooth.

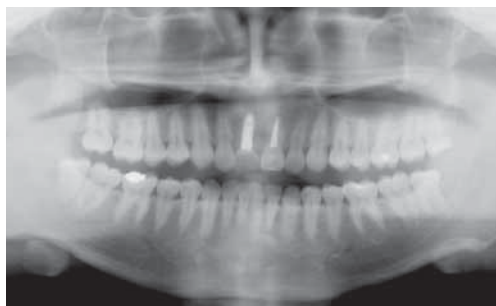

Fig.21 POST-OPERATIVE OPG.

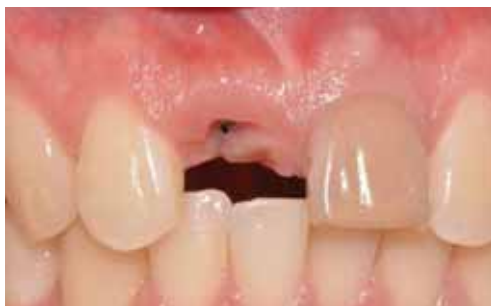

Fig.22 3 MONTHS POST OPERATIVE.

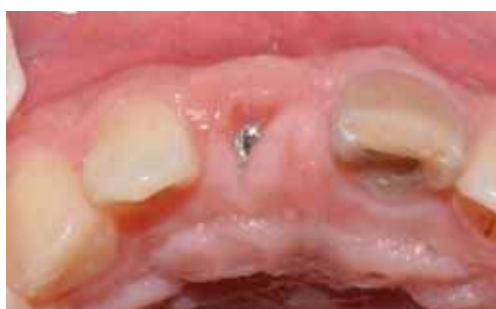

Fig.23 3 MONTHS POST OPERATIVE.

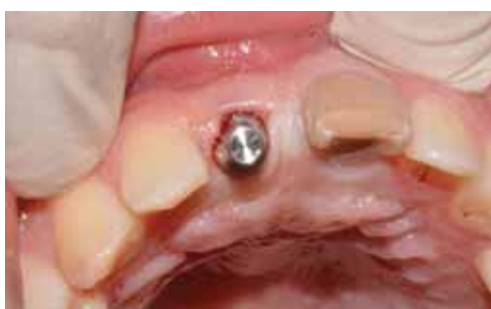

Fig.24 IMPRESSION FOR PROVISIONAL.

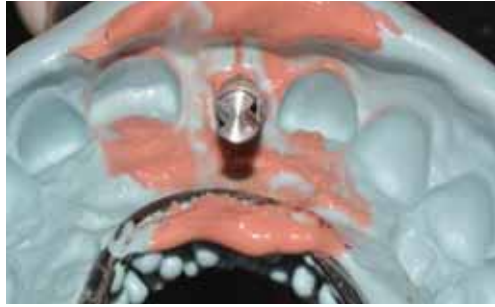

Fig.25 IMPRESSION FOR PROVISIONAL.

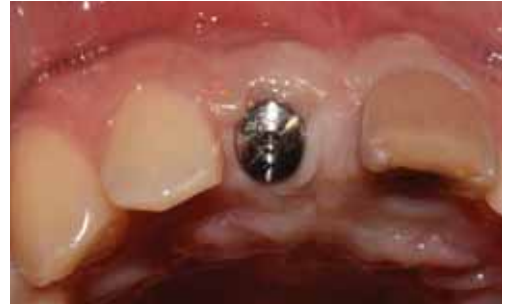

Fig.26 PROVISIONAL CROWN. LARGER HEALING ABUTMENT TO PUSH OUT SOFT TISSUE.

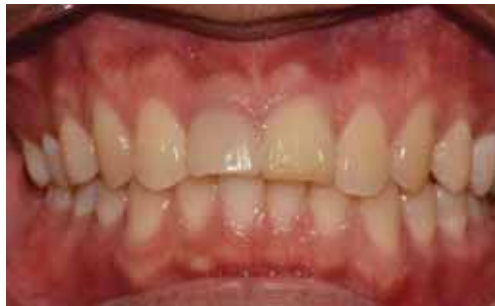

Fig.27 PROVISIONAL CROWN .PROVISIONAL CROWN IN PLACE, INTERNAL BLEACHING ON 21.

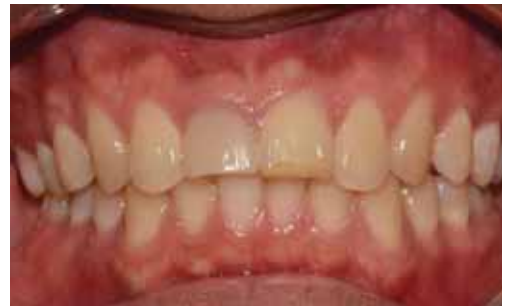

Fig.28 FINAL IMPRESSION. GINGIVA LEVEL ON 11 WAS STILL SLIGHTLY CORONAL COMPARE TO 21 BUT PATIENT DID NOT MIND.

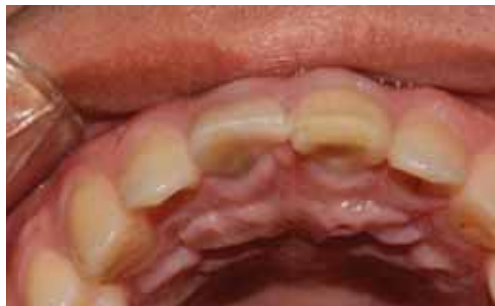

Fig.29 FINAL IMPRESSION.SINCE PATIENT IS STILL IN HIS 20S, IT IS NOT A BAD IDEA TO LEAVE THE SOFT TISSUE A BIT CORONALLY IN CASE OF FUTURE RECESSON.

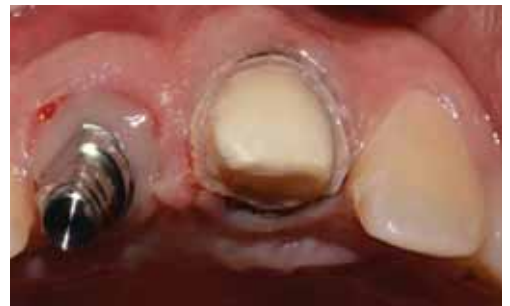

Fig.30 FINAL IMPRESSION. EMERGENCE PROFILE MAINTAINED AND RECORDED WITH CUSTOMIZED IMPRESSION COPPING.

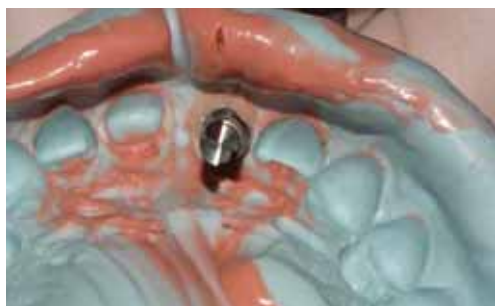

Fig.31 FINAL IMPRESSION.

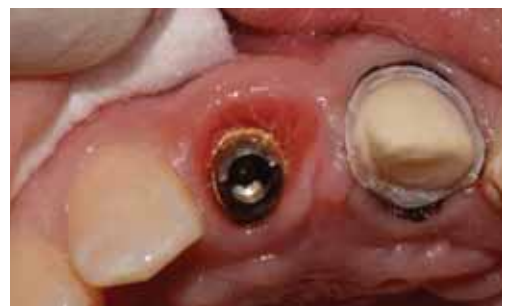

Fig.32 FINAL PROSTHESIS. CEMENTABLE UCLA ABUTMENT WAS USED.

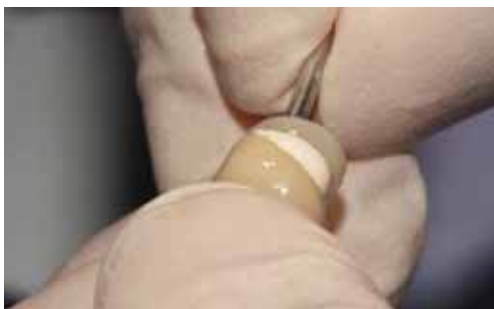

Fig.33 FINAL PROSTHESIS.EXCESS CEMENT REMOVED FROM A DUPLICATED DIE.

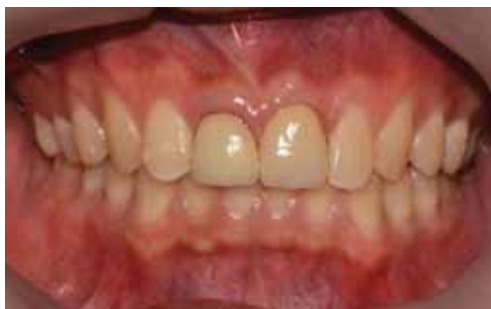

Fig.34 FINAL PROSTHESIS.FRONTAL VIEW.

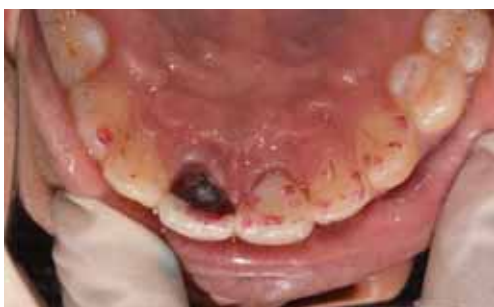

Fig.35 FINAL PROSTHESIS. EVEN OCCLUSAL CONTACT.

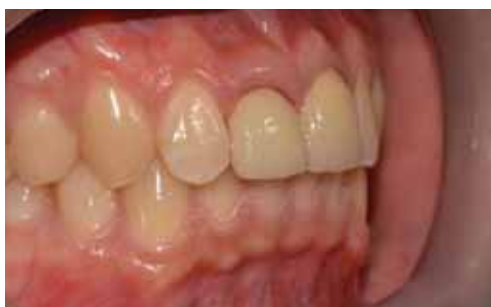

Fig.36 FINAL PROSTHESIS.

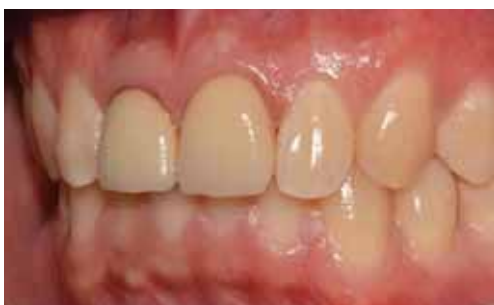

Fig.37 FINAL PROSTHESIS.

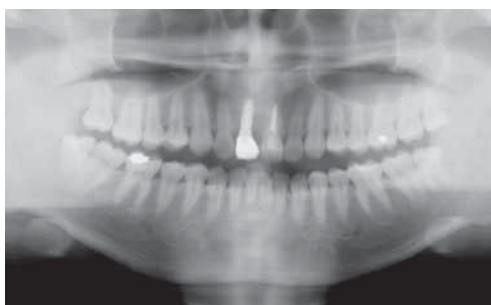


Fig.38 FINAL OPG.

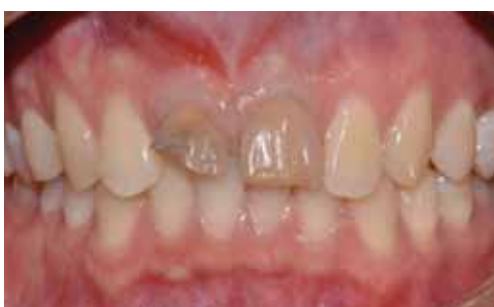

Fig.39 FINAL COMPARISON. (Before)

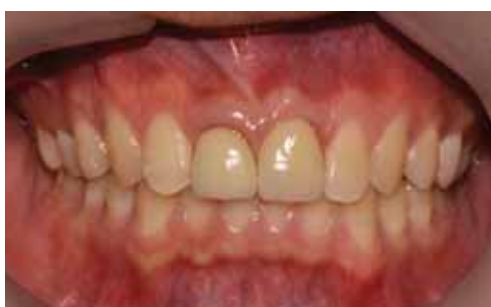

Fig.40 FINAL COMPARISON. (After)



Restorative

SCRIP

Anterior esthetic restoration

Posterior zirconia restoration

Full mouth rehabilitation

Over denture

8 Years Follow-up Case of Class III CMI/CM Fixation in the Maxillary 1st and 2nd Molar Area

Jongyub Kim
DDS, MS, Ph.D



QR Code by Case

Patient Information

A 62-year-old, No history of alcohol consumption or smoking.

Treatment Plan

The residual alveolar bone height at #26 and 27 sites was measured as 6-8mm from the panoramic view. In this case, there were three choices to make: Class I CMI fixation with 6-7mm short implants without involving the inferior cortical wall of the sinus; Class II CMI fixation with 7-8.5mm long implants without bone graft; Class III CMI/CM fixation with 8.5-10mm long implants with crestal bone graft. In this case, Class III fixation was chosen after long discussion with the patient. She wanted to have longer implants. So we decided to place two 5x10mm implants with 3-5mm sinus elevation with the SCA technique.

Tools that used in surgery

EB-II Active, EB/IT Kit, SCA Kit

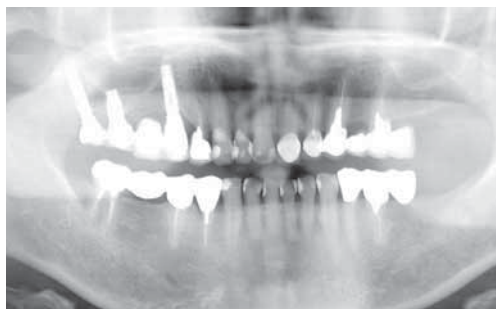

Fig.1 Panoramic view at the first visit showed cantilever bridges on #23-25-X area & #34-35-X. Implant placement was planned at #26,27, and #35, 36 & 37 area.

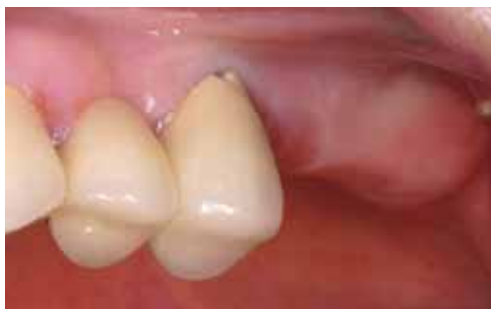

Fig.2 A labial view of the left posterior area showed enough attached gingiva and a broad ridge at the #26 & 27 area.

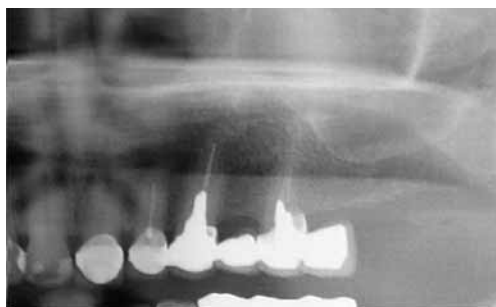


Fig.3 A radiograph showing 7-8mm and 6-7mm residual bone heights at the #26 and #27 sites respectively. This case was classified as Class III CM fixation, where implant placement was performed simultaneously with sinus graft. Prior to the placement of a 10mm long implant, the SCA kit was used to aid sinus grafting procedure.

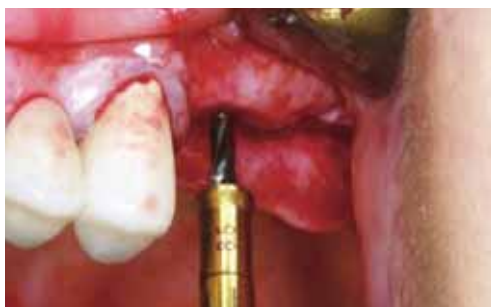

Fig.4 A crestal incision was made for flap reflection, and a 2mm twist drill with a stopper 1mm shorter than the residual bone was used to drill up to 1mm short of the sinus floor.

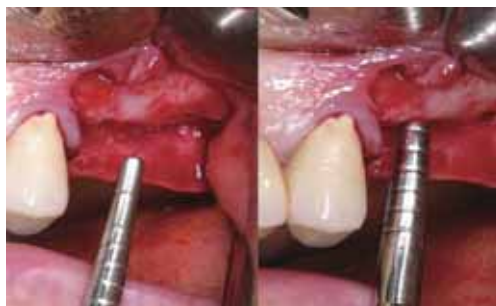

Fig.5 Lateral osteotomes were used to compact soft bone laterally. The bone density was D442.

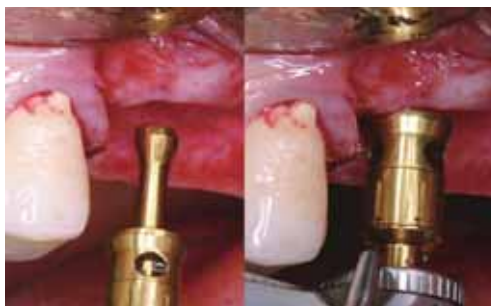

Fig.6 The Ø3.2mm diameter S-reamer was used to penetrate the sinus floor.

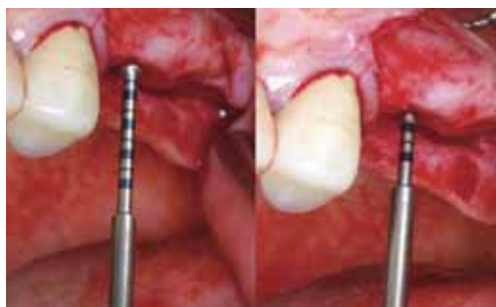

Fig.7 As the depth gauge goes down into the osteotomy opening, it must remain in contact with the lateral wall of the osteotomy site all the time. The operator should feel the hard resistance at the bottom if the cortical bone of the sinus floor is not completely drilled through. The same procedure is repeated until the operator notices a drop with the depth gauge.

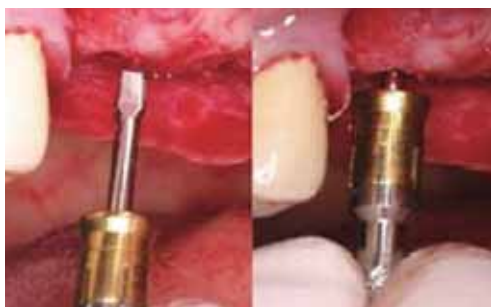

Fig.8 The space created between the sinus floor and the lifted membrane was filled with 0.5cc of FDDBA (RegenOss, Cellumed, Korea). A bone spreader with 10mm stopper was used to detach the membrane by spreading the bone laterally in the space created by lifting the sinus membrane. It reduces the tension on the membrane so that more bone could be inserted without the membrane tearing.

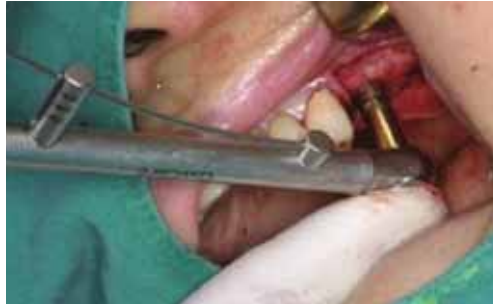

Fig.9 Two implants (EB 5.0X10mm, Neobiotech, Korea) were inserted. The insertion torques obtained for #26 and 27 were 40 and 25 Ncm respectively. Class III CMI/CM fixation played a major role for high insertion torques.

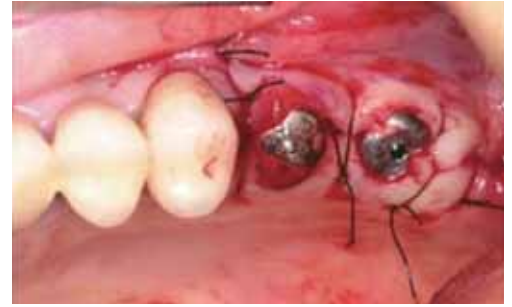

Fig.10 Healing abutments were connected, and simple interrupted suture was used for primary wound closure.

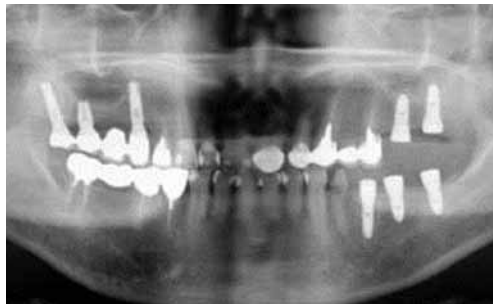


Fig.11 Postsurgical panoramic radiograph. Adequately positioned implants and 3-5mm high dome-shaped grafted bone around the implant apices are seen.

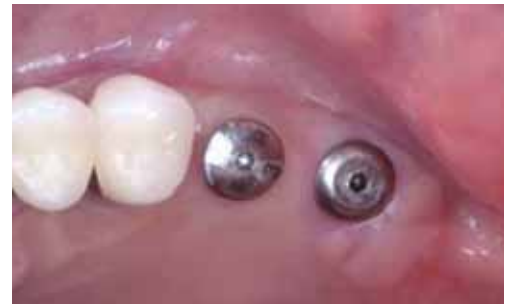

Fig.12 Three months post-op: Adequate amount of attached gingiva is present around the healing abutment. An impression was made at that time.

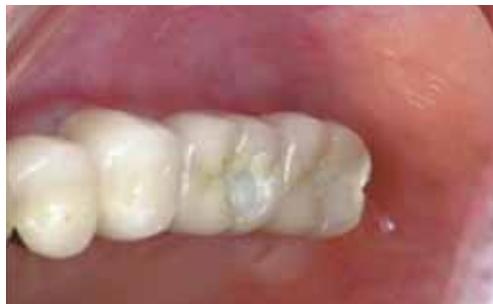

Fig.13 SCRP type prosthesis. Occlusal adjustment and polishing were done after the access hole was filled with composite resin.

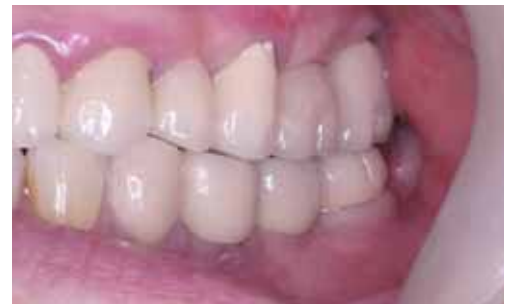

Fig.14 A buccal view of a definitive 2 unit PFM prosthesis (SCRP) in maximum intercuspation.

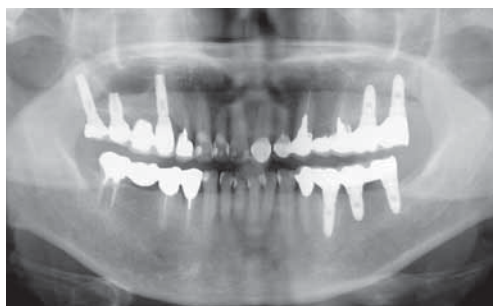

Fig.15 Panoramic view after the delivery of the definitive prosthesis. Graft material around the implants was well maintained.

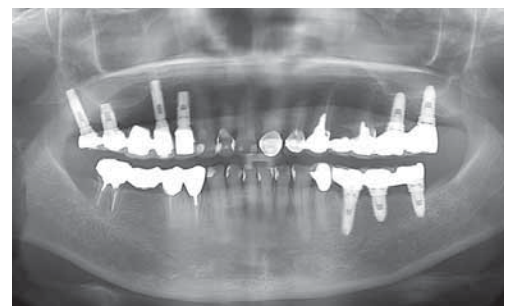


Fig.16 Panoramic view (8 year follow-up). Pneumatization of the new inferior border of the sinus is clearly visible at this time. Marginal bone resorption was observed at the distal area of #27 implant.

4 years follow-up of a clinical case of sinus graft done by SCA and SLA kit

Jongyub Kim
DDS, MS, Ph.D



QR Code by Case

Patient Information

A 52-year-old.

Treatment Plan

Implants placement on #14, #15, #16 & #26 following bilateral sinus augmentation.

Tools that used in surgery

IS-II Active, Neo Surgical Kit, SLA Kit, SCA Kit, Ti-mesh, GBR Kit

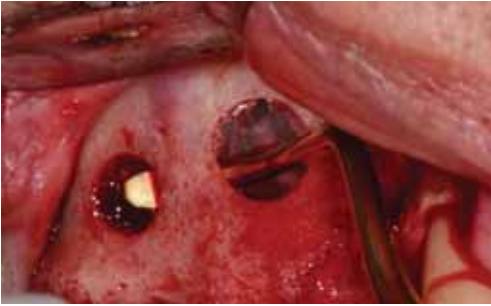

Fig.1 Two small lateral hole was made using the LS reamer in the SLA kit.



Fig.2 A combination of Calpore and Allograft was used for the sinus graft.

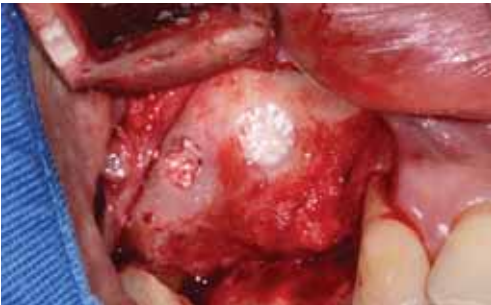

Fig.3 Sinus was filled with bone grafting material.

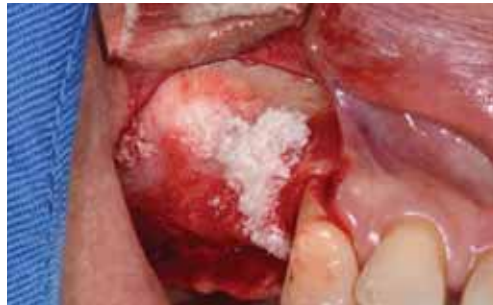

Fig.4 Additional bone graft was made to the defect on a premolar site.

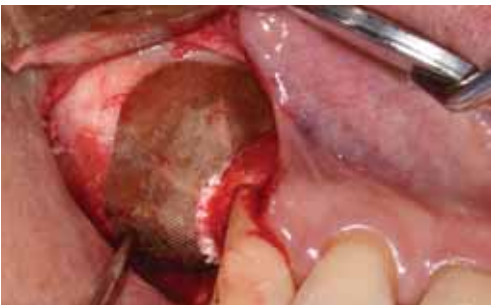

Fig.5 A titanium mesh was placed over the graft.

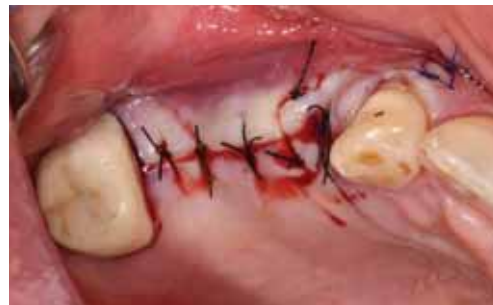

Fig.6 The wound closure was achieved with a combination of horizontal and interrupted suture.

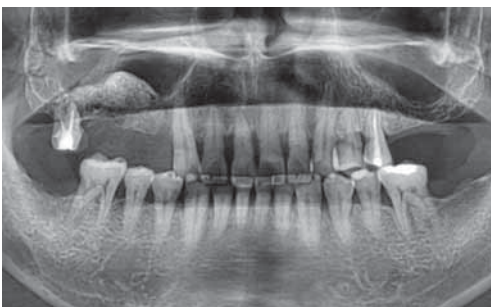

Fig.7 Postoperative panoramic view.

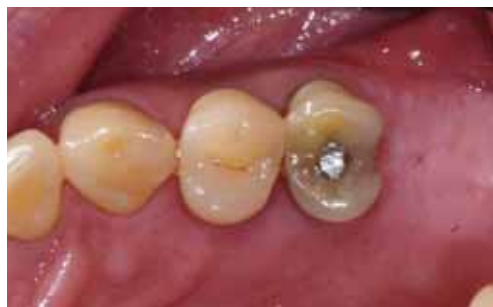

Fig.8 Preoperative clinical view of the maxillary left posterior area.

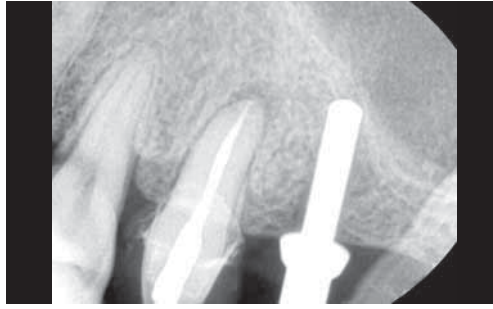


Fig.9 The left sinus was augmented by the crestal approach.

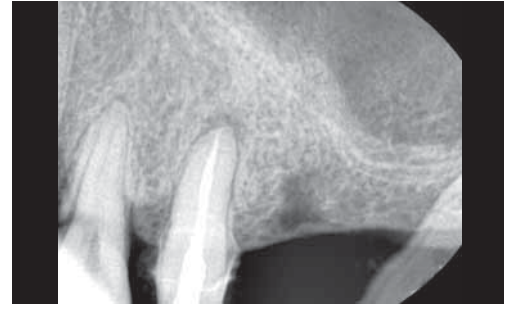

Fig.10 The sinus was grafted by the crestal approach using the SCA kit.

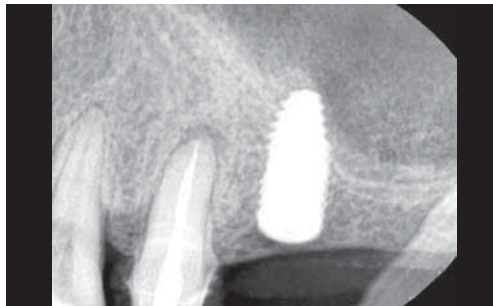


Fig.11 CMI IS II active implant was placed in the grafted maxilla.

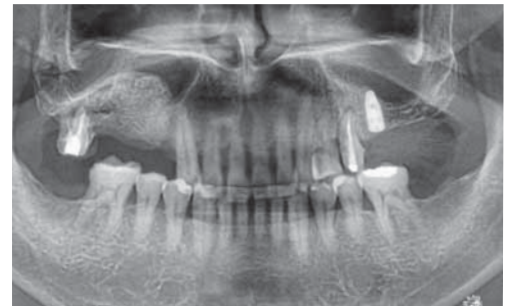

Fig.12 Panoramic radiograph taken after the surgery.

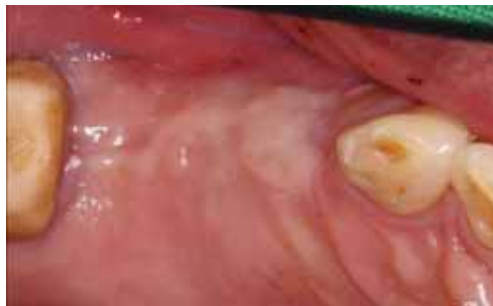

Fig.13 5 months postoperative clinical view. No membrane exposure was found.

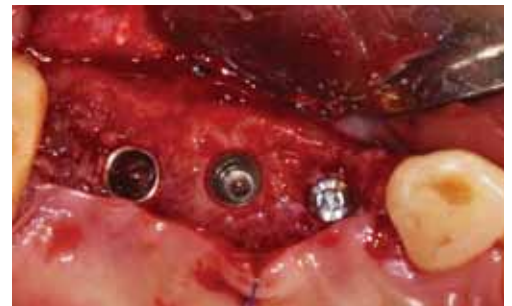

Fig.14 3 implants were successfully placed due to good bone formation made on the buccal side.

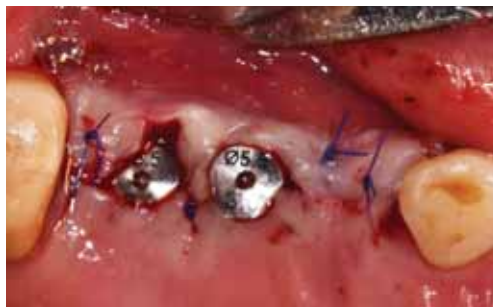

Fig.15 Submerged for #14; non submerged for #15 and #16.

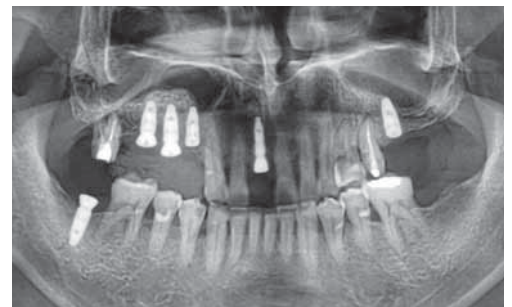

Fig.16 Postoperative radiographic view.

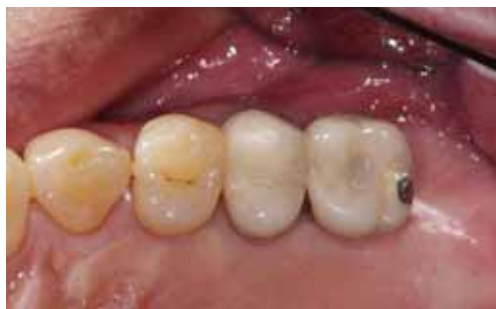

Fig.17 Final single SCRP crown on #26.

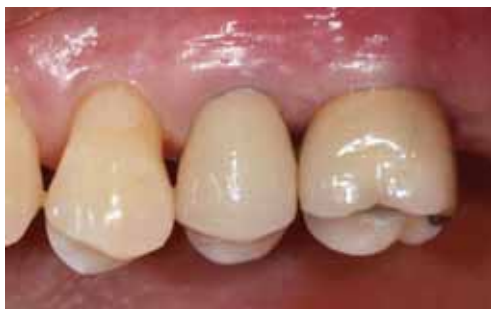

Fig.18 Buccal view.

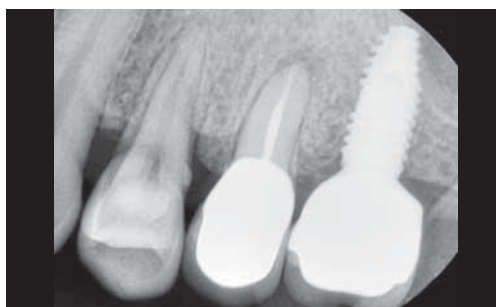

Fig.19 Periapical radiographic view.

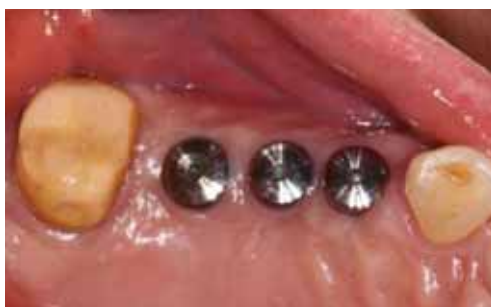

Fig.20 Soft tissue has healed 4 months after the surgery.

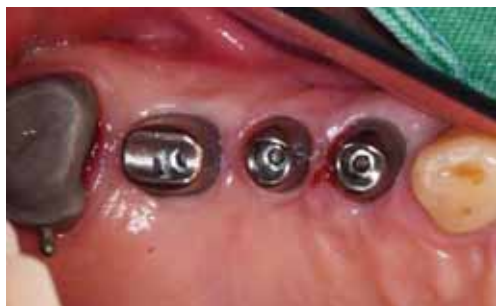

Fig.21 Customized abutments were tried in.

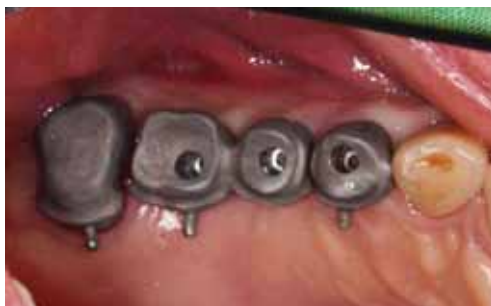

Fig.22 SCRP single crown on #14 and SCRP two unit PFM FPD on #15 and #16 were tried in.

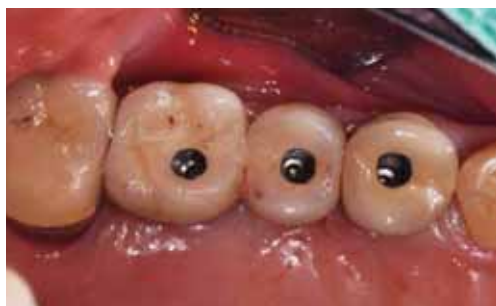

Fig.23 SCRP single crown on #14 and SCRP two unit PFM FPD were delivered.

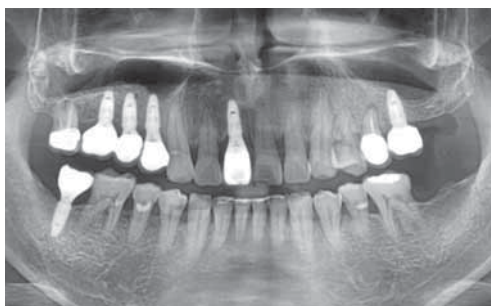

Fig.24 Postoperative panoramic view.

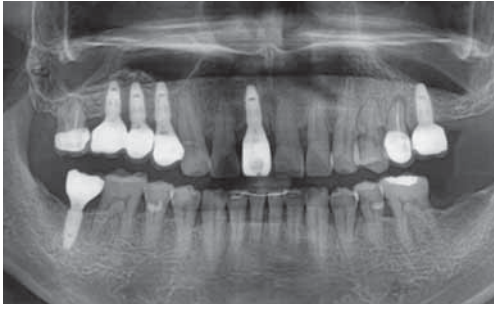


Fig.25 4 years postloading radiograph. All implants are successfully maintained without bone loss.

Ti-Mesh Fixation Case



Dr. Junwoo Lee
DDS



QR Code by Case

Patient Information

A 51-year-old, female.

Treatment Plan

1. Removal of old prosthesis.
2. Performing GBR on #35 and 36 area with mixture of allograft and PRP bone.
3. Implant placement.
4. Final prosthesis.

Tools that used in surgery

Ridge Wider Kit, Ti-Mesh, GBR Kit, Neo Surgical Kit, IS-II active

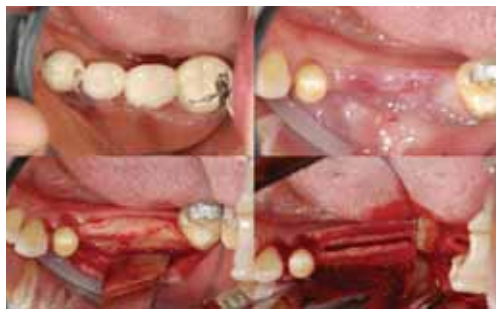

Fig.1 Photo shown on the upper left side is the pre-operative intra-oral photograph at the first day of examination. (06/30/2014) The rest of the intra-oral photographs were taken on the day of surgery. (10/13/2014)

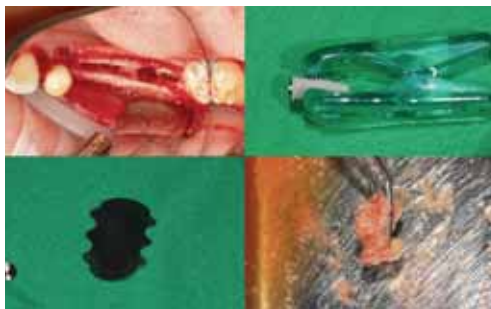


Fig.2 As extremely narrow ridge was found on the mandibular left, ridge split was performed. In such case, the site was fixed with the Ti-Mesh and GBR was applied by inserting mixed bone (mixture of allograft bone and PRP bone) to fill the split gap space.

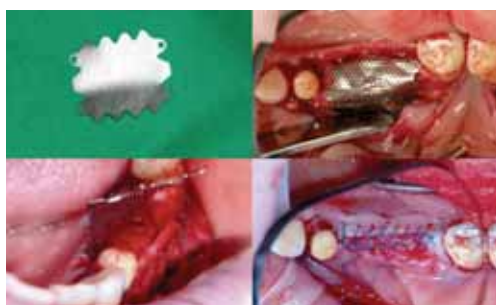

Fig.3 As shown on the lower left photo, the ridge has widened quite a bit after the ridge split and GBR. The Ti-Mesh was fixed with bone screws, and periodontal releasing incision was performed. Flap was sutured with primary closure. (10/13/2014)

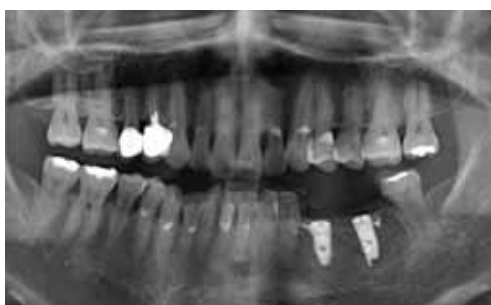


Fig.4 Post-op panorama after implant placement.

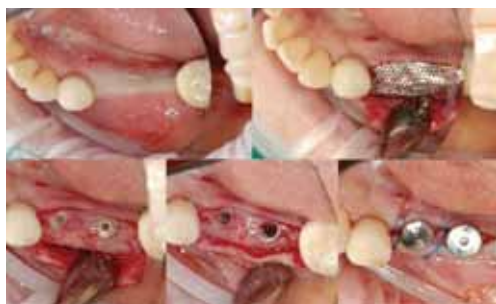

Fig.5 Second surgery. (02/25/2015) The epithelium has become thinner due to Ti-Mesh's good ability of space keeping. When the surface layer of the epithelium was opened, the Ti-Mesh remained well fixed. Complete bone regeneration was observed following the removal of the Ti-Mesh. New bone was created widely on the sides of the placed implants.

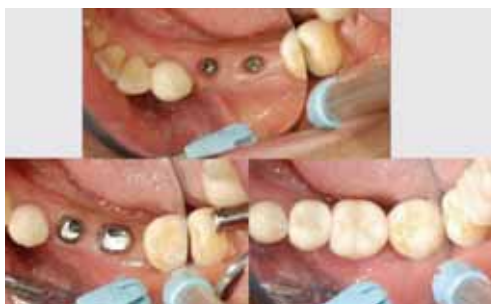

Fig.6 Good soft tissue healing was seen after second surgery. Impression of #35 & #36 was taken. (3/16/2015) The three photos were taken while connecting the CAD/CAM Abutment and delivering the temp cr. (04/15/2015)

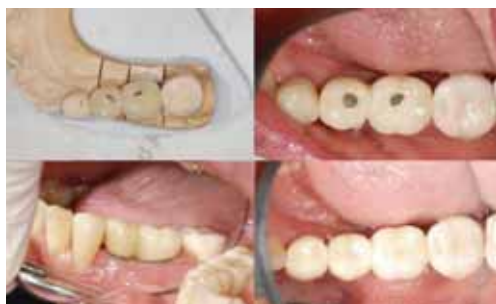

Fig.7 Clinical view of left mandibular after delivery of final restoration. (06/26/2015)

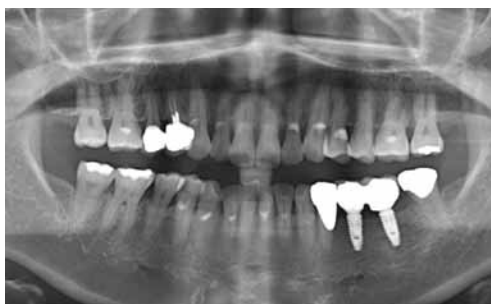

Fig.8 Panoramic view after delivery of final restorations.

Immediate Placement and Immediate Loading in the maxillary central incisor



Dr. Young-Ku Heo
DDS, MSD, Ph.D



QR Code by Case

Patient information

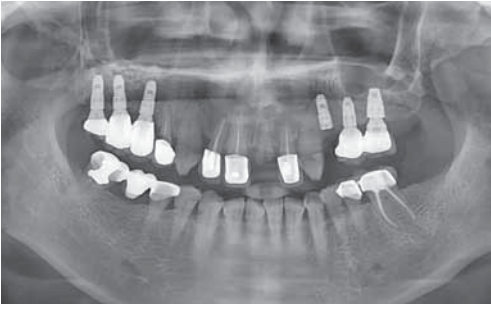54 years old / Female.

Treatment Plan

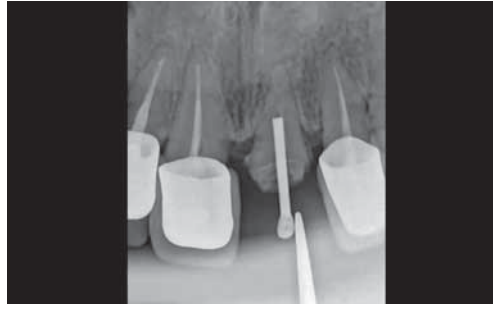
1. Immediate placement on #21 with IS-III active implant.
2. Bone grafting if needed.
3. Delivery of final prosthesis. (Single SCRIP crown)

Tools that used in surgery

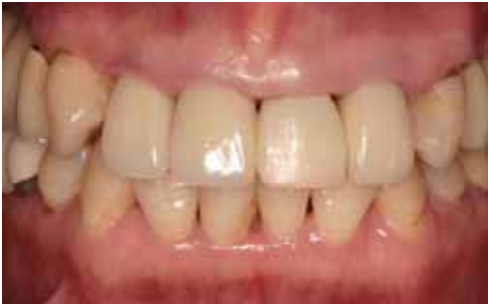IS-III active, Neo Surgical Kit



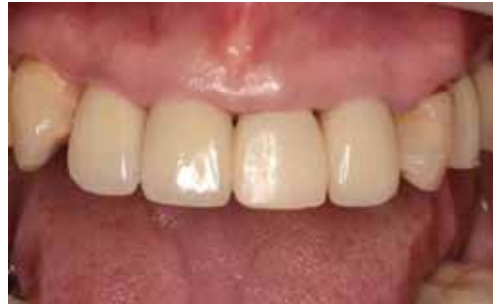| Fig.1 Pre-op panorama.



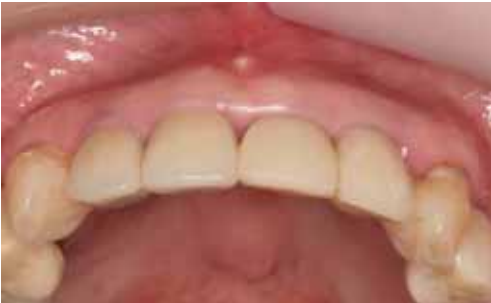| Fig.2 Pre-op periapical radiograph.



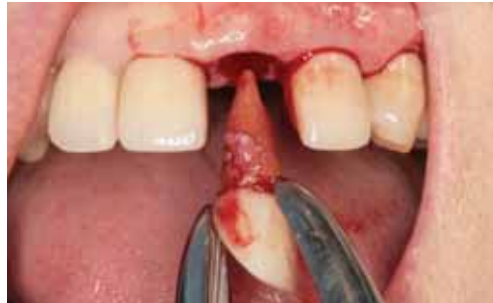| Fig.3 Intra-oral photograph.



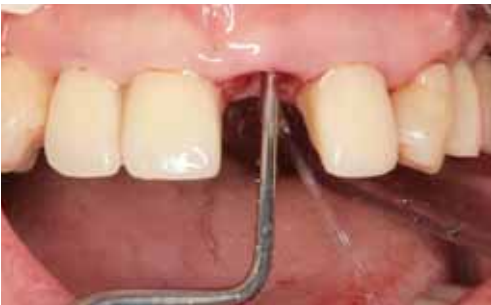| Fig.4 Intra-oral photograph.



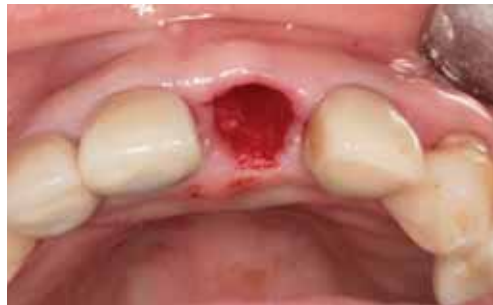| Fig.5 Intra-oral photograph.



| Fig.6 Extraction of #21.



| Fig.7 Curettage and irrigation.



| Fig.8 Immediately after the extraction of #21.

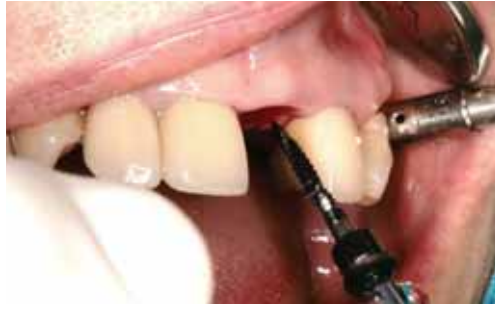

Fig.9 Point drill. (1,200rpm)

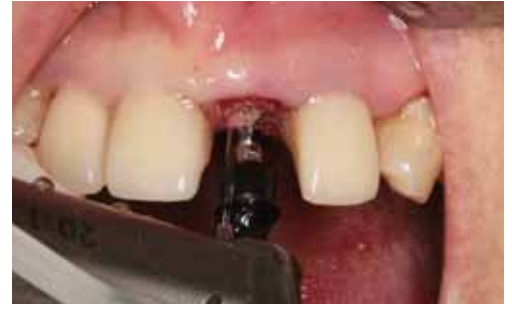

Fig.10 Point drill. (1,200rpm)

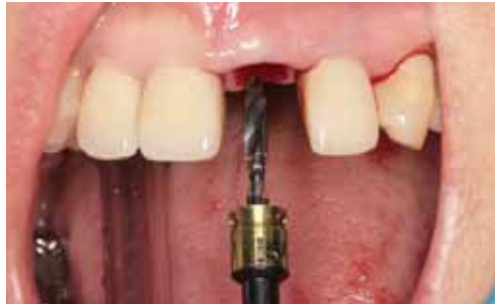

Fig.11 Ø2.2 drill with 10mm stopper > 13mm stopper (1,200rpm) Enough drilling for the implant placement with the appropriate Stopper connected to the drill with irrigation. If you want to place the implant deeply or adjust the depth, it is good to put a one step longer stopper for over-drilling.

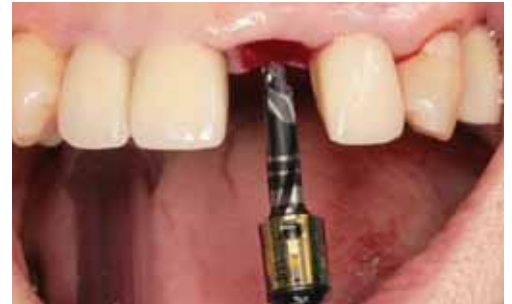

Fig.12 Ø3.0 drill with 13mm stopper. (1,200rpm)

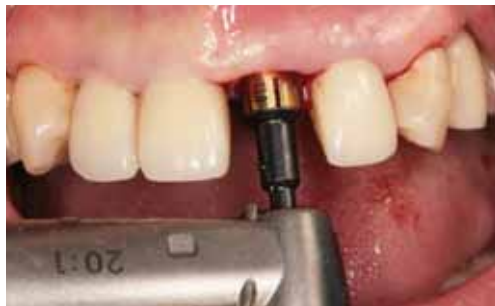

Fig.13 Ø3.5 drill with 13mm stopper. (1,200rpm)

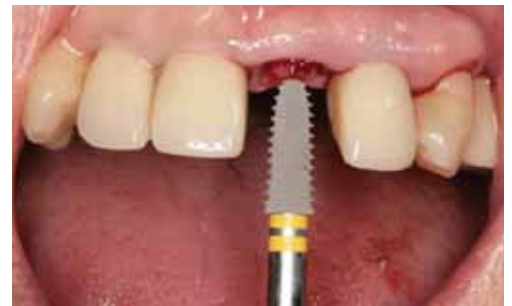

Fig.14 Neobitech IS-III active 4.0x11.5mm fixture.

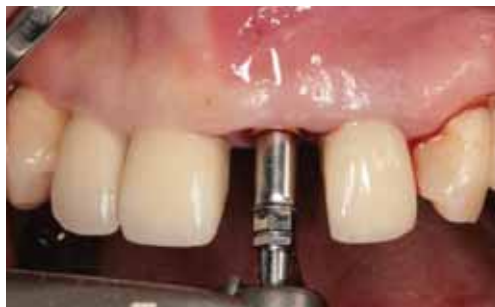

Fig.15 Neobitech IS-III active 4.0x11.5mm fixture was placed in the area of #21.

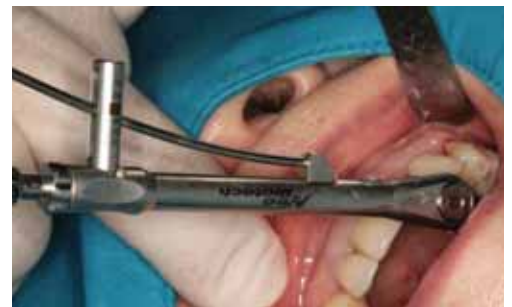

Fig.16 The fixture was finally tightened with the torque ratchet.

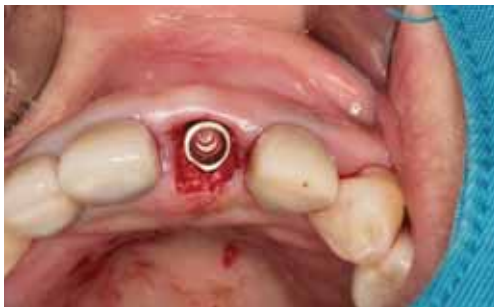

Fig.17 Immediate implant placement.

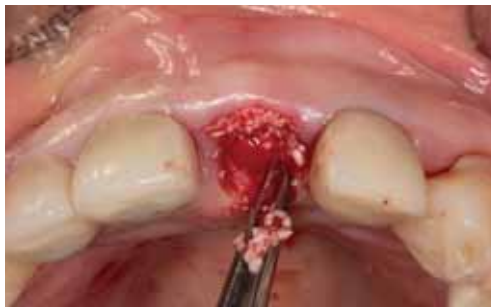

Fig.18 The gab was filled with an allogenic bone. (RegenOss™)

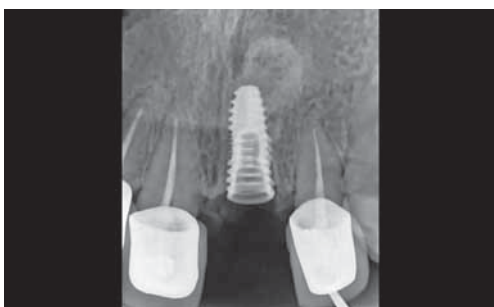

Fig.19 Post-op periapical radiograph.

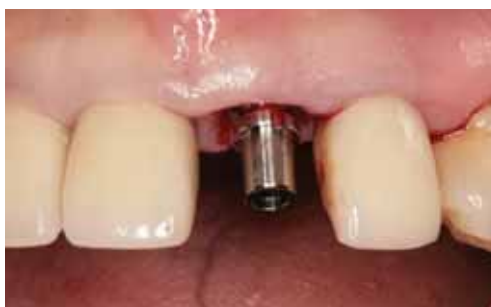

Fig.20 A SCR(Screw-Cement Retained Prosthesis) temporary abutment for IS type was connected.

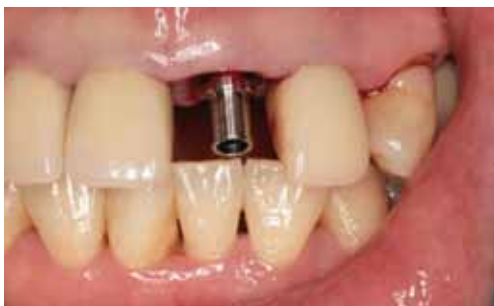

Fig.21 A SCR(Screw-Cement Retained Prosthesis) temporary abutment for IS type was connected.

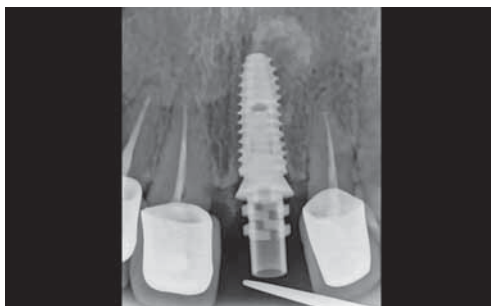

Fig.22 Postoperative radiograph of the implant in place with a provisional abutment.



Fig.23 A provisional crown.

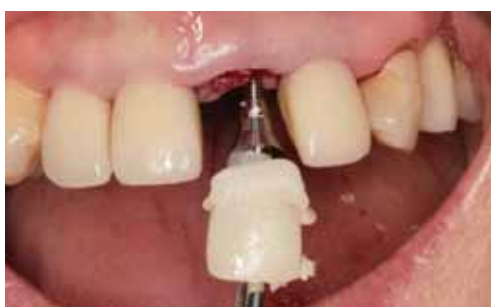

Fig.24 A provisional crown.

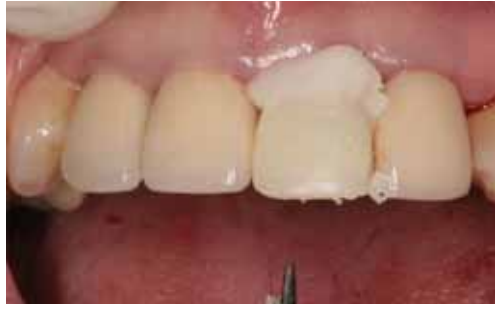

Fig.25 A SCRP provisional crown was delivered.

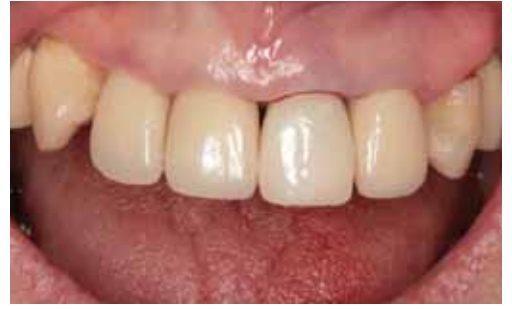

Fig.26 Frontal view of the patient's smile. Temporary restoration provided to the patient on the surgery day reduces the stress caused by the treatment and allows to return to the daily life immediately.

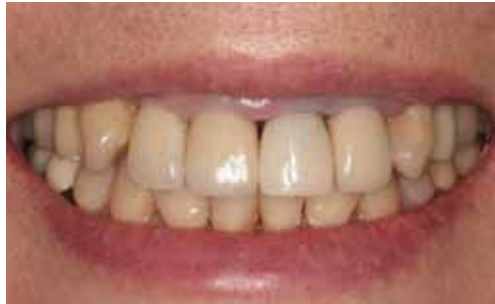

Fig.27 Provisional restoration was immediately delivered on the day of the surgery.

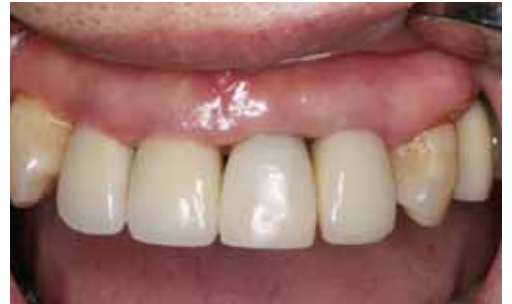

Fig.28 Final prosthesis. (Single SCRP crown)

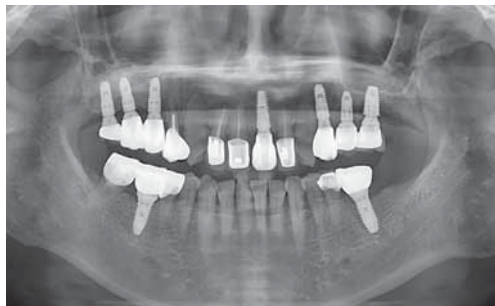

Fig.29 3-year follow-up.

Delayed Implant placement on periodontally compromised single anterior tooth



Dr. Tan Soon Teik
BDS, MFDS RCS, FICCDE



QR Code by Case

Patient Information

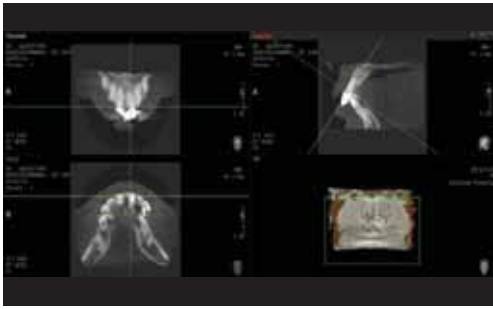
A 55-year-old, female.

Treatment Plan

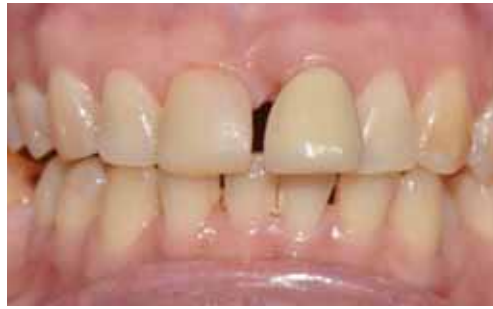1. Extraction with socket preservation to preserve hard tissue.
2. Delayed implant placement with any tissue graft if necessary.
3. Long term provisional crown to remodel and re-establish gingiva zenith, interdental papilla and soft tissue contour.
4. Final prosthesis with customized abutment copying the profile of the established soft tissue support.

Tools that used in surgery

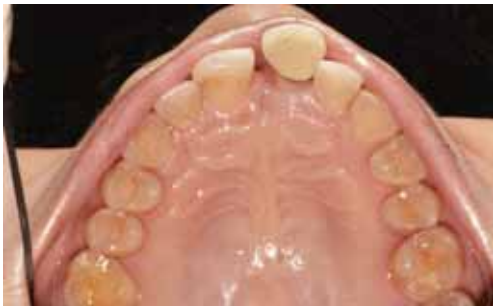Neo Surgical Kit, IS-II active



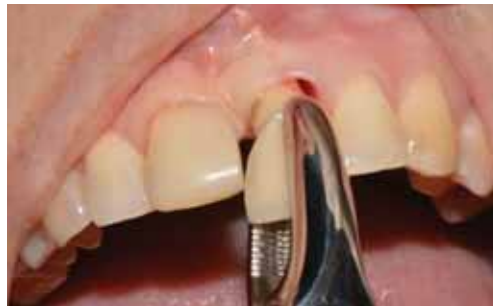| Fig.1



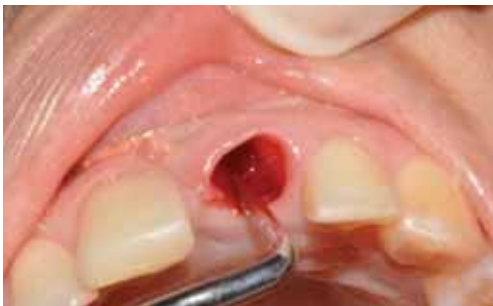| Fig.2 PRE-OPERATIVE.



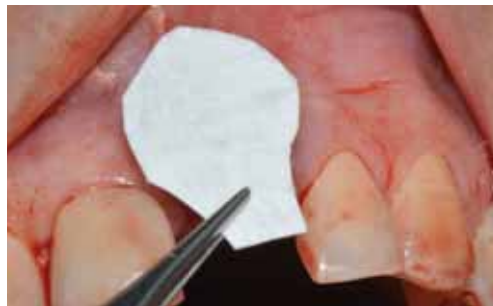
| Fig.3 PRE-OPERATIVE.



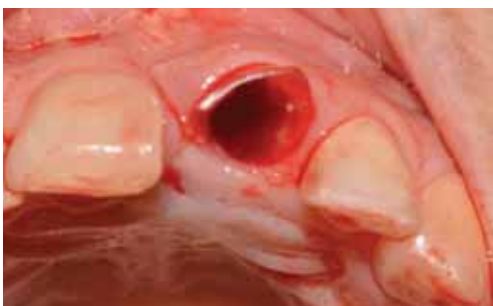| Fig.4 ATRAUMATIC EXTRACTION AND SOCKET CURRATAGE.




| Fig.5



| Fig.6 COLLAGEN MEMBRANE PLACEMENT.



| Fig.7



| Fig.8 PRF PREPARATION.

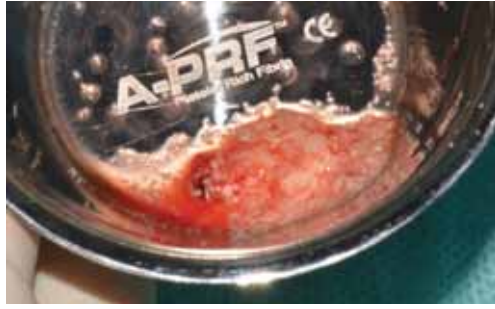


Fig.9

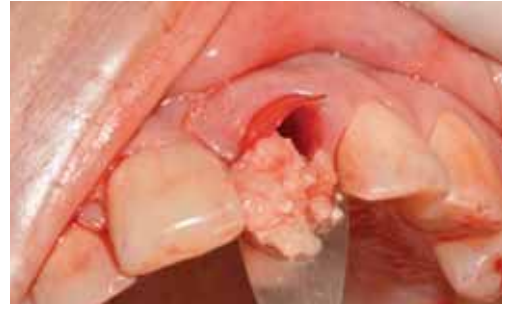

Fig.10 GBR WITH MIXTURE OF ALLOGRAFT AND PRF.

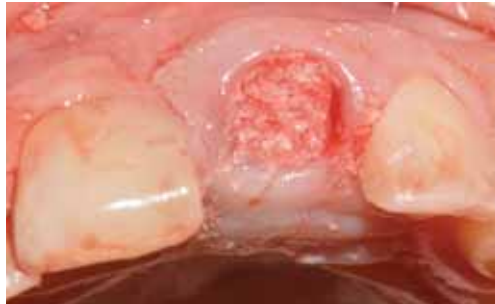

Fig.11

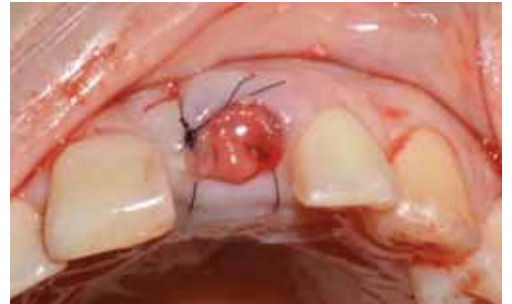

Fig.12 CLOSURE OF SOCKET WITH PRF MEMBRANE.

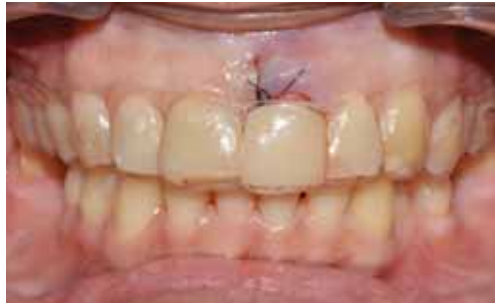

Fig.13

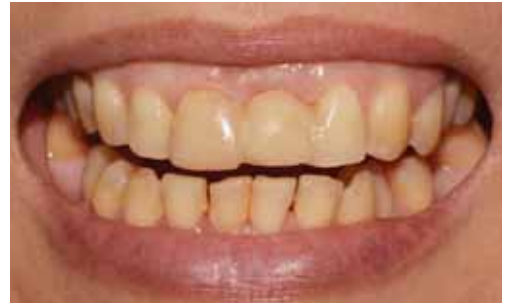

Fig.14 COMPOSITE BONDED BRIDGE AS PROVISIONAL FOR 4 MONTHS.

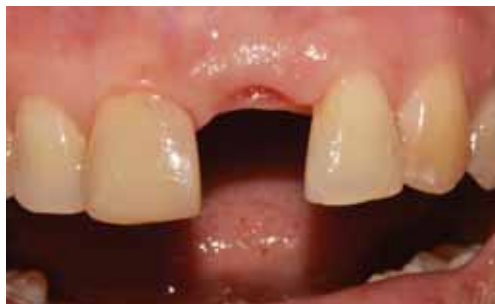

Fig.15 HEALING AFTER 4 MONTHS, GOOD SOFT TISSUE.

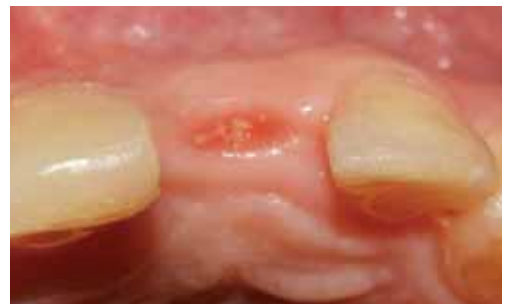

Fig.16

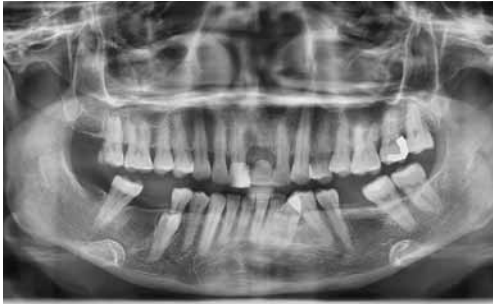

Fig.17 PRE-OP OPG: BONE DENSITY POOR.

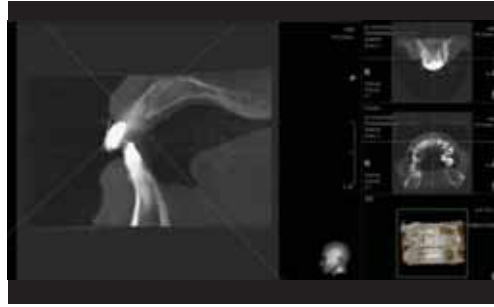


Fig.18 CBCT ASSESSMENT: BONE GRAFT POORLY INTEGRATED.

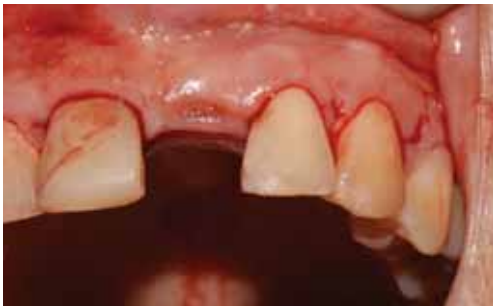

Fig.19 INCISION AND FLAP OPENING.

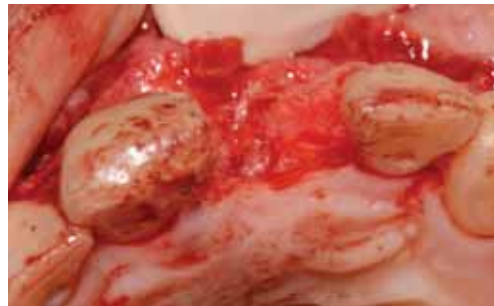


Fig.20

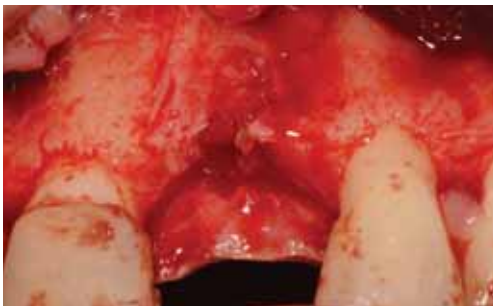

Fig.21 BONE IS SOFT WITH MUCH GRANULATION TISSUE.

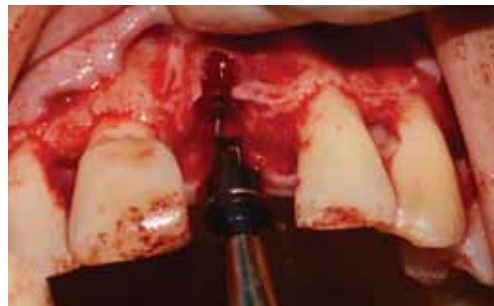

Fig.22

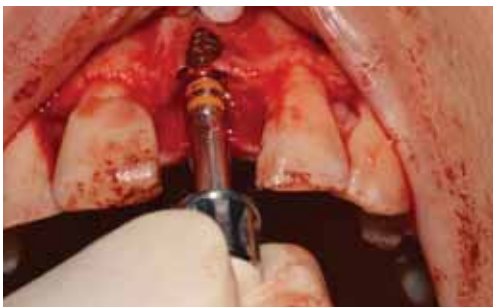

Fig.23 IMPLANT PLACED SLIGHTLY DEEPER FOR HIGHER PRIMARY STABILITY.

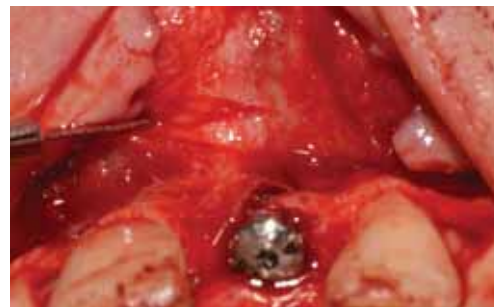
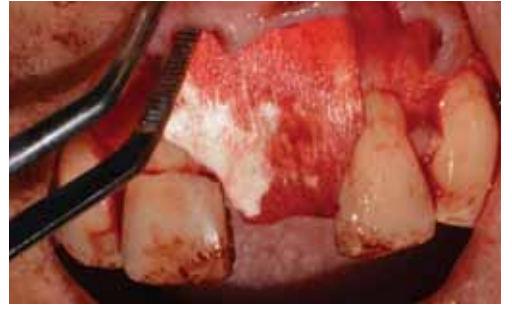

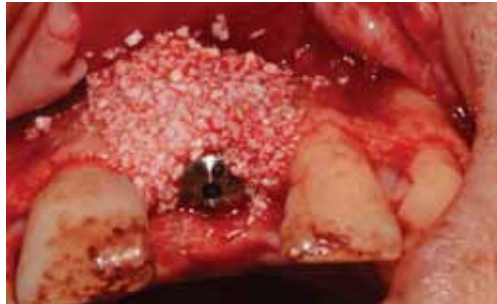Fig.24



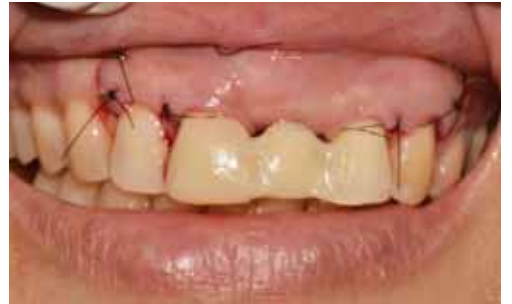| Fig.25 INSERTION TORQUE.



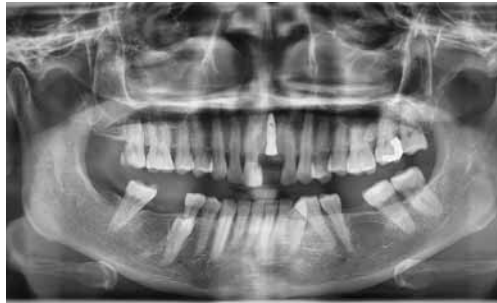| Fig.26 GBR WITH XENOGRAFT.



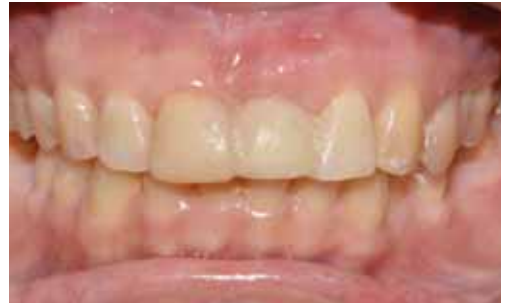| Fig.27



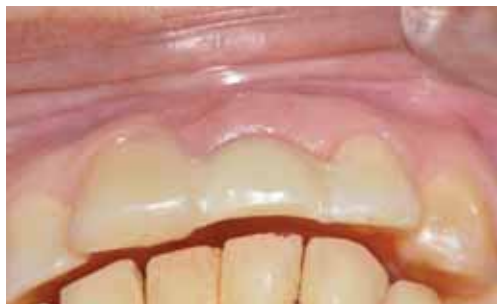| Fig.28 TENSION FREE PRIMARY CLOSURE.



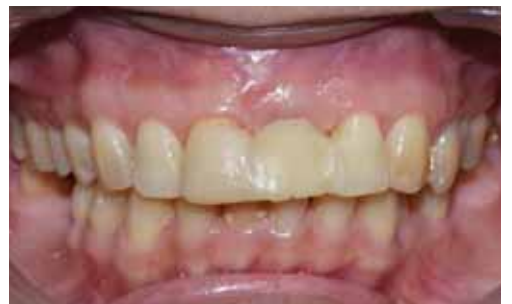| Fig.29 POST-OPERATIVE OPG.



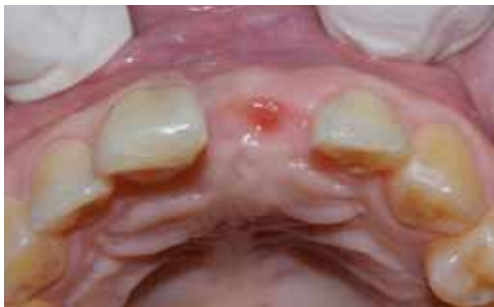| Fig.30 1 MONTH HEALING.



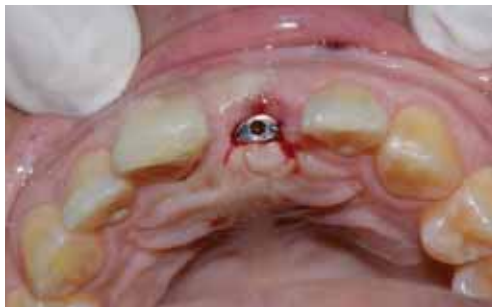| Fig.31



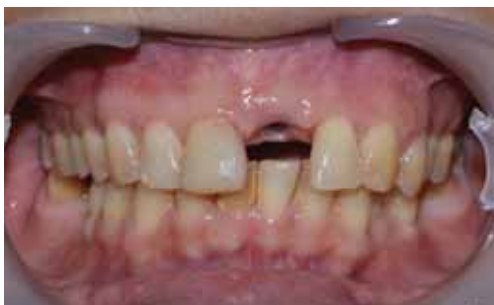| Fig.32 4 MONTHS HEALING.



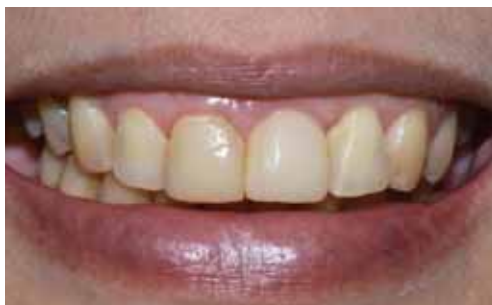| Fig.33



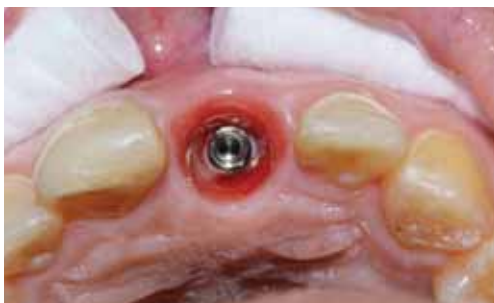| Fig.34 CHANGING HEALING ABUTMENT.



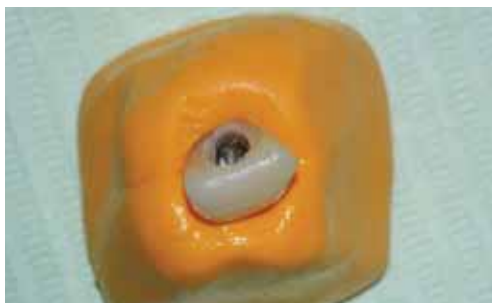| Fig.35



| Fig.36 PROVISIONAL CROWN FOR 4 MONTHS.



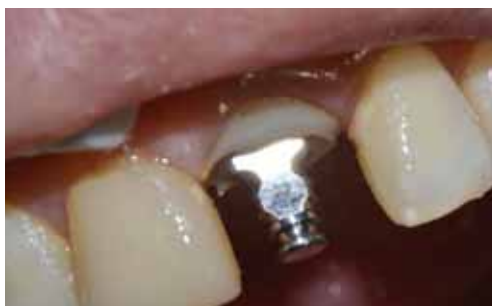| Fig.37



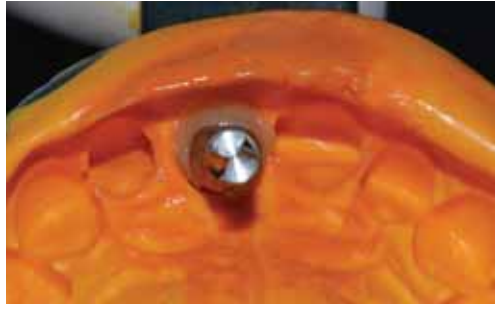| Fig.38 FINAL IMPRESSION.



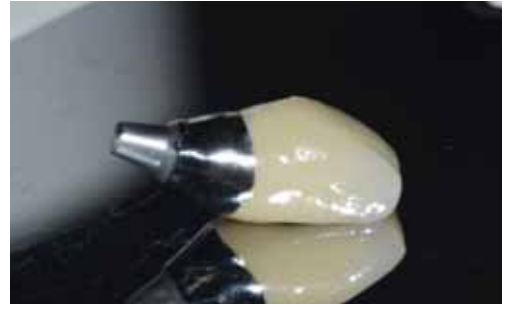| Fig.39



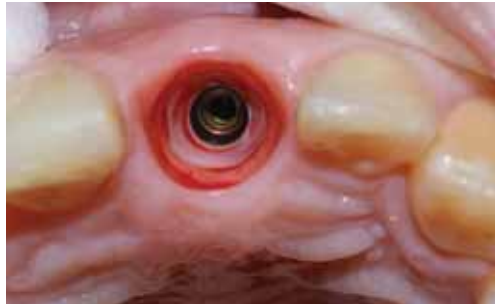| Fig.40 FINAL IMPRESSION.



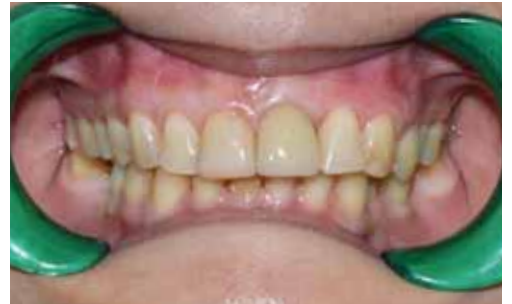| Fig.41



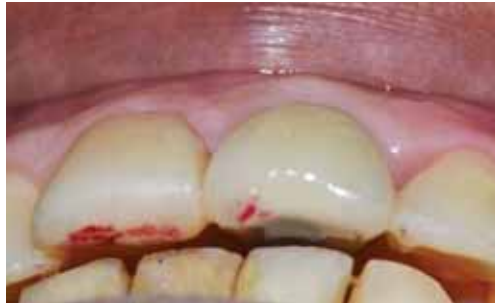| Fig.42 FINAL CUSTOMISED ABUTMENT WITH TITANIUM BASE FOR SOFT TISSUE ADHERENCE.



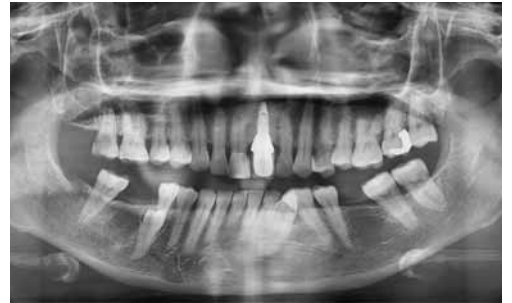| Fig.43



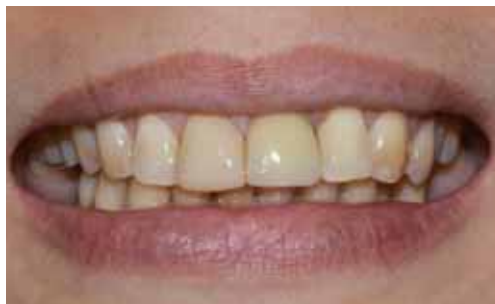| Fig.44 CROWN IN PLACE.



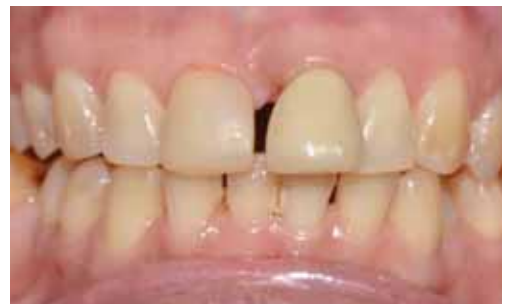| Fig.45



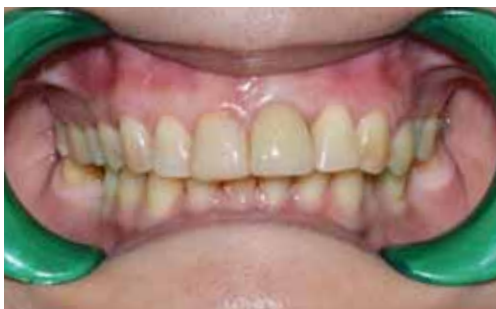| Fig.46 FINAL OPG.



| Fig.47 FINAL SMILE.



| Fig.48 BEFORE.



| Fig.49 BEFORE.

Implant placement with IS-III active fixtures in the posterior mandible



Dr. Young-Ku Heo
DDS, MSD, Ph.D



QR Code by Case

Patient information

A 55-year-old, male.

Treatment Plan

1. IS-III active implant installation was planned.
2. Prosthesis : 3-unit zirconia SCRPFDPs on implants #45, #46 & #47.

Tools that used in surgery

IS-III active, Pick-cap Impression coping, Neo Surgical Kit

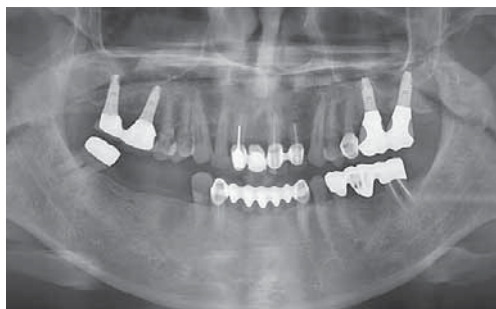

Fig.1

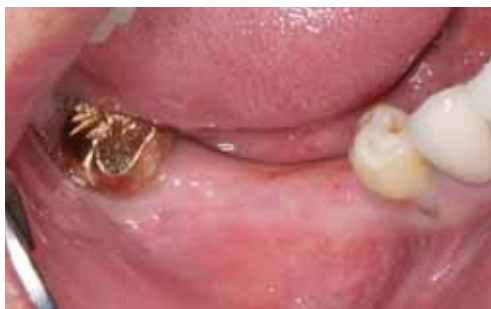

Fig.2 Intra-oral photograph.

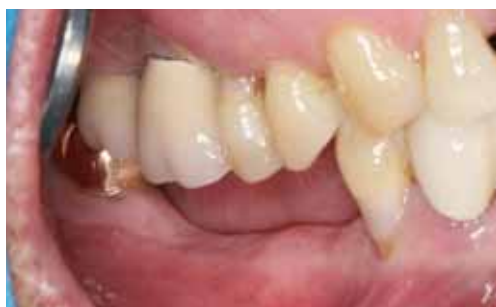

Fig.3 Intra-oral photograph.

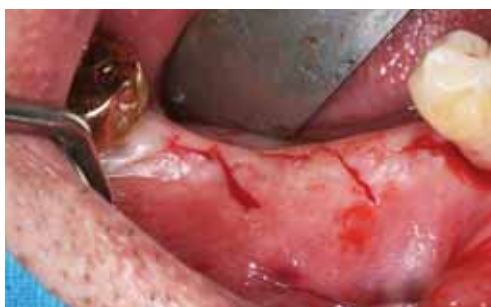

Fig.4 Multiple oblique incision was performed to safe attached gingiva and minimally invasive surgery. This method helps patient's wounds heal much faster.

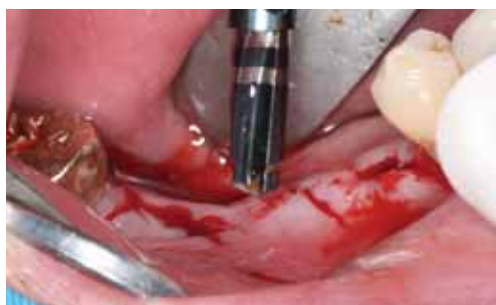

Fig.5 Enough drilling for the implant placement with the appropriate Stopper connected to the drill with irrigation. (Recommended speed : 1,200rpm)

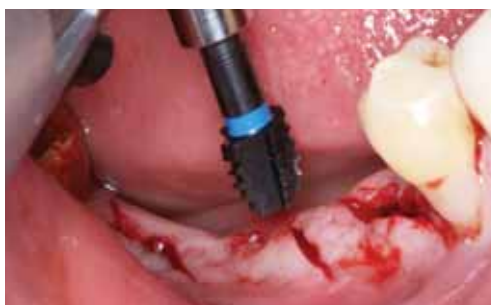

Fig.6 Tapping with irrigation.

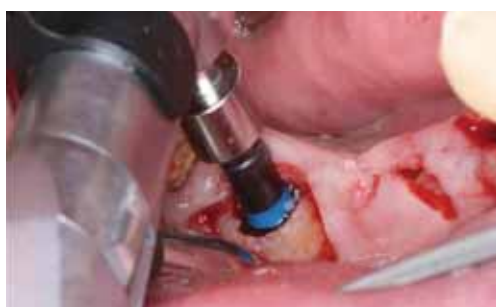

Fig.7 Recommended speed when using the Cortical tap : 50rpm.

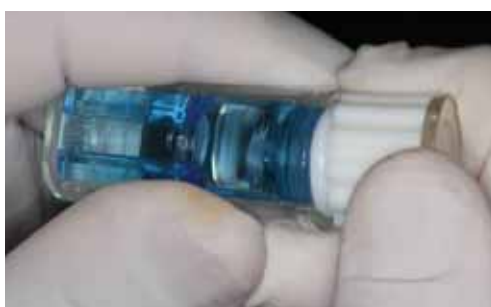

Fig.8 Open the sterilized package after checking the type, size and expiration date of implant specified on the label and packaging status.

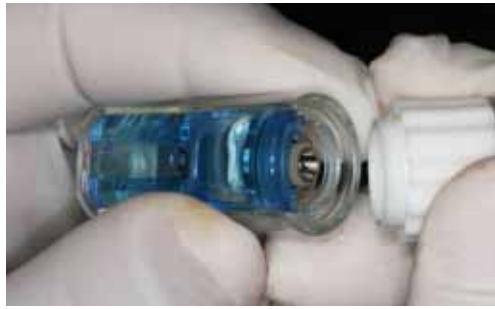


Fig.9

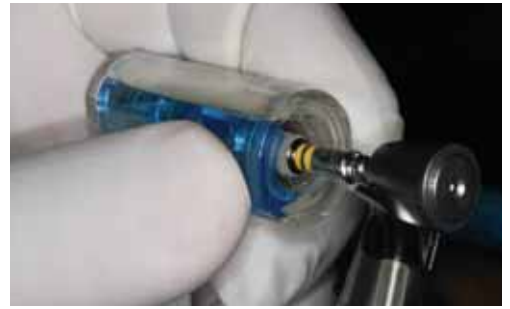

Fig.10 Connect the Fixture Driver mounted on the Hand Piece or Torque Ratchet to the implant in a straight line.



Fig.11 Be careful to prevent contamination of implants from metal or saliva.

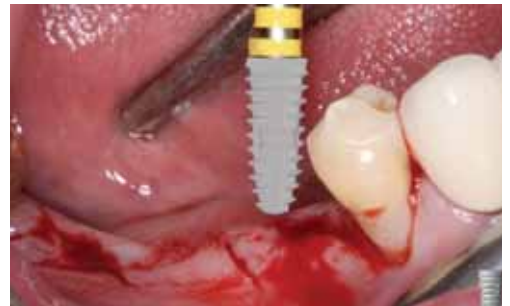

Fig.12 Fully insert the implant inside the bone with the torque value of 35-45Ncm by placing the implant in the pre-drilled hole and rotate the Hand Piece with 25-35rpm. Make sure not to exceed 50Ncm when placing an implant.

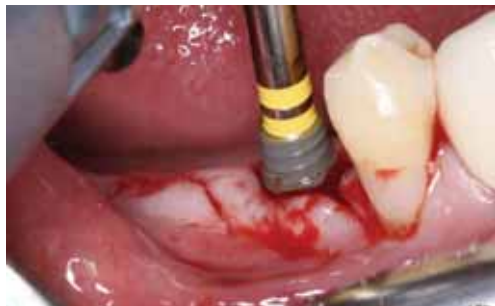

Fig.13 CMI IS-III active 4.0*10mm (Neobiotech, Korea) fixture was placed in the area of #45.

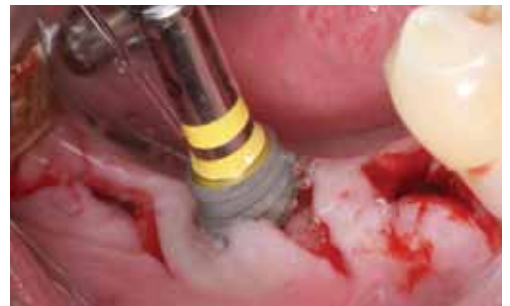

Fig.14 CMI IS-III active 5.0*10mm (Neobiotech, Korea) fixtures were placed in the area of #46 and 47.

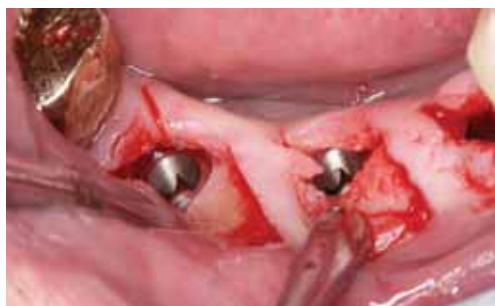

Fig.15 3 implants were placed successfully.

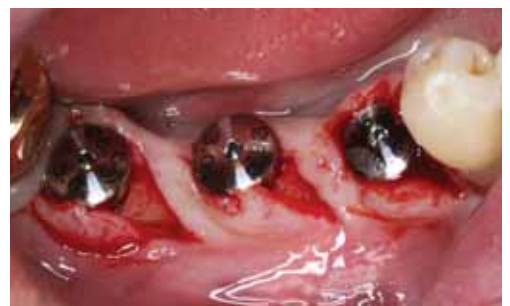

Fig.16 Healing abutments were connected to the fixtures.

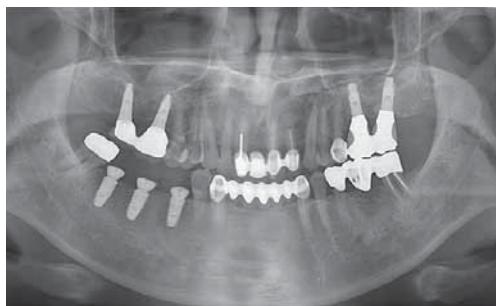

Fig.17 Postoperative panoramic radiograph showing 3 implants placed in the mandibular right posterior area.

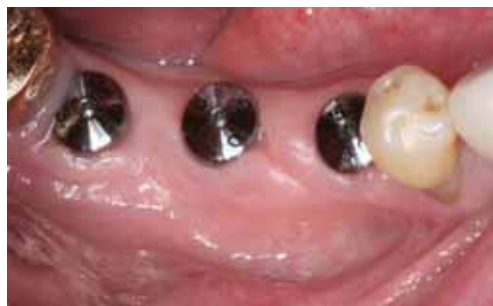

Fig.18 4 weeks after the surgery.

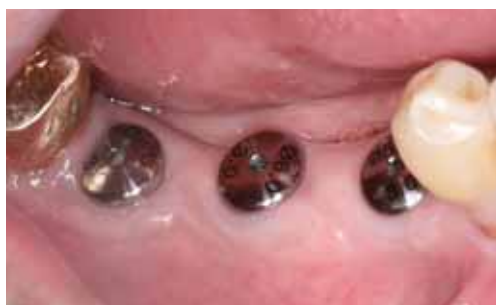

Fig.19 3 months after implant placement surgery. Good soft tissue healing was seen. Impression was made at this time.

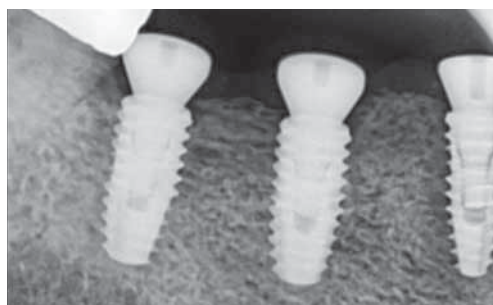

Fig.20 A periapical radiograph after 3 months healing.

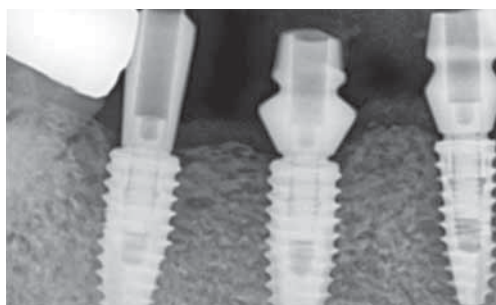


Fig.21 Pick Cap impression copings (Neobiotech, Korea) were connected to the implants for making impression for prosthesis fabrication.

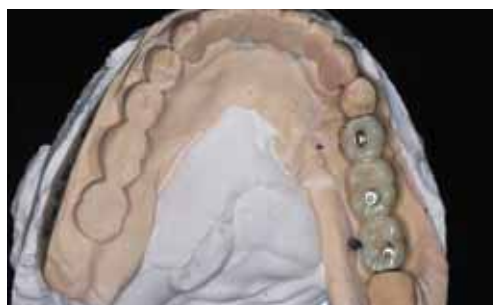

Fig.22 A definitive 3-unit zirconia SCRPFD were fabricated.

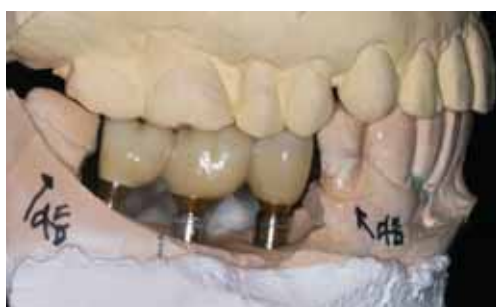

Fig.23



Fig.24 SCRPF prepared abutments.

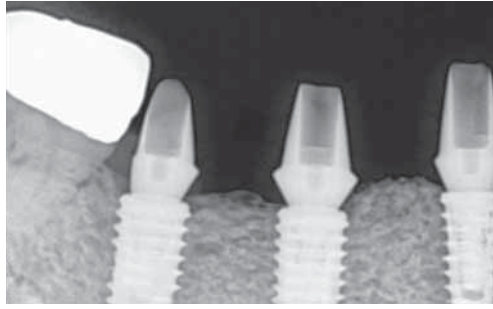


Fig.25 The SCRCP abutments were repositioned.

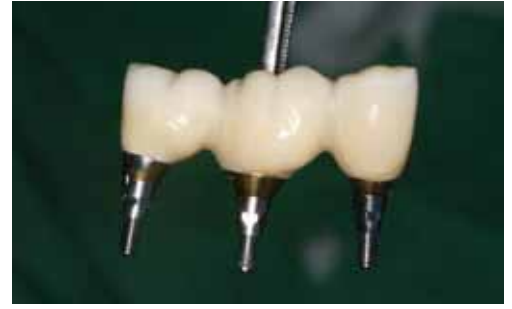

Fig.26 A definitive 3-unit zirconia SCRCP FPD were fabricated on the SCRCP abutments.

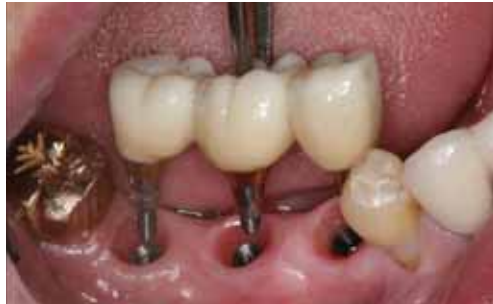

Fig.27 3-unit SCRCP zirconia FPD were cemented with a final resin cement.

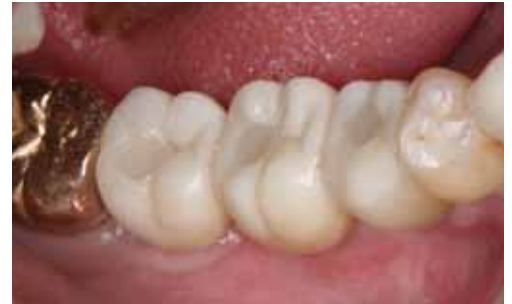

Fig.28 The prosthesis was repositioned and the screw holes were occluded by resin.

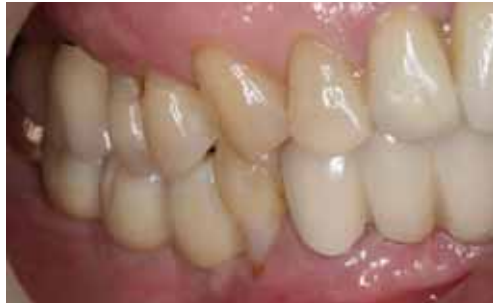

Fig.29 Lateral view of right mandibular after delivery of restorations.

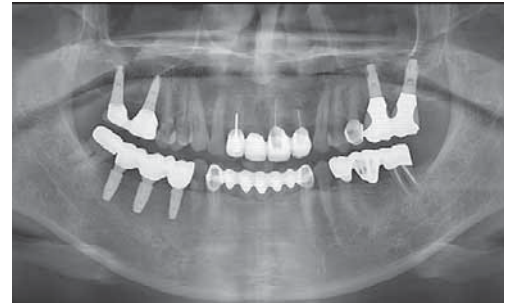

Fig.30 Panoramic view after delivery of the prosthesis.

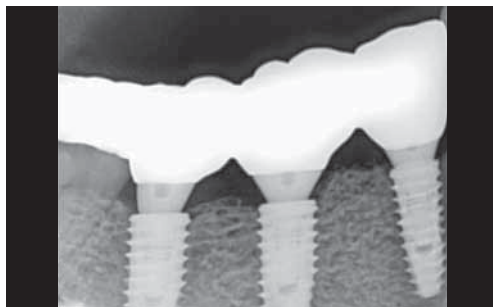


Fig.31 Periapical radiograph after delivery of the final prosthesis.

Maxillary sinus graft with lateral approach and implants placement at right upper molars with LS-reamer in SLA kit

Dr. Nam Yoon Kim
DDS, MDS, Ph.D



QR Code by Case

Patient Information

A 50-year-old, male.

Treatment Plan

1. Minimally invasive sinus floor augmentation via lateral approach (LS reamer in SLA kit Neobiotech Co.) with simultaneously #16, 17 Implant placement. (one staged surgery + less flap operation)
2. Implantation of IS-III active fixture connection with healing abutment for 1 staged surgery.
3. delivery of splinted monolithic full zirconia crown with pre-fabricated SCRP abutments.

Tools that used in surgery

IS-II active, Sinus All Kit

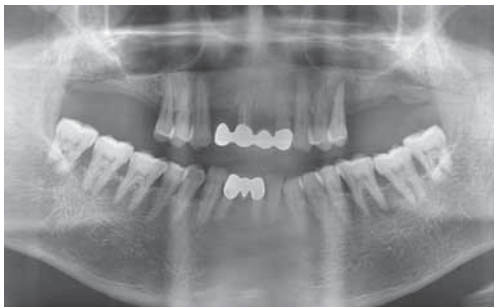

Fig.1 Pre-op panorama: Partial edentulism on maxillary right posterior region. The height of the remaining alveolar ridge at the 1st molar site is 4-6mm.

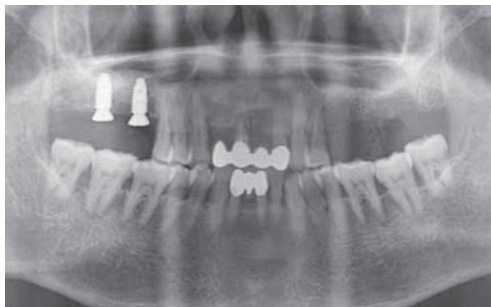

Fig.2 Panoramic x-ray immediately after sinus grafting procedure.

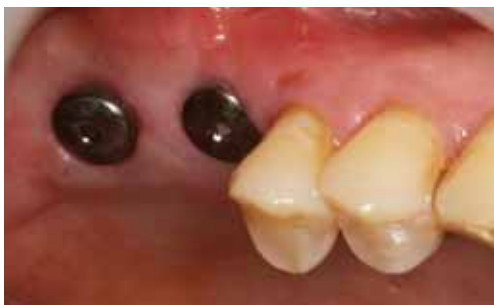

Fig.3 Soft tissue was healed around healing abutment.

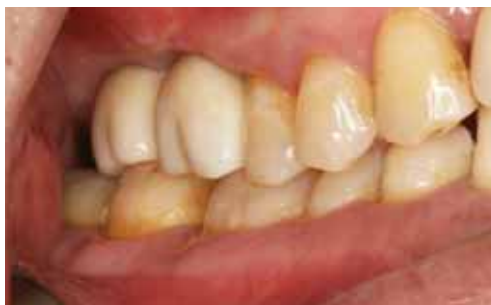

Fig.4 Lateral view : The final prosthesis in occlusion.

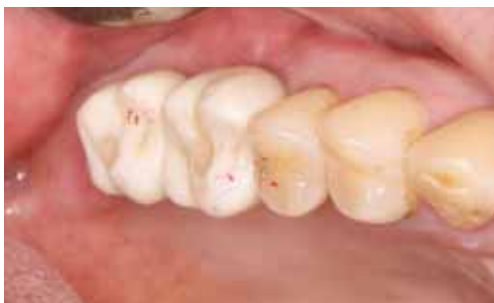

Fig.5 Occlusal view : Access holes were filled with resin.

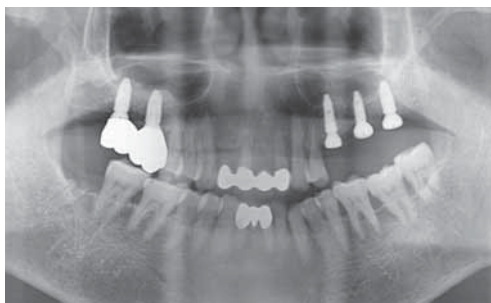

Fig.6 The final prosthesis on maxillary right posterior region was delivered.

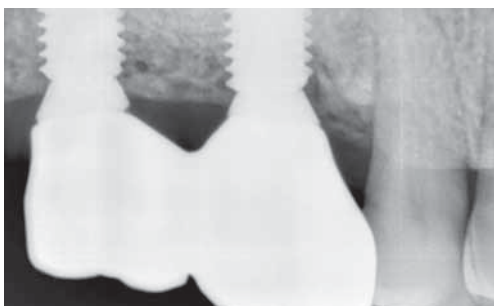


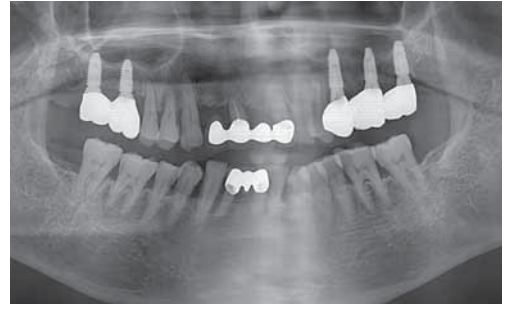
Fig.7 Periapical x-ray of the final prosthesis.

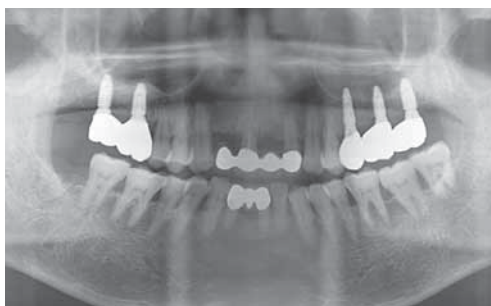
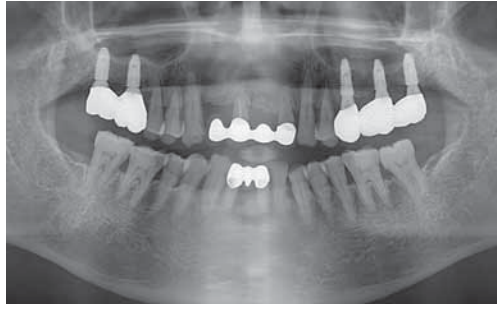
Fig.8 3-year follow-up panorama.



| Fig.9 5-year follow-up panorama.



| Fig.10 6-year follow-up panorama.

GBR with Neobiotech CTi-mem



Dr. Chul-Wan Park
DDS, MSD, CAGS, FICD



QR Code by Case

Patient Information

Case 01. 67 years old / Female.

Case 02. 66 years old / Female.

Treatment Plan

Case 01.

1. Extraction of tooth #44 and implant placement on #44 with GBR.

Case 02.

1. Extraction of #16, 17 and implant placement on #16, 17 with GBR.

Tools that used in surgery

IS-II active, Neo Surgical Kit, CTi-mem, GBR Kit

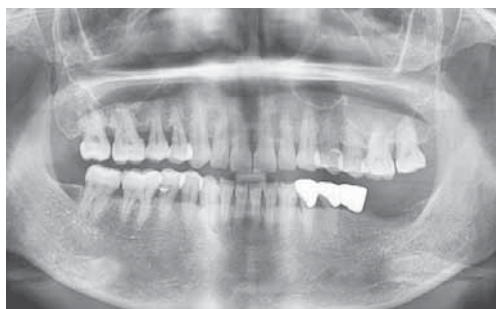

Fig.1 <Case 1> Extraction of # 44 is needed due to severe bone loss.

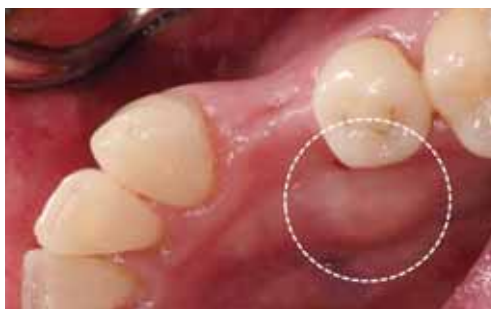

Fig.2 Torus around the surgical site.

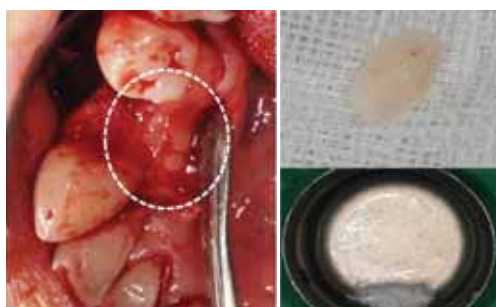


Fig.3 Removed torus was combined with allogenic graft material.

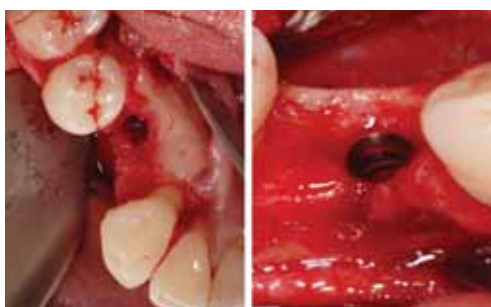

Fig.4 Buccal bone deficiency around IS-II implant. (4.0x10mm)

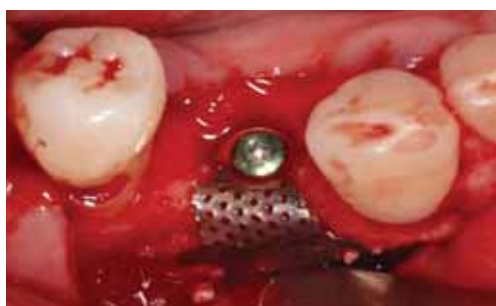

Fig.5 Bone graft material was covered and secured with CTI-mem.

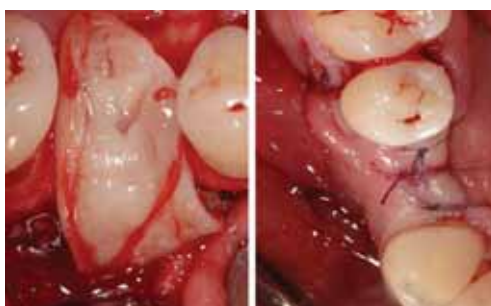


Fig.6 PRF was used to cover the CTI-mem. Tension-free primary closure of flap was achieved.

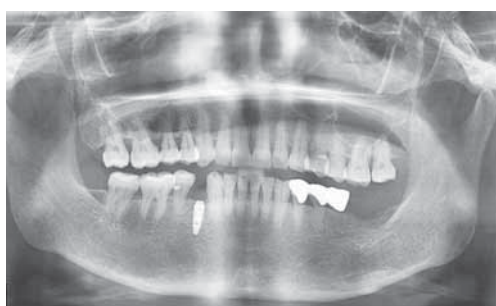

Fig.7 Post-surgical panex view.

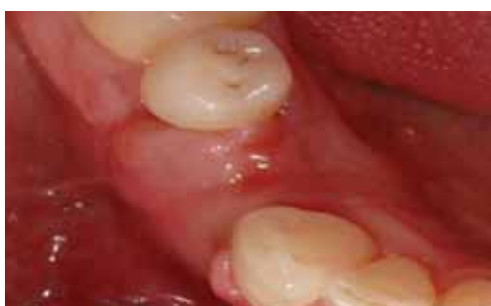

Fig.8 No membrane exposure during 4months of healing period.

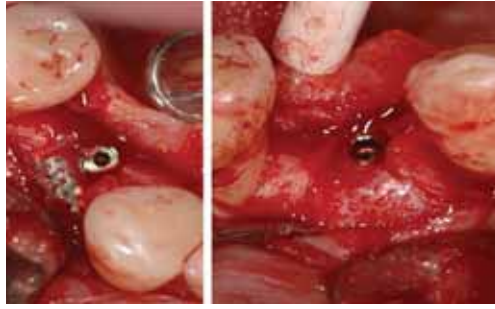


Fig.9 Uncovery and removal of CTi-mem.

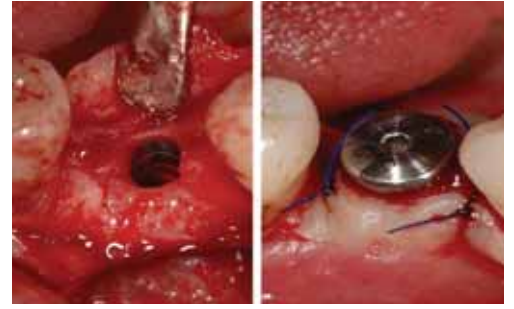


Fig.10 Healing abutment was installed.

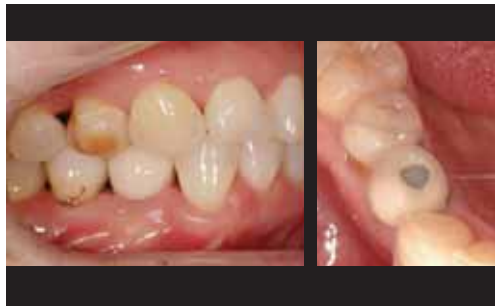

Fig.11 Screw-cement retained implant crown.

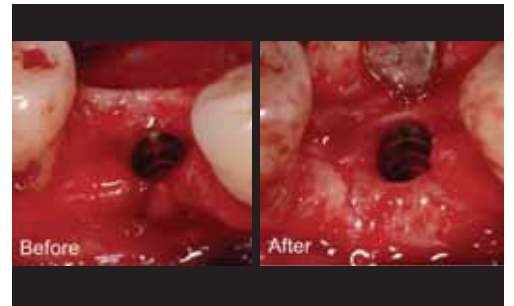

Fig.12 Before and after.

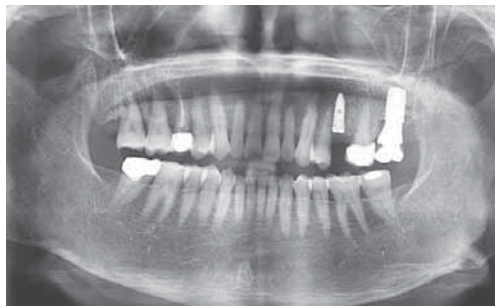

Fig.1 <Case 2> #16 & #17 need to be extracted due to severe bone loss around palatal root.

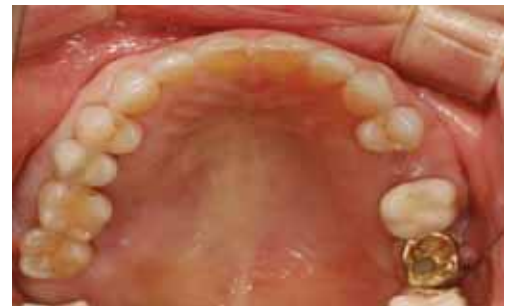

Fig.2 Intraoral view of pre-treatment.

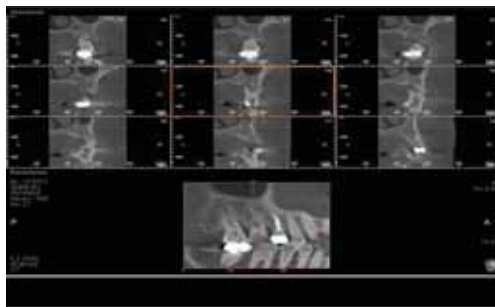


Fig.3 CT view of #16 & #17 shows bone loss around palatal root.

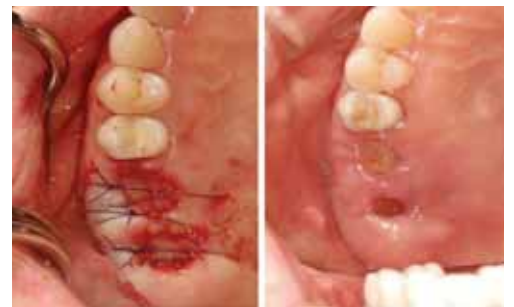

Fig.4 Extraction & socket preservation was performed.

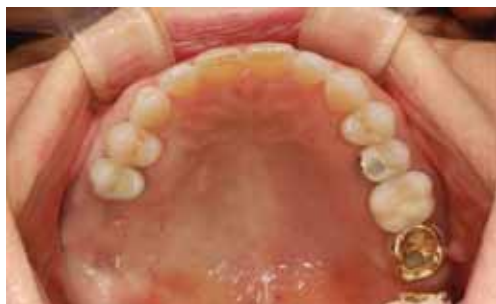

Fig.5 Intraoral view at the time of implant surgery.

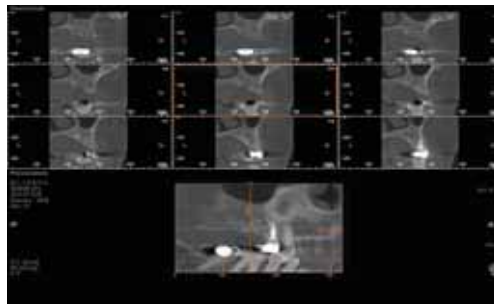


Fig.6 CT shows bone defect on palatal side.

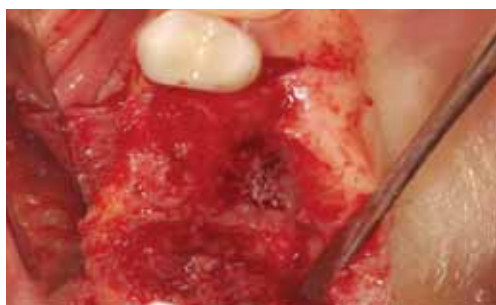

Fig.7

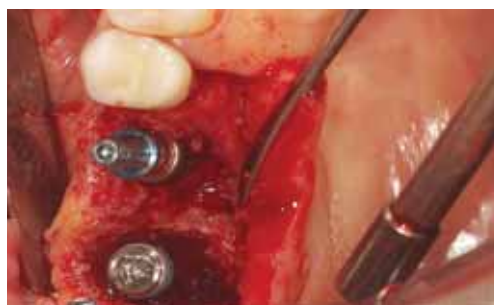

Fig.8 Neobiotech IS-II implants were installed.

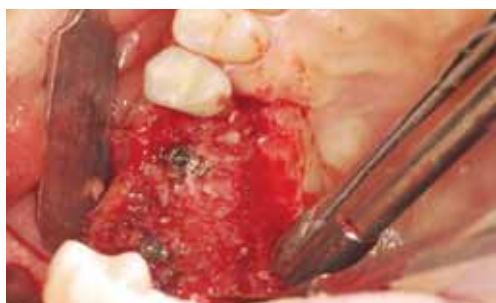

Fig.9 Allogenic bone (ICB cortical, Rocky mountain) was grafted.

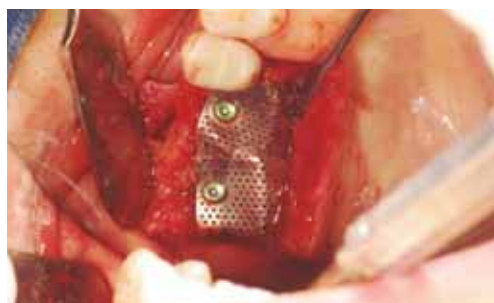


Fig.10 Bone graft material was covered and secured with CTi-mem.

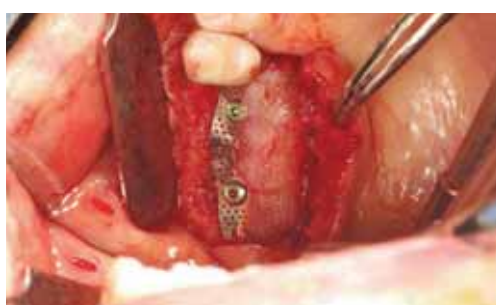

Fig.11 PRF was used to cover the CTi-mem.

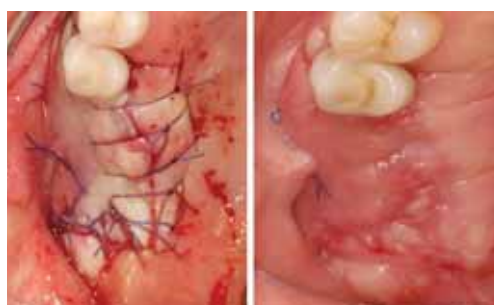

Fig.12 Tension-free primary closure of flap was achieved.

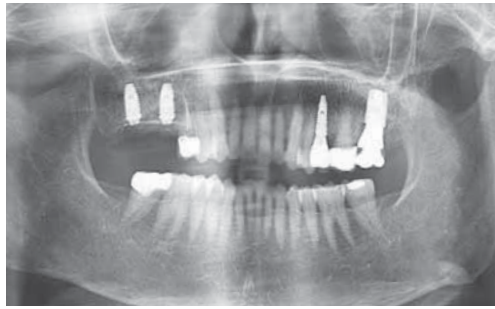

Fig.13 Post-surgical panorax view.

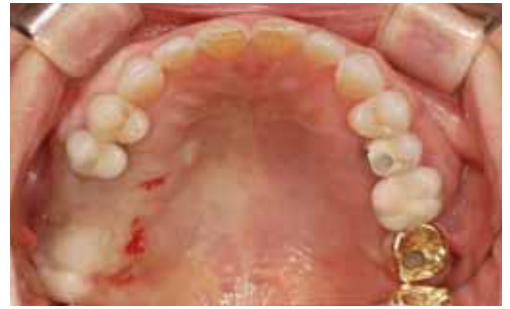

Fig.14 No membrane exposure during 4months of healing period.

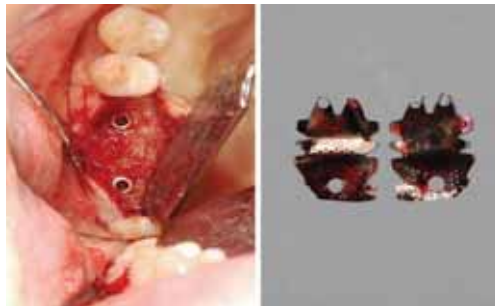

Fig.15 Uncover and removal of CTi-mem.

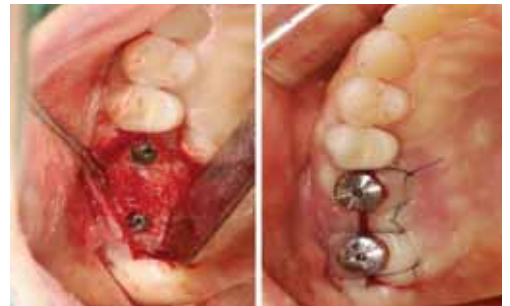

Fig.16 Installation of healing abutments.

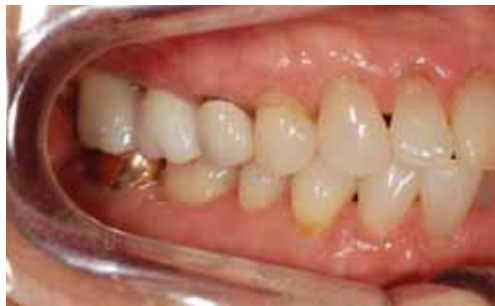

Fig.17

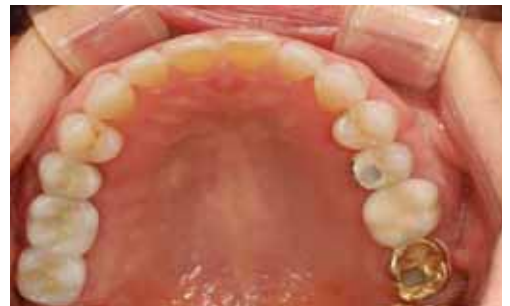

Fig.18 Screw-cement retained splinted implant crowns.

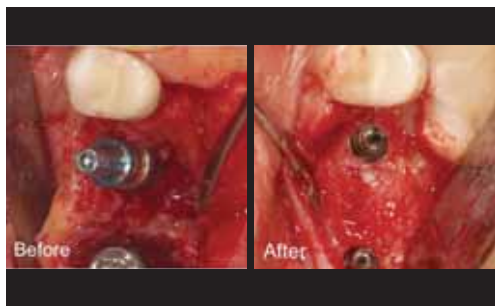


Fig.19 Before & after.

Full arch implantation with Neo NaviGuide on the edentulous mandible

Dr. Young-Ku Heo
DDS, MSD, Ph.D



QR Code by Case

Patient information

A 55-year-old, female.

Treatment Plan

1. Placement of implants on #31, 33, 34, 35, 36, 37 / #43, 44, 45, 46, 47.
2. Use full arch surgical guide.
3. One-stage approach if possible.
4. Early loading if insertion torque is over 30N/cm & ISQ value is above 70 without stability dip.
5. Final prosthesis with zirconia fixed complete denture on implants.

Tools that used in surgery

IS-III Active fixture, S-Mini fixture, S-Mini Kit, Neo NaviGuide Kit

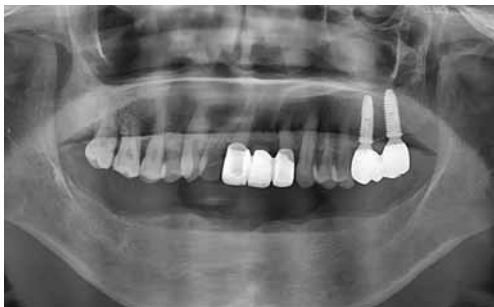

Fig.1 The patient had well-controlled hypertension and was taking an aspirin prescribed by her family doctor. It seems to have enough vertical bone for implant placement in the mandible.

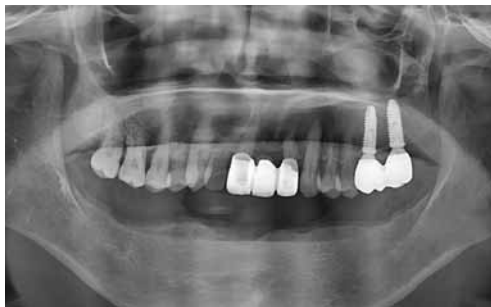

Fig.2 Pre-op panorama.

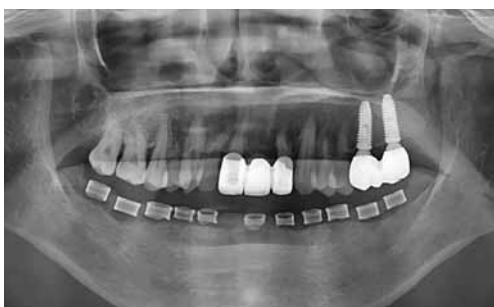

Fig.3 Panorama with the Neo NavGuide.

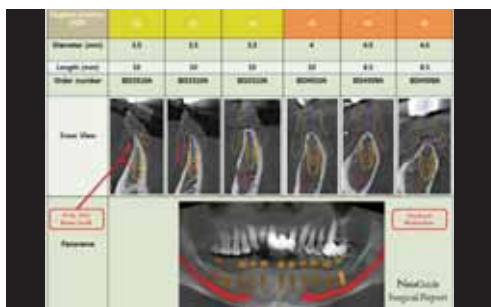

Fig.4 The posterior area was planned for placement of a 4.5 mm wide IS-III active implant and a 1-2 mm subcrestal placement to reduce exposure.

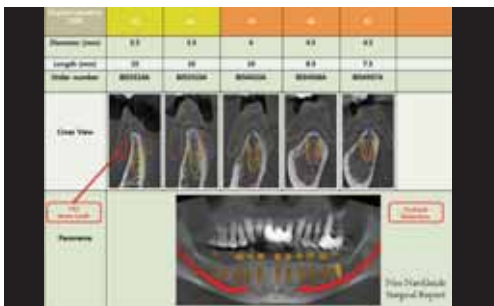


Fig.5 The posterior area was planned for placement of a 4.5 mm wide IS-III active implant and a 1-2 mm subcrestal placement to reduce exposure.

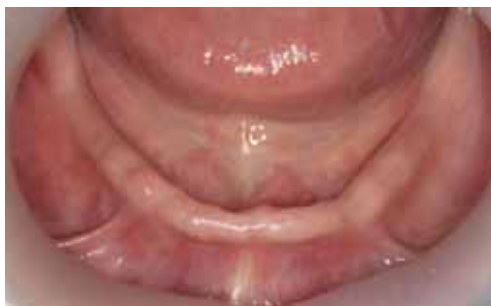

Fig.6 Intra-oral photograph.

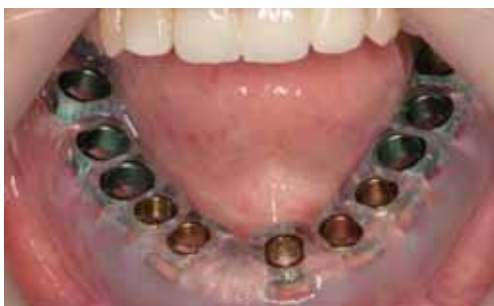

Fig.7 The Neo NavGuide was placed in the mouth.

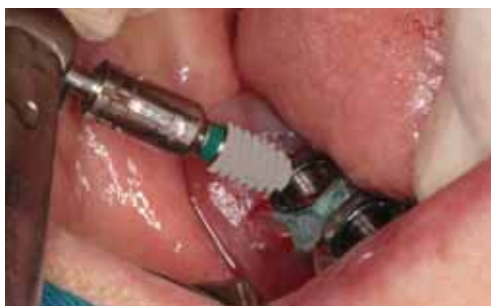

Fig.8 CMI IS-III active (Neobiotech, Korea) 4.5*7.3mm fixture was placed in the area of #47.

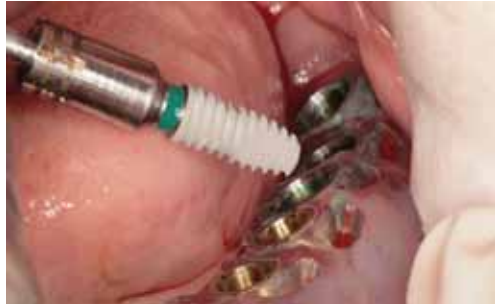

Fig.9 CMI IS-III active (Neobiotech, Korea) S-1 4.0*10mm fixture was placed in the area of #35.

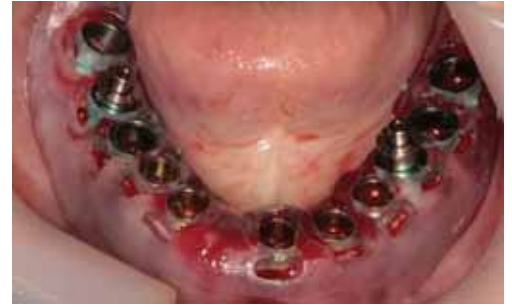

Fig.10 Fixing the Neo NaviGuide, with vertical anchor(in fixture) connected to the fixture.

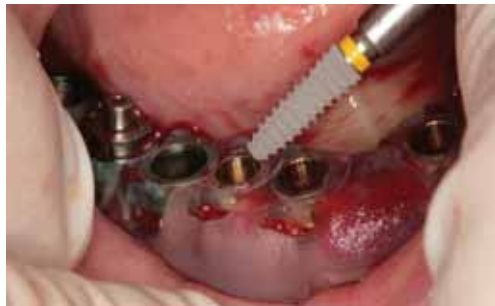

Fig.11 CMI IS-III active (Neobiotech, Korea) 3.5*11mm fixture was placed in the area of #44.

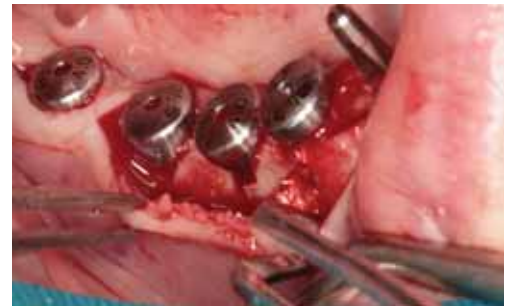

Fig.12 Healing abutments were connected to the fixtures.

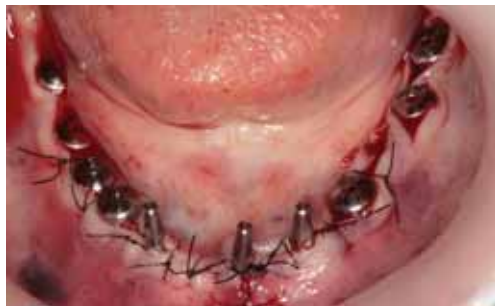

Fig.13 After the surgery.

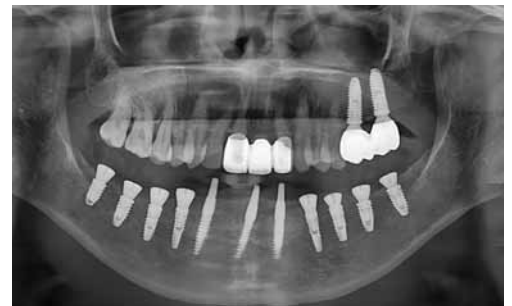

Fig.14 Post-op panorama.

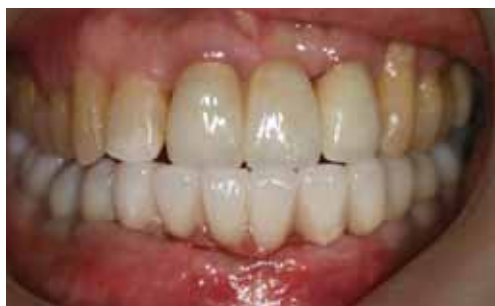

Fig.15 Final prosthesis. (zirconia fixed complete denture on implants)

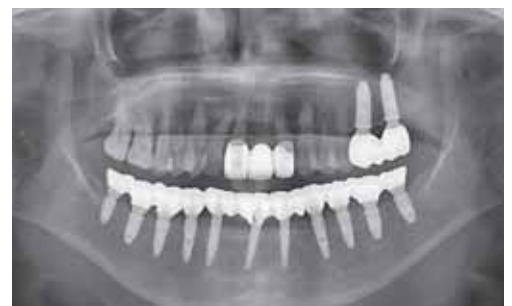

Fig.16 1 year follow-up.

CASE 4. Full arch implantation with Neo NaviGuide on the edentulous maxillary and mandible

Yongkwan Choi
DDS, MSD, Ph.D



QR Code by Case

Patient Information

Case 04. 62 years old / Male.

Treatment Plan

1. Implantation on edentulous area using surgical stent.
2. Checking by Anycheck.
3. Delivery of final prosthesis. (SCRP type)

Tools that used in surgery

IS-III Active fixture, Neo NaviGuide Kit, AnyCheck

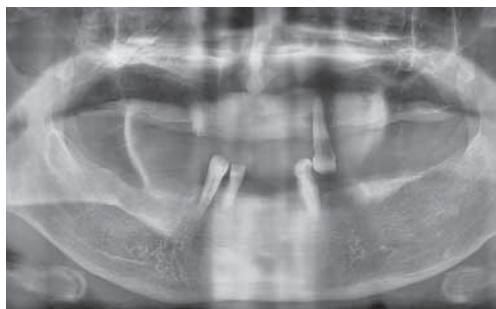

Fig.1 1st visit panorama.

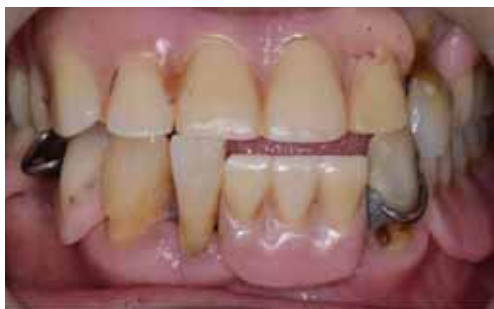

Fig.2 1st visit intraoral view.

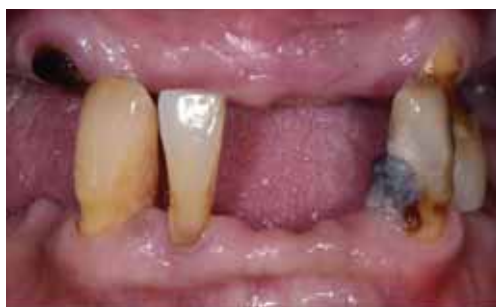

Fig.3 Pre operative intraoral view.




Fig.4 Surgical report.

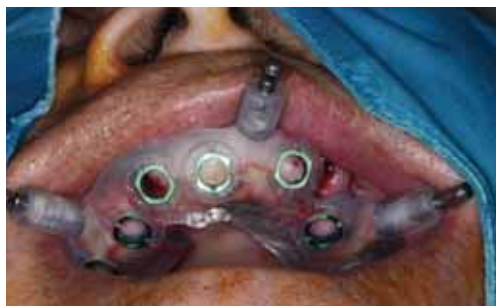

Fig.5 Maxillary surgical guide fixation after teeth extraction.

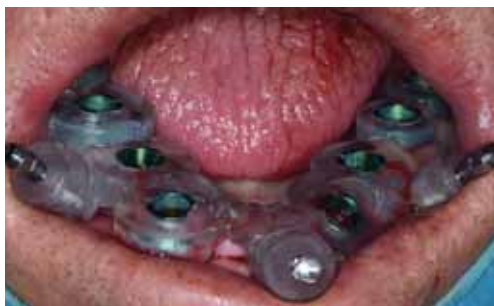

Fig.6 Mandibular surgical guide fixation after teeth extraction.

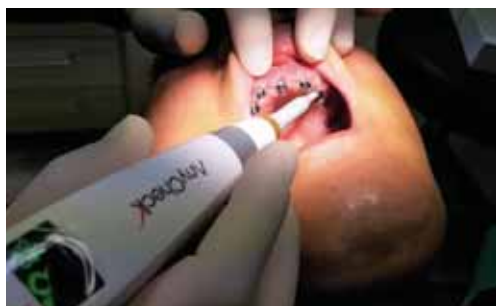

Fig.7 IST check by Anycheck.

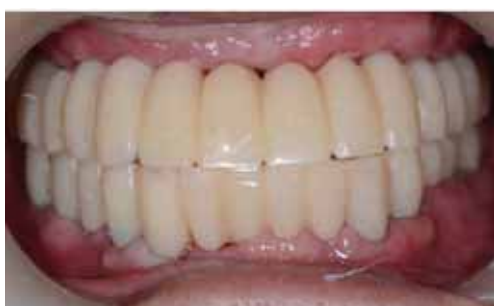

Fig.8 Loading by provisional restoration. (2 weeks after implant placement)

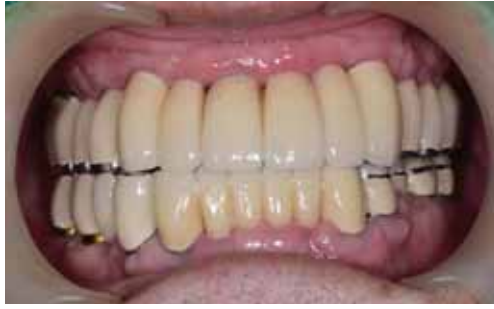

Fig.9 Final restoration. (SCR type)

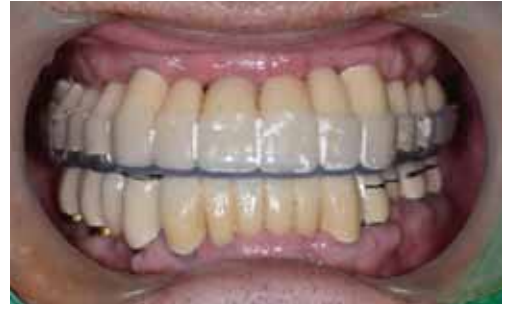

Fig.10 Night guard using 060 wafer.

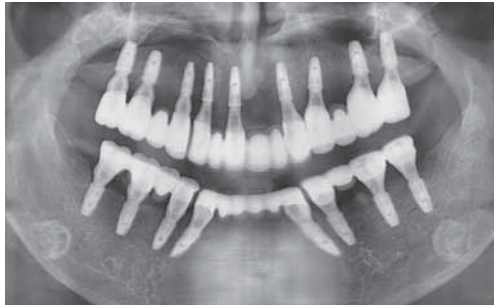

Fig.11 A panoramic radiograph after the final delivery of the prostheses.

HIGHBRIDGE CASE : 4 IS-II Active implants (NeoBiotech) in the edentulous mandible

Dr. Yukihiisa TAKAHASHI
DDS, Ph.D



QR Code by Case

Patient Information

A 60-year-old, male.

Treatment Plan

1. Implantation on #33, 35, 43, 45 using Neobiotech IS-II Active implants.
2. Removal of excessive bone around implant with bone profile bur.
3. Final prosthesis (Superstructure), the Highbridge superstructure (Dr.Yukihiisa Takahashi developed in 2017)that uses snap-stud-type attachments.

Tools that used in surgery

IS-II Active, Neo Surgical Kit, Bone Profile

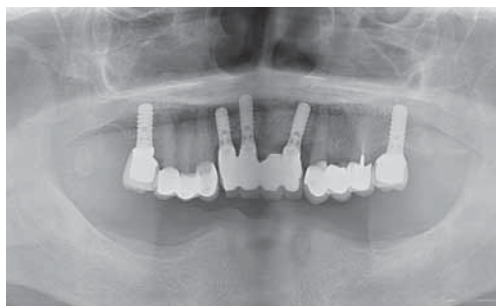

Fig.1 The residual bone in his mandible had a remarkable height difference between the anterior and posterior regions. Four NeoBiotech IS-II Active implants were placed and bone leveling was performed to adjust implant shoulder levels.

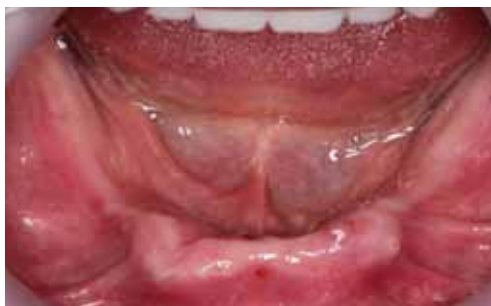

Fig.2 The residual bone in his mandible had a remarkable height difference between the anterior and posterior regions.

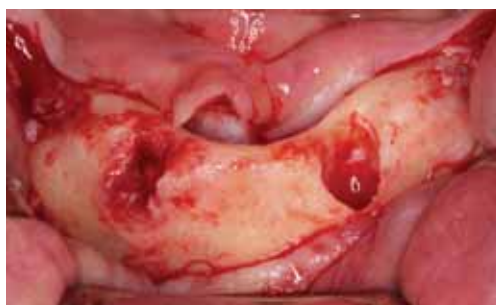

Fig.3 Four NeoBiotech IS-II active implants were placed and bone leveling was performed to adjust implant shoulder levels.

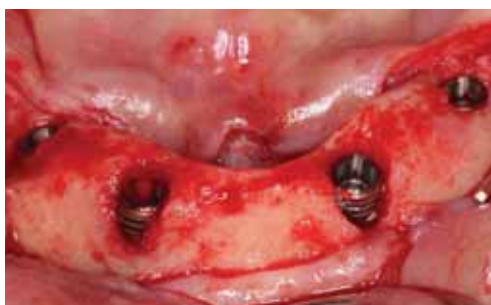

Fig.4

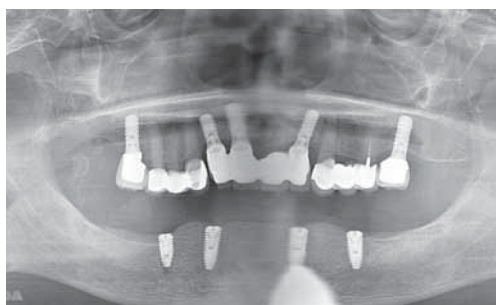

Fig.5



Fig.6 In order to remove excessive bone around an implant, Neobiotech's Bone Profile is very effective and efficient.

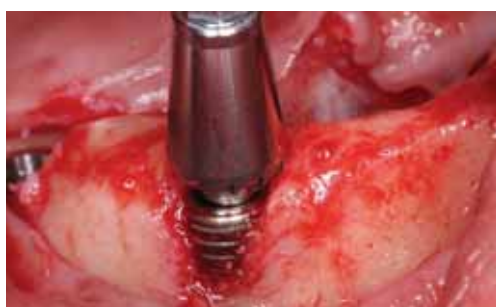

Fig.7

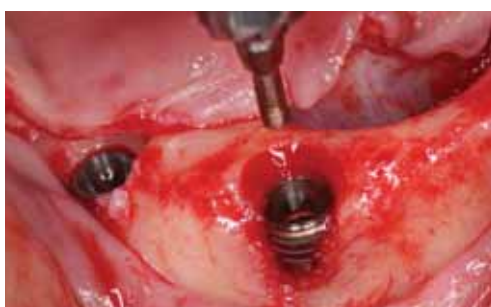

Fig.8

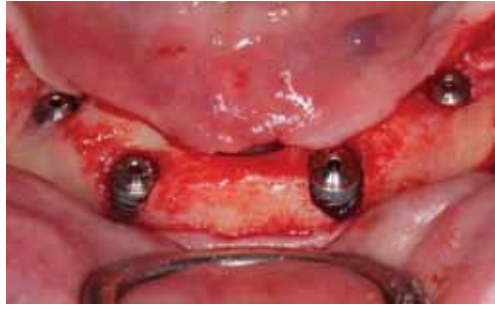

Fig.9

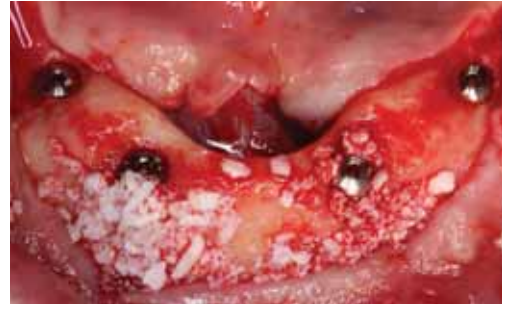

Fig.10

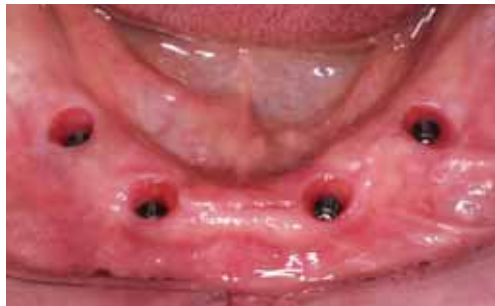

Fig.11 Four months later, peri-implant mucosa was very healthy.

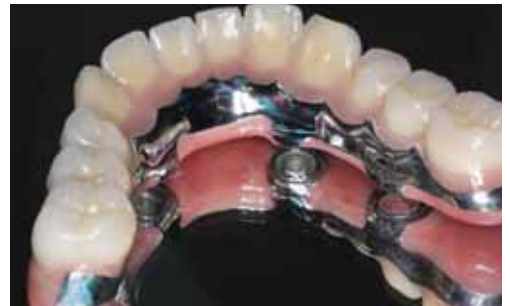

Fig.12 Highbridge superstructure.

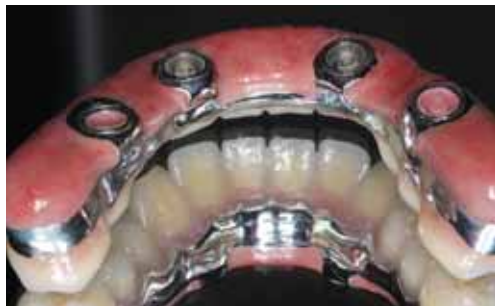

Fig.13

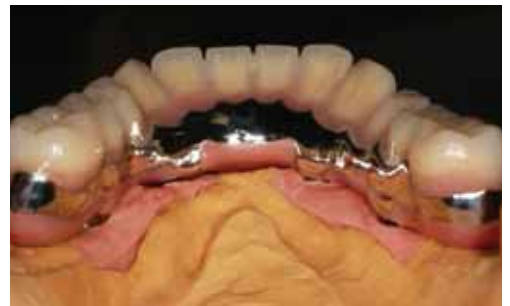

Fig.14

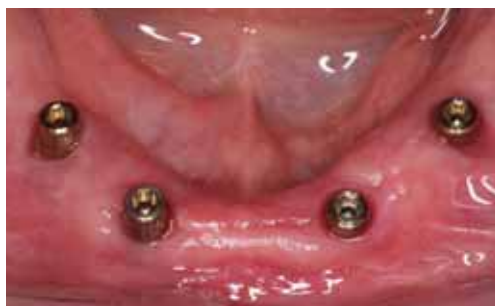

Fig.15 Wada Precision Dental Laboratories' snap-stud-type attachments were placed.

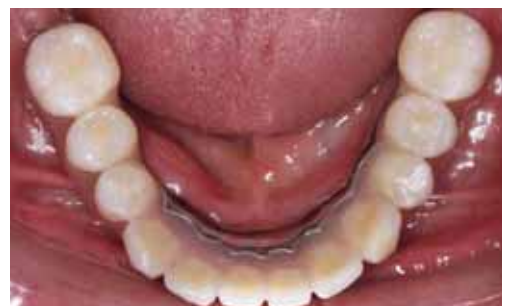
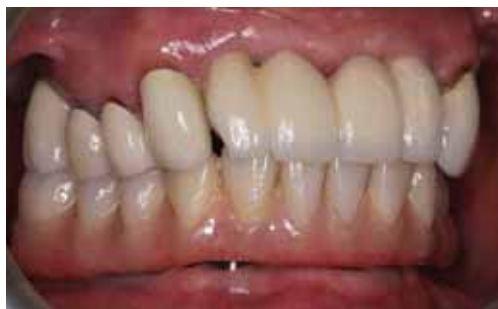
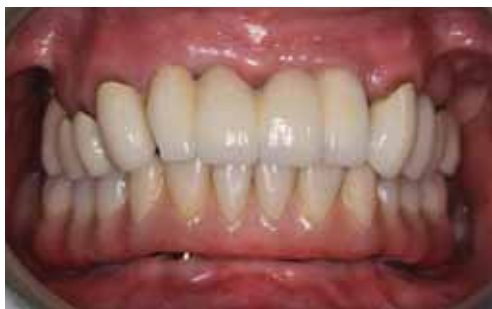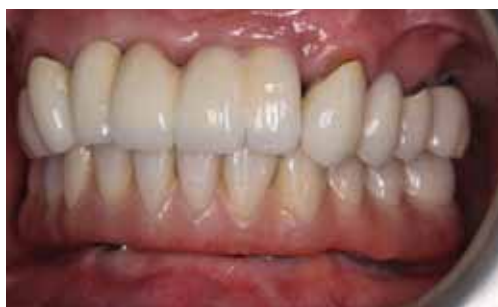Fig.16 The superstructure was designed to have sufficient space for brushing around the four implants.



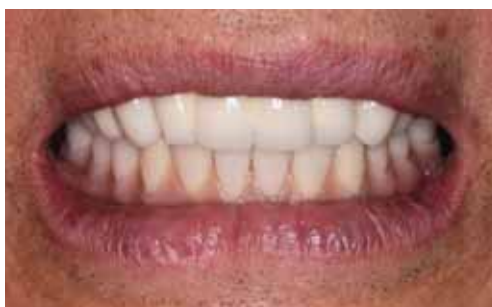| Fig.17



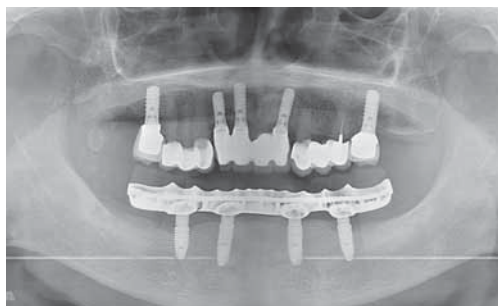| Fig.18



| Fig.19



| Fig.20



| Fig.21 1 year follow up, it is very stable not only bone and tissue around implants, but also the Highbridge superstructure.

Distal Extension Removable Partial Denture with implant-supported surveyed FPD



Dr. Chul-Wan Park
DDS, MSD, CAGS, FICD



QR Code by Case

Patient Information

A 75-year-old male patient presented with hypertension and diabetes mellitus. The patient also presented with retained roots on #14, 13, 22, 23 which had been used as abutments for RPD. Remained 3 unit FPD on #12-X-21 was mobile, and all of the remained upper teeth were non-restorable.

Treatment Plan

1. Distal Extension Removable Partial Denture for upper posterior teeth.
2. Implant placement on #14, 13, 11, 23, 24.
3. Implant-supported surveyed FPD on #14-13-X-11-X-X-23-24.

Tools that are used in surgery

IS-II Active, ACM

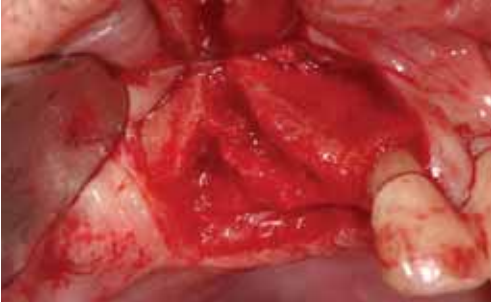

Fig.1 Implant placement & GBR on #13, 14, 23, 24 was planned.

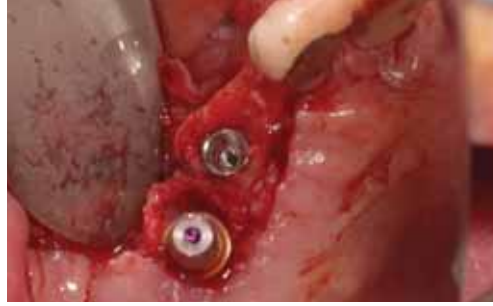

Fig.2 All of implants are Neobiotech IS-II 4.0*10mm.

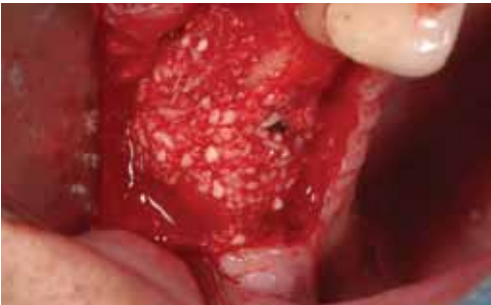

Fig.3 Allograft (ICB cortical) and collagen membranes were used for GBR. The autogenous bone was harvested using ACM drill.

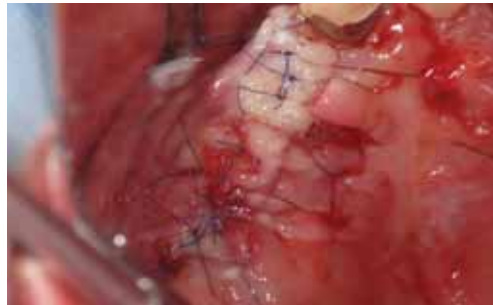

Fig.4

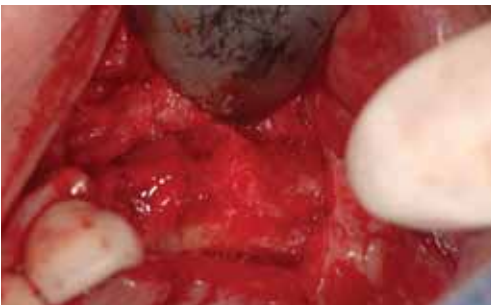

Fig.5 Implant placement & GBR procedure on #23,24.

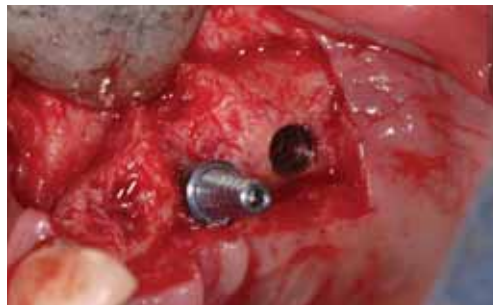

Fig.6

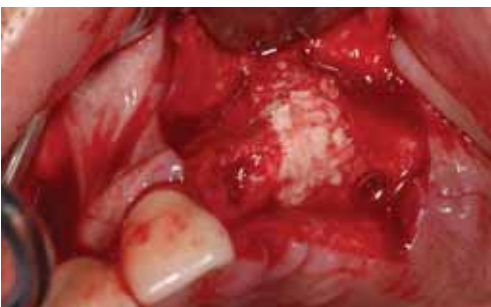

Fig.7

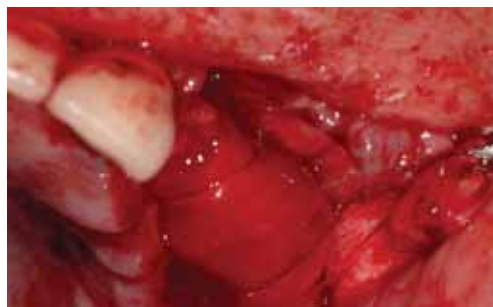

Fig.8

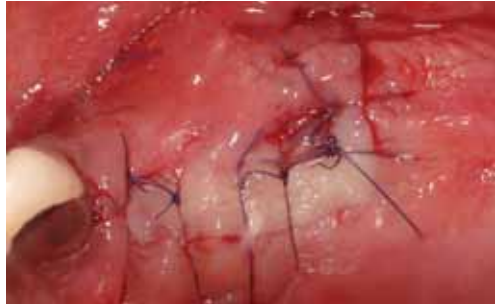

Fig.9

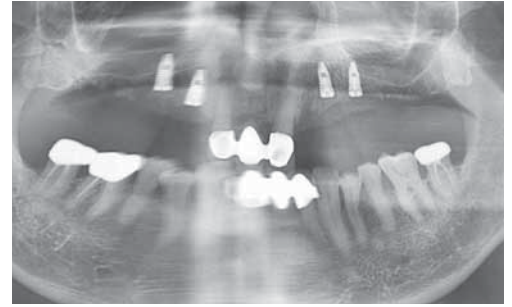


Fig.10 Panoramic view after implant placement on #13, 14, 23, 24.

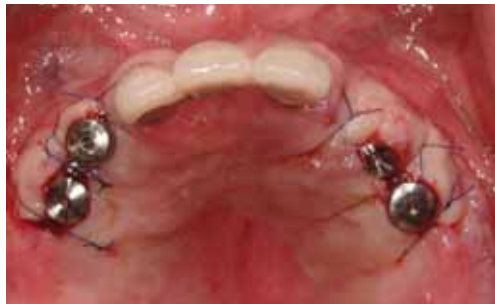

Fig.11 Uncovery of implants was done after 4 month.

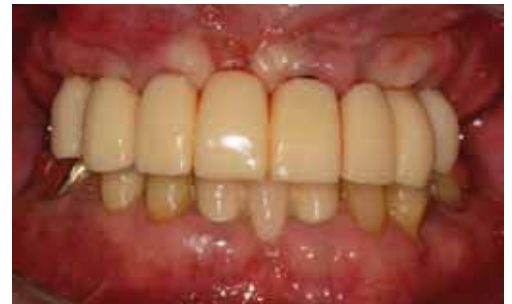

Fig.12 Extraction of remained FPD on #12-X-21 & delivery of provisional restoration on #14-13-X-X-X-X-23-24 was done afterward.

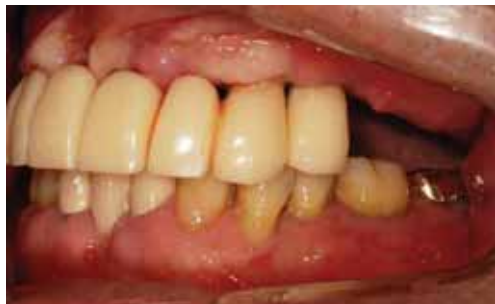

Fig.13

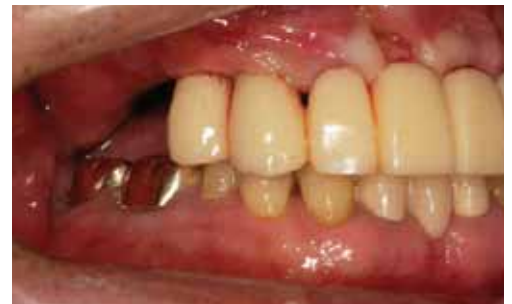

Fig.14

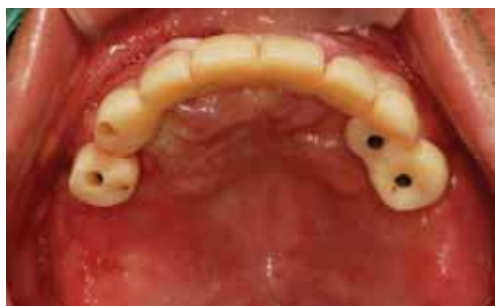

Fig.15

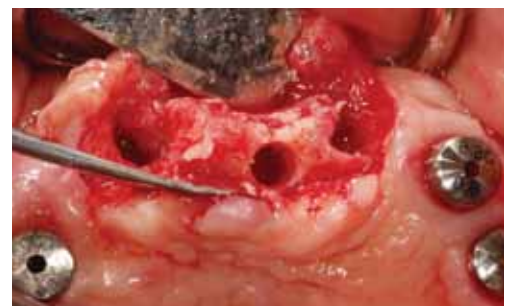

Fig.16 Finally, implant placement on #11 was done. Since there was severe bone resorption on the labial side, implant was placed intentionally on the palatal bone.

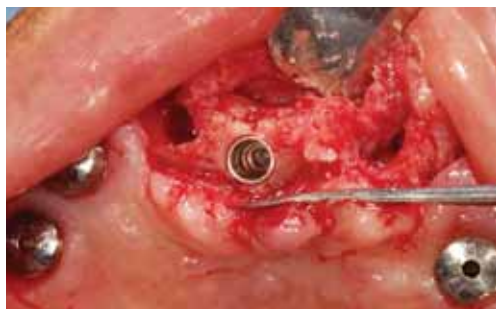

Fig.17

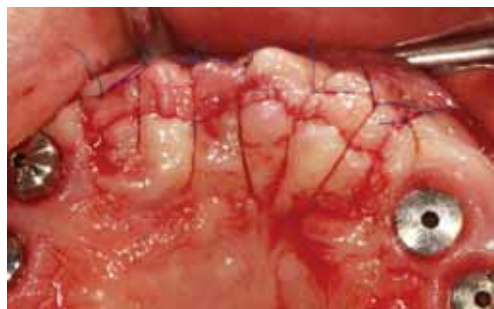

Fig.18

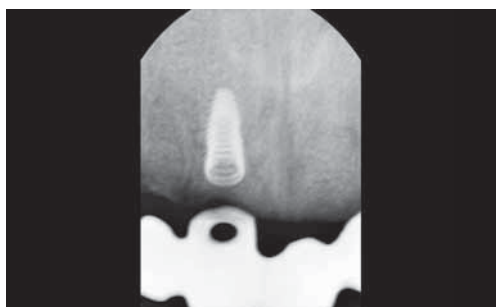


Fig.19 PA view of IS-II implant on # 11.



Fig.20 Metal frame was cut and joined to get passive fitting.

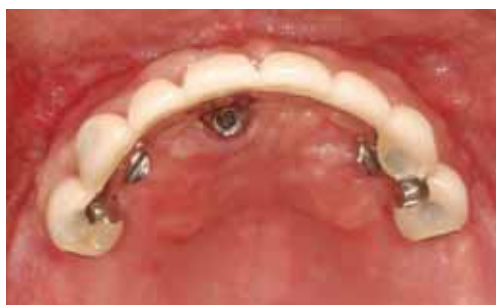

Fig.21 Design of implant-supported surveyed FPD.

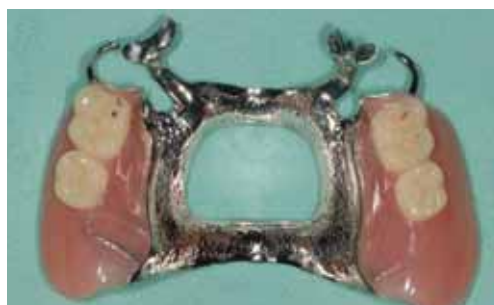

Fig.22 Design of RPD.

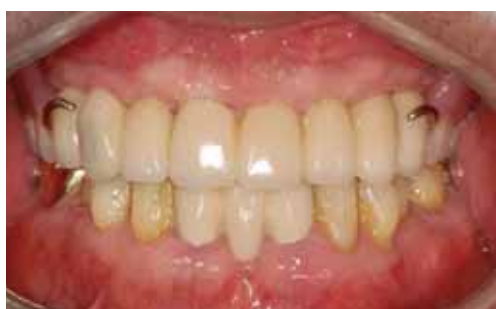

Fig.23 Prosthetic delivery.

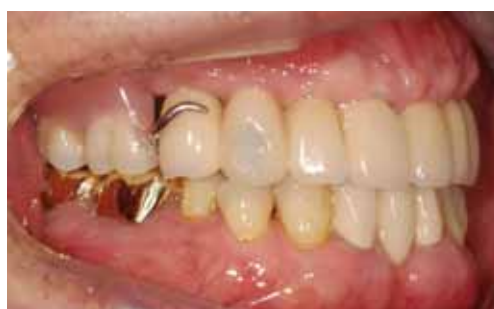
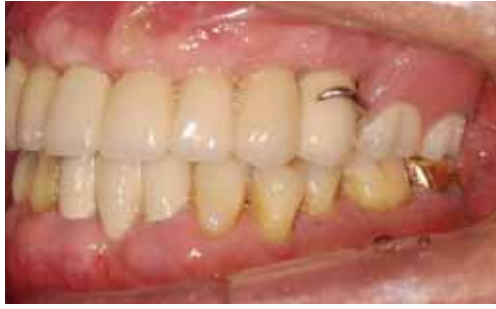
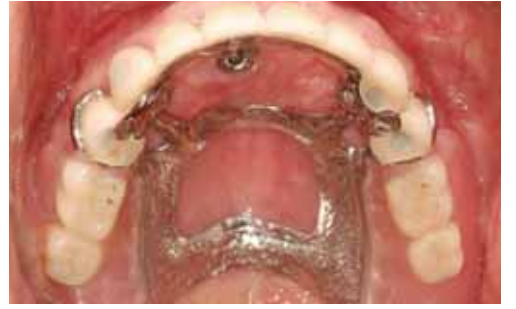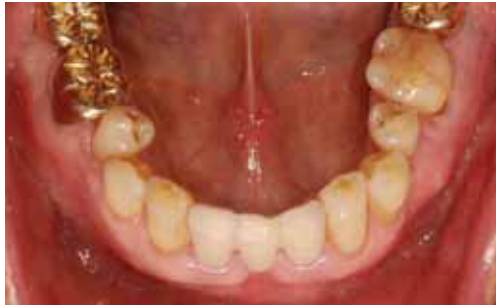Fig.24



| Fig.25



| Fig.26



| Fig.27



Implant Complication

Prevention of peri-implantitis

Atraumatic implant removal

Fractured screw removal

1 year follow-up of peri-implantitis treatment with i-Brush

Dr. Young-Ku Heo
DDS, MSD, Ph.D



QR Code by Case

Intraoral Examination

This patient was referred to the clinic for marginal bone resorption around implant #47 caused by peri-implantitis.

Treatment Plan

1. #47 - peri-implantitis treatment with i-brush.
2. GBR on defect area.
3. Delivery of original bridge.

Tools that used in surgery

i-Brush

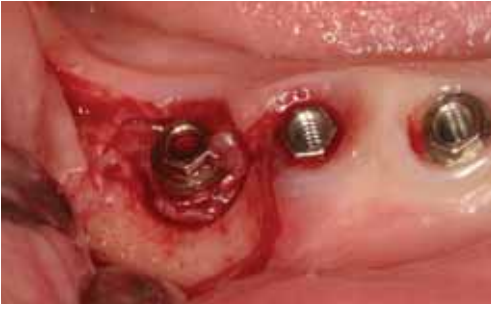

Fig.1 The implant was exposed with flap elevation and severe peri-implant bone loss was found.

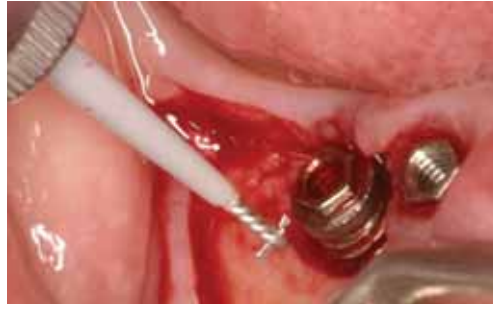

Fig.2 Each contaminated implant thread was cleaned with i Brush for 3 minutes, at 8000rpm.

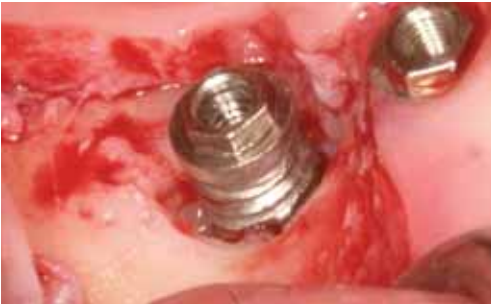

Fig.3 New rough surface has been created by i Brushing.

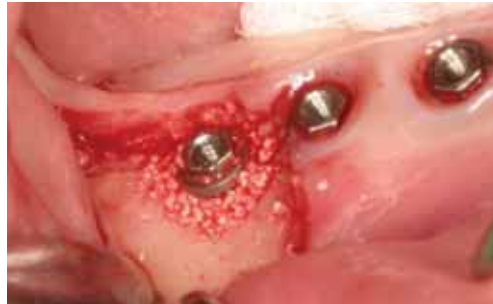

Fig.4 Bone material was applied to the defect.

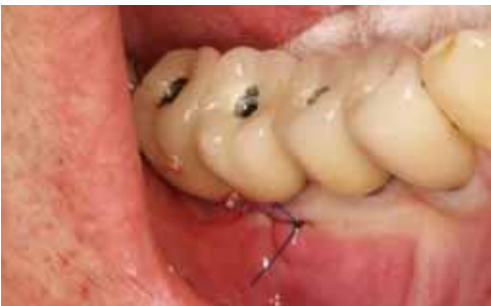

Fig.5 Original bridge was delivered on the implants right after the surgery.

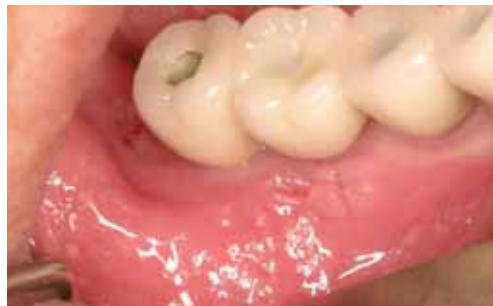

Fig.6 2 weeks after the surgery.

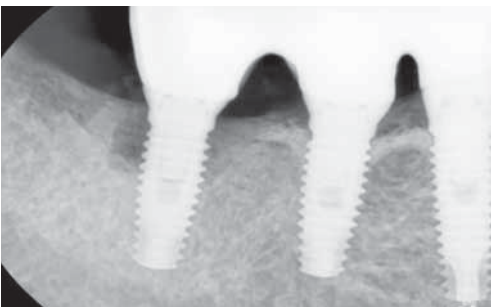

Fig.7 At surgery.

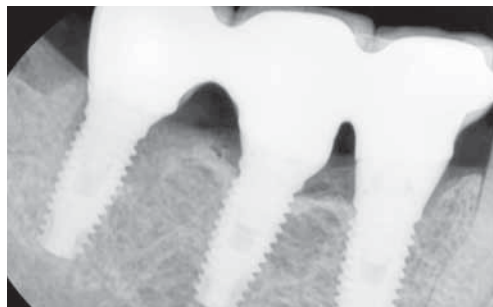
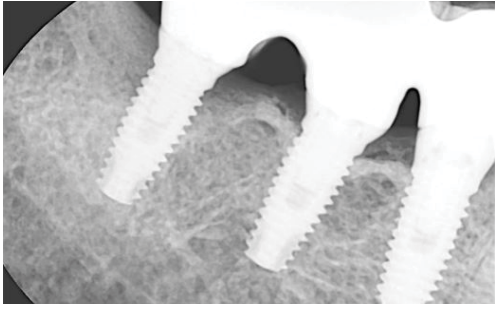


Fig.8 3 months follow-up



| Fig.9 1 year follow-up.

Peri-implantitis treatment using i-Brush and R-Brush



Dr. Jongyub Kim
DDS, MS, Ph.D



QR Code by Case

Intraoral Examination

8mm of vertical bone loss was found on #45.

Treatment Plan

1. Surgical exploration without restoration.
2. Surgical debridement of granulation tissue and cleaning exposed implant surface with I-brush and R-brush.
3. Bone graft filling on defect.
4. Suture and F/U.

Tools that used in surgery

R-Brush, i-Brush

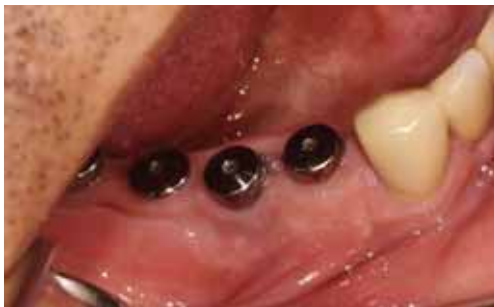

Fig.1 8mm of vertical bone loss was found on #45.

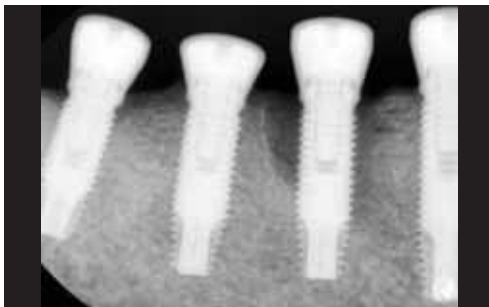


Fig.2 8mm of vertical bone loss was found on #45.

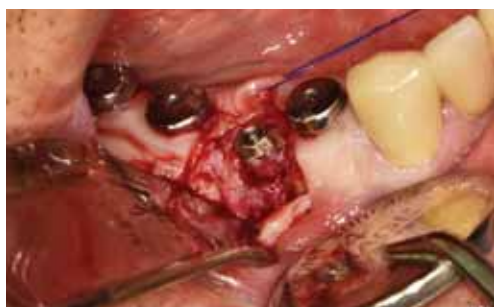

Fig.3

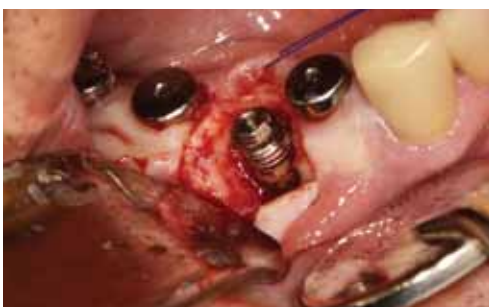

Fig.4 The implant was exposed with flap elevation and severe peri-implant bone loss was found.

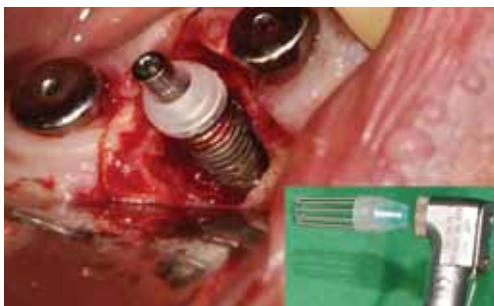

Fig.5 A R-Brush was used for mechanical cleansing of circumferential defect at 8000rpm

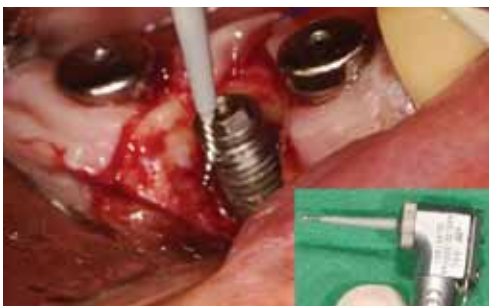

Fig.6 Noncircumferential defect was cleaned with an i Brush for 3 minutes each thread. It was used at 3000 to 5000rpm.

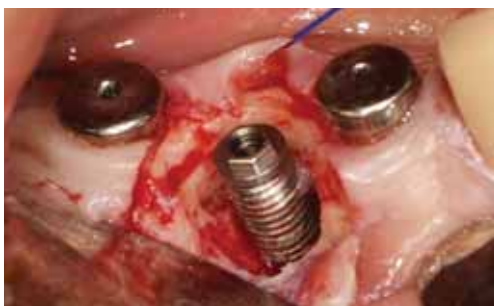

Fig.7 New rough surface has been created.

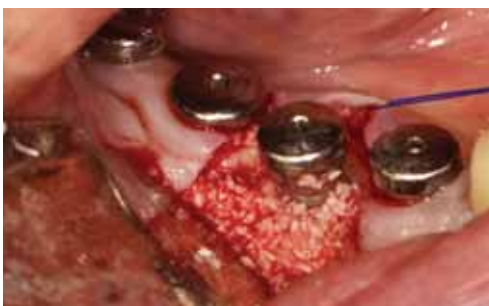

Fig.8 Bone material was applied to the defect.

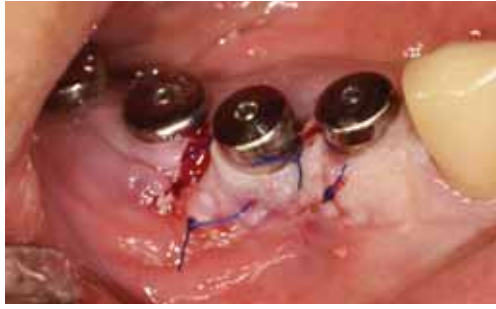

Fig.9 The wound area was sutured.

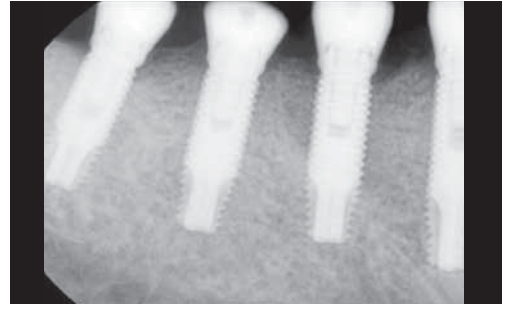


Fig.10 Postoperative radiographic view verifies crestal level of peri-implant bone.

Good Neo Product for peri-implantitis treatment with an i-Brush

Yongkwan Choi
DDS, MSD, Ph.D



QR Code by Case

Patient information

47 years old / Male.

Treatment Plan

1. #35 Immediate implant placement.
2. #36, 37 - peri-implantitis treatment with i-brush.
3. GBR with combination of xenograft and autogenous bone. (ACM drill)

Tools that used in surgery

i-Brush, ACM

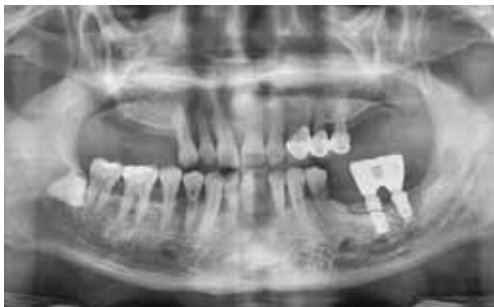

Fig.1 First visit, Peri-implantitis on #36 and #37.

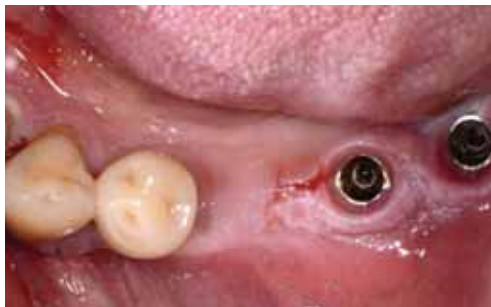

Fig.2 Existing implant prosthesis removal.

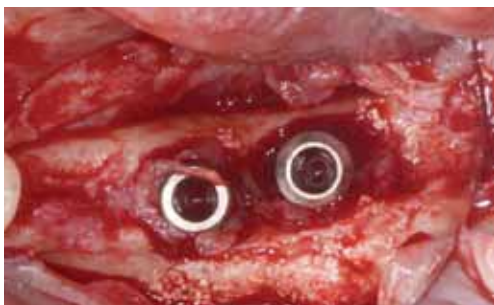

Fig.3 A broad bone loss occurred including inflammatory granulation tissue caused by peri-implantitis.



Fig.4 i-Brush.

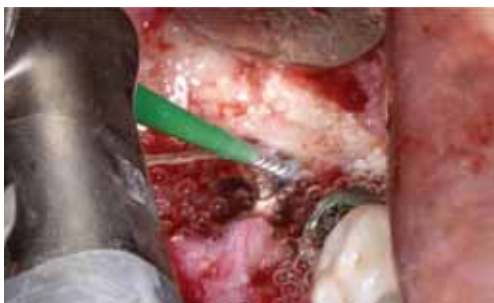

Fig.5 i-Brush was used for the granulation tissue removal and cleaning the contaminated implant surface.

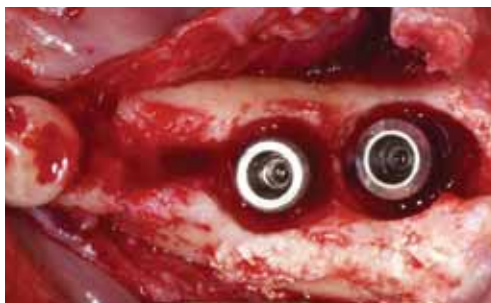

Fig.6 Removed granulation tissue and each contaminated implant thread was cleaned with a i-Brush.

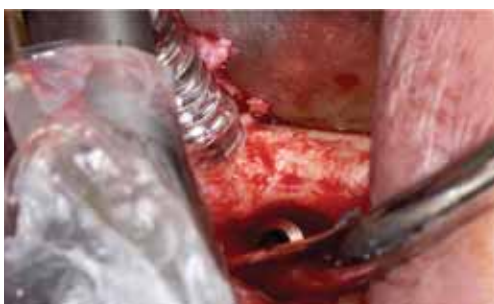

Fig.7 Auto graft bone was harvested by using the ACM drill.



Fig.8 Combination of auto graft bone and xeno graft bone.

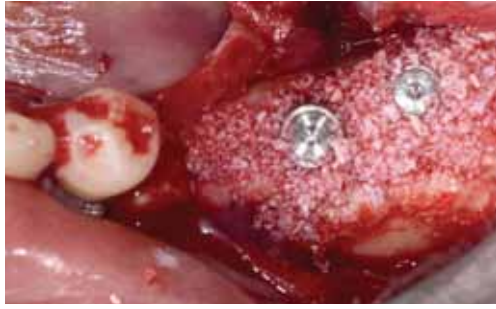

Fig.09 Bone graft.

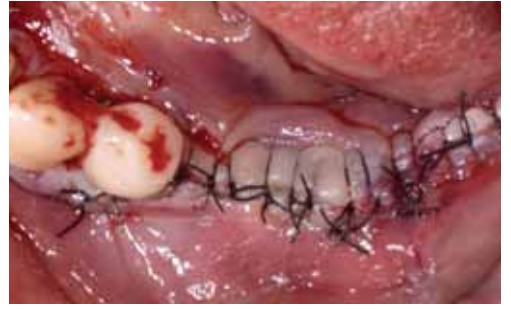

Fig.10 Suture was performed.

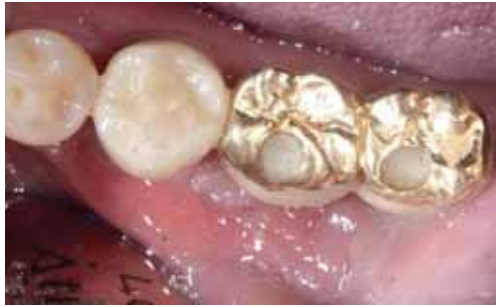

Fig.11 Existing prosthesis, additional implant placement on #35.

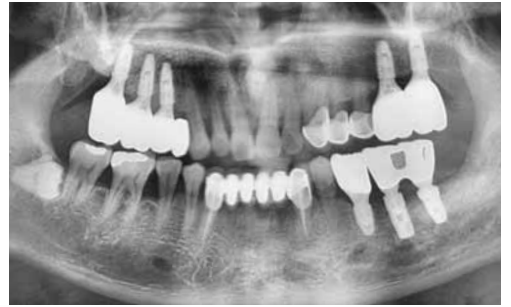

Fig.12 After 2 years.

Minimally invasive removal of a periodontally compromised implant



Dr. Young-Ku Heo
DDS, MSD, Ph.D



QR Code by Case

Intraoral Examination

- #35: Bone loss of 3mm.
- #36: Floating with no bone development & gingival inflammation.
- #37: Bone loss of 5mm.

Treatment Plan

Remove the periodontally compromised implants #35, 36 and 37 with FR Kit.

Tools that used in surgery

FR Kit

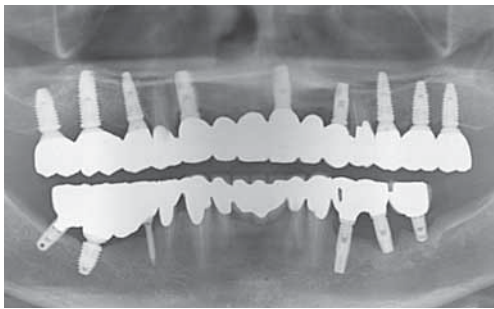


Fig.1 - #35 : Bone loss of 3mm.
 - #36 : Floating with no bone development & gingival inflammation.
 - #37 : Bone loss of 5mm.




Fig.2 - #35 : Bone loss of 3mm.
 - #36 : Floating with no bone development & gingival inflammation.
 - #37 : Bone loss of 5mm.

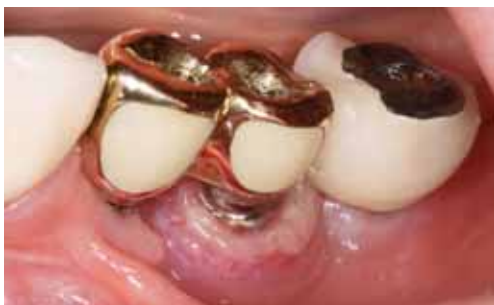

Fig.3 - #35 : Bone loss of 3mm.
 - #36 : Floating with no bone development & gingival inflammation.
 - #37 : Bone loss of 5mm.

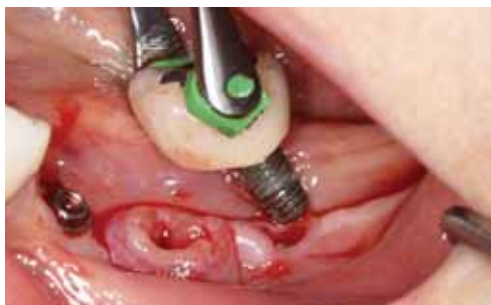

Fig.4 Failed implants #36 and #37 were easily removed with a crown remover.

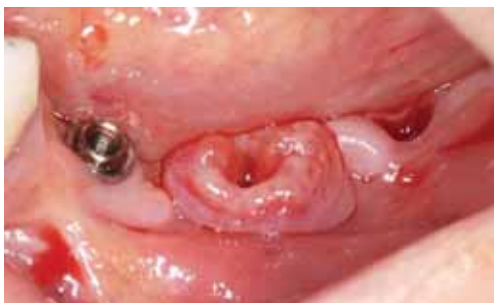

Fig.5 The buccal view following removal of #36 and #37.

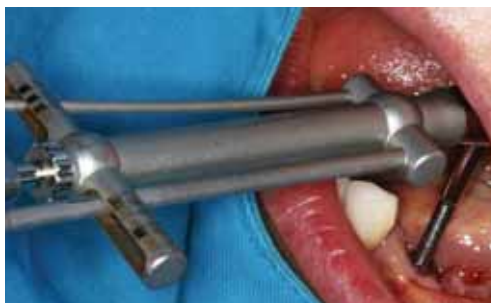

Fig.6 A fixture remover screw was screwed into the implant fixture #35 with 70Ncm of wrench torque. (less than 80Ncm is recommended)

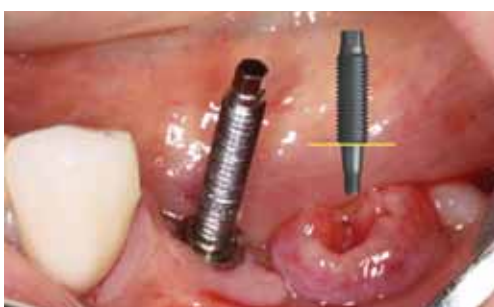

Fig.7 A fixture remover screw must be inserted to the yellow line marked on a 3D image to prevent them from getting fractured. Bottom threads are in the opposite direction to upper threads.

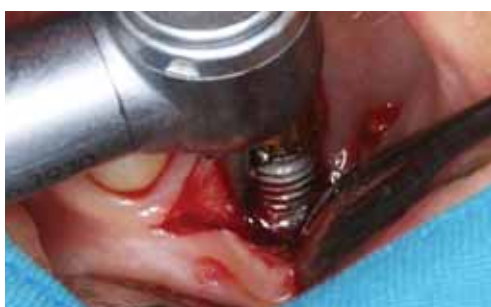

Fig.8 A fixture remover that fits to the coronal part of the implant was screwed on the removal screw in counterclockwise direction. 300Ncm counter-torque was applied with copious water, but failed to unthread the implant.

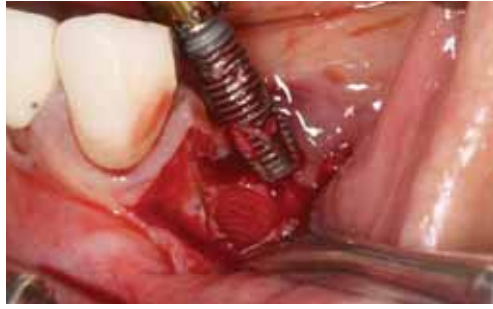

Fig.9 With 1mm of crestal bone prep, the implant started to come out at 200Ncm counter-torque.

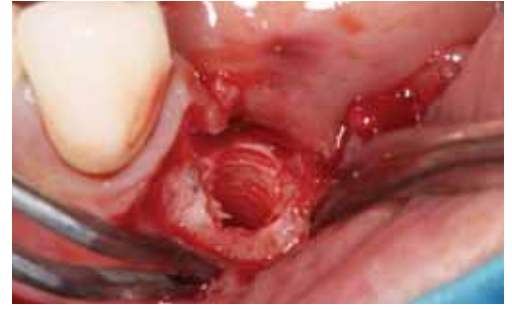

Fig.10 As the favorable bony conditions of threads are preserved, implant may be inserted again with good prognosis.

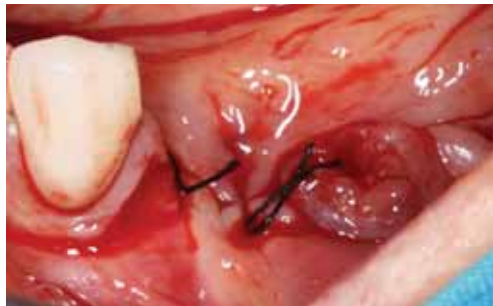

Fig.11 The surgical site was simply sutured.

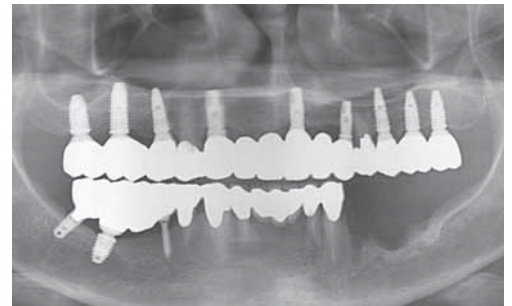


Fig.12 Postoperative radiographic view.

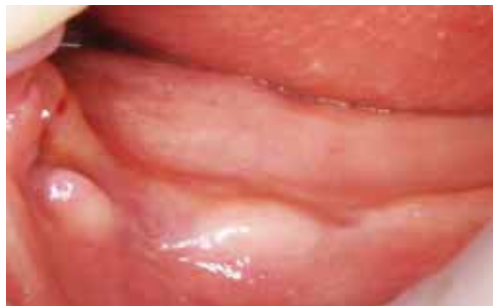

Fig.13 The surgical site following a month of tissue healing.

Immediate implant placement on right maxillary central incisor according to the principles with IS-II Active implant



Dr. Paweł Strzępek
DDS



QR Code by Case

Situation

Patient was a 49 years old female, who lost her crown as well as the post and core of tooth 11 when biting on a mouthpiece of a diving apparatus. She came to the clinic 5 days after she had lost the tooth. An x-ray of the tooth was performed on that day and the treatment plan was explained to the patient.

Treatment Plan

1. Extraction of rest of the root. (#11)
2. Implant placement with Neobiotech IS-II Active implant.
3. Temporary immediately prosthetic.
4. Final prosthesis.

Tools that used in surgery

FR Kit

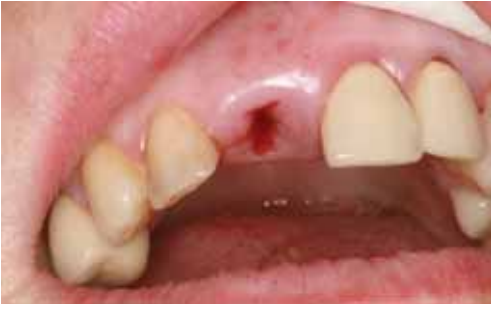

Fig.1 Condition of the patient 5 days after the crown was lost.

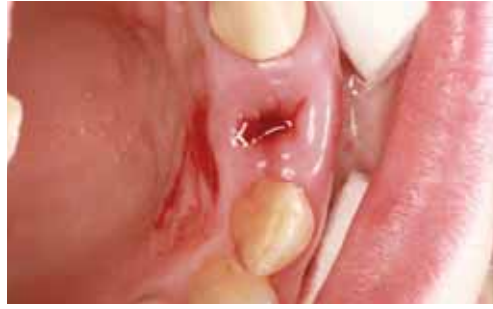

Fig.2

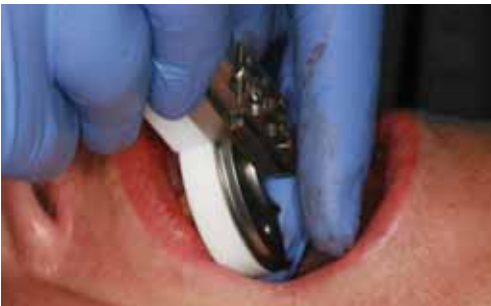

Fig.3 Under infiltration anaesthesia the fractured root was removed atraumatically with periostomes and a Bendix device manufactured by Zepff.

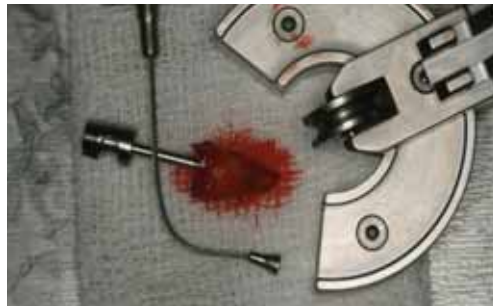

Fig.4

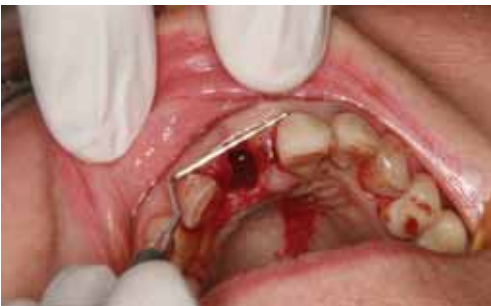

Fig.5 The implant bed was formed according to the principles of immediate implantation technique.

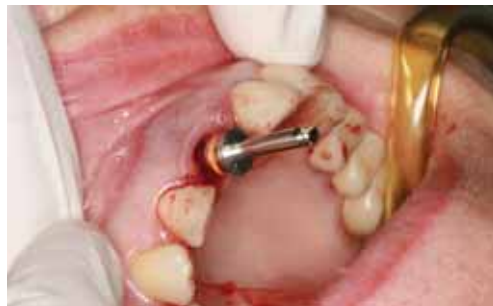

Fig.6

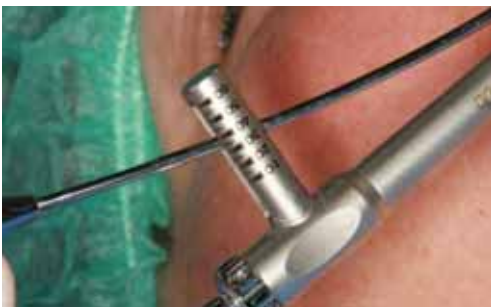

Fig.7 An IS-II Active implant of 3.5 mm in width and 13 mm in length manufactured by NeoBiotech was immersed with the force of 40 Ncm.

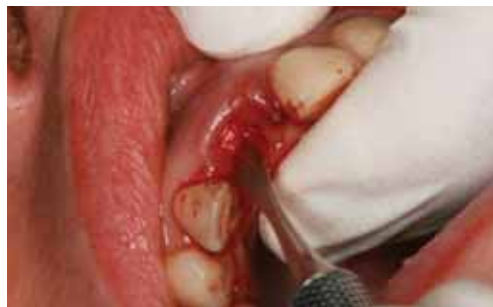

Fig.8 The fissure between the implant and the vestibular bone lamella was augmented.

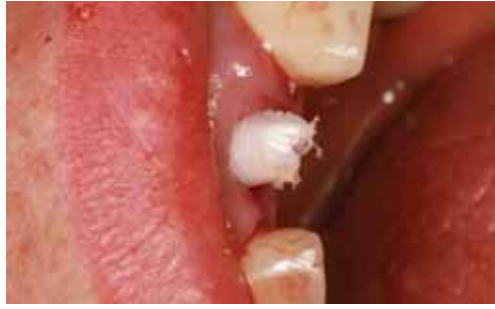

Fig.9 A prosthetic restoration was preformed supported by a temporary connector.

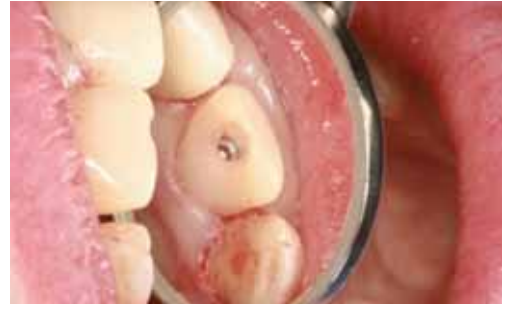

Fig.10

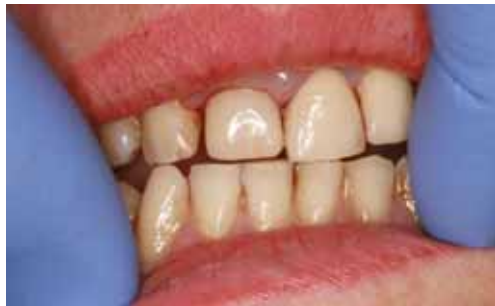

Fig.11

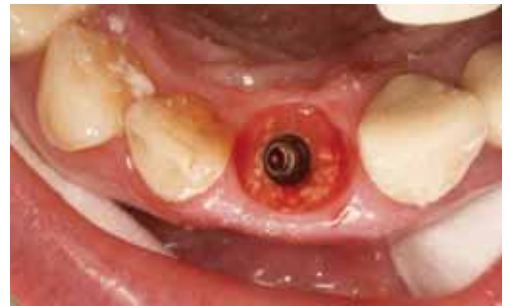

Fig.12 While preserving the implant emergence profile, which had been obtained during healing.

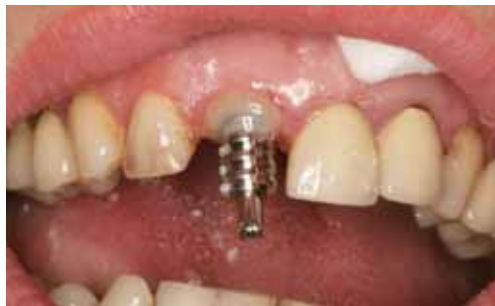

Fig.13 After an 8-week integration period impressions were collected.

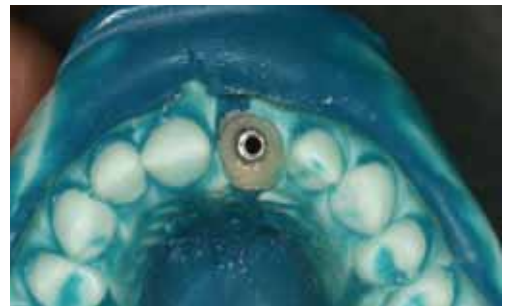

Fig.14

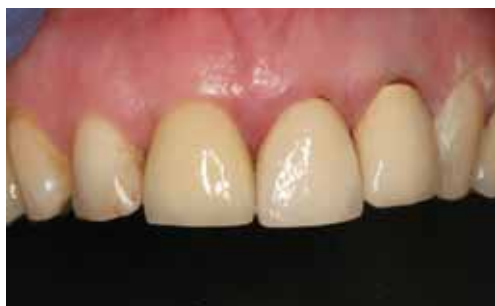

Fig.15 The final prosthetic restoration was formed.

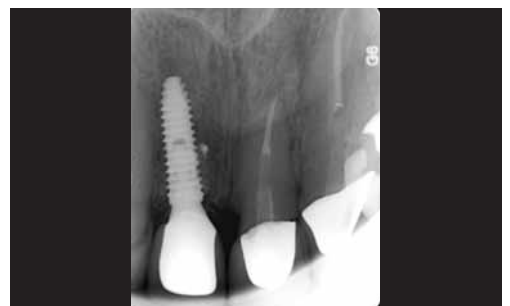

Fig.16 A periapical x-ray was performed to evaluate embedment of the restoration.

Removal of a fractured implant screw



Dr. Young-Ku Heo
DDS, MSD, Ph.D



QR Code by Case

Patient information

A 47-year-old, male.

Treatment Plan

Removal of the fractured implant screw in the area of #36 with SR Kit.

Tools that used in surgery

SR Kit

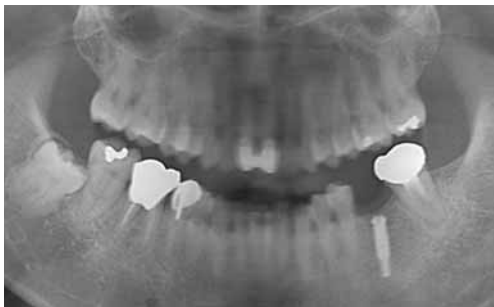

Fig.1 A 47 year old male patient was referred to the clinic with a fractured implant screw.




Fig.2 A Ø1.2mm Perfect guide connected to a PG driver.

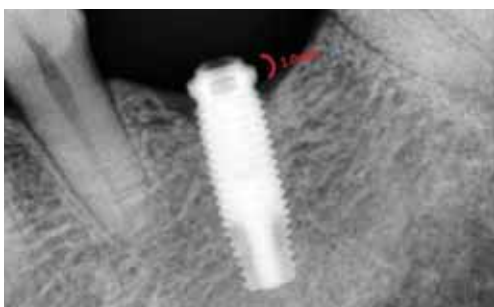


Fig.3 Periapical view. For a perfect guide to be screwed into the screw hole, an implant has to have at least 1mm of the screw threads on top of the fractured screw.

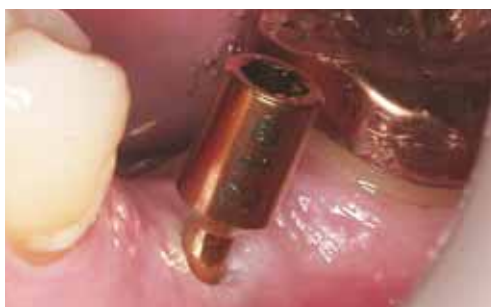

Fig.4 A Ø1.2mm perfect guide was tightened to 15Ncm in the screw hole. A perfect guide positions a drill the dead center of the screw and prevents it from damaging the threads of the implant.

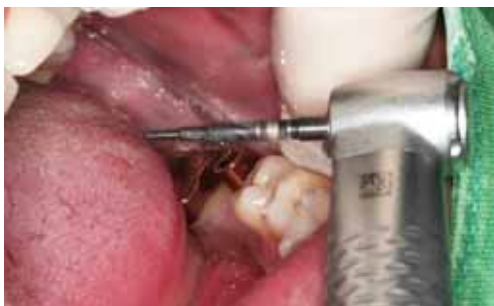

Fig.5 A Ø1.0mm reverse drill is used at 2,000rpm with copious water irrigation. Drilling direction should be in reverse.



Fig.6 Implant motor was turned on reverse.

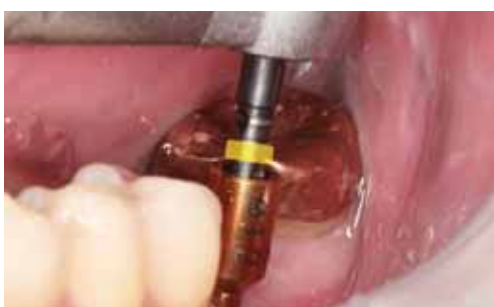

Fig.7 Using a perfect guide, a reverse drill was placed right on top of the fractured screw. Then approximately 1.0mm was gently drilled vertically down. The use of rubber stoppers is suggested for 1.0mm of depth control.

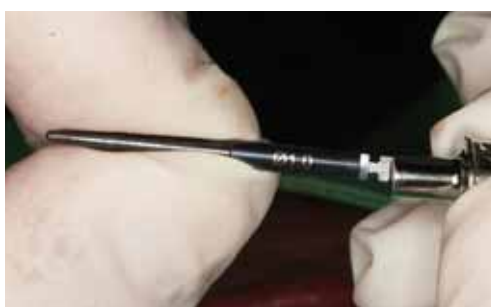

Fig.8 A Ø1.0mm screw remover matching to the reverse drill is being connected to a shank driver.

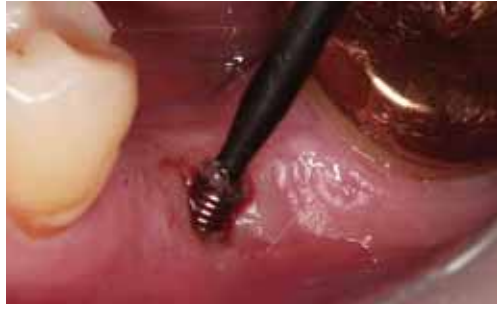

Fig.9 The fractured screw was being removed by rotating the screw in counterclockwise direction.

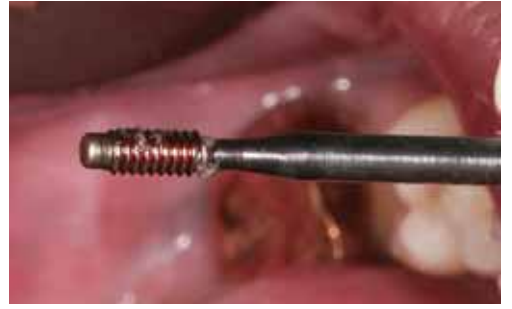

Fig.10 The fractured screw came out of the screw hole.




Fig.11 Drilled site in the center of the fractured screw.

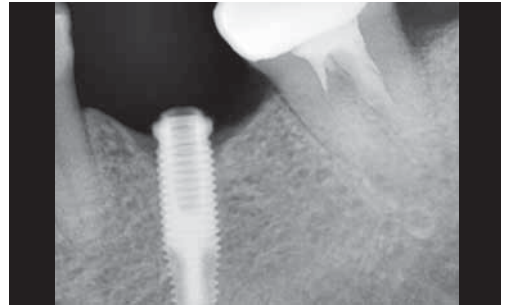



Fig.12 Postoperative view of screw removal.

Removal of a fractured implant screw



Dr. Young-Ku Heo
DDS, MSD, Ph.D



QR Code by Case

Patient information

A 54-year-old, female.

Treatment Plan

Removal of the fractured implant screw in the area of #11 with SR Kit.

Tools that used in surgery

SR Kit

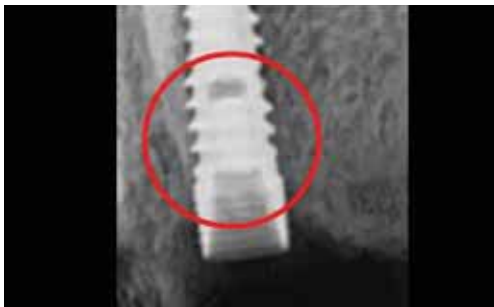

Fig.1 Preoperative view of screw removal.

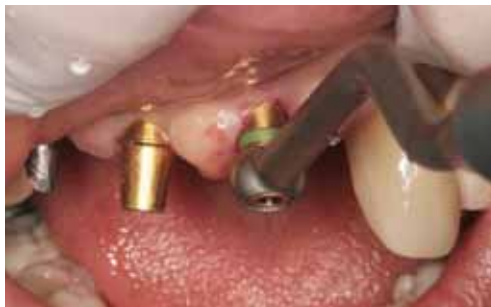

Fig.2 Perfect guide connected to a PG driver.

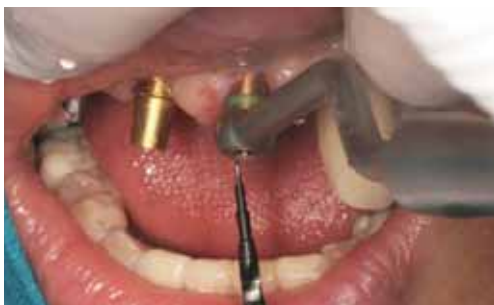

Fig.3 A Ø1.0mm reverse drill was used at 2000RPM with copious water irrigation.

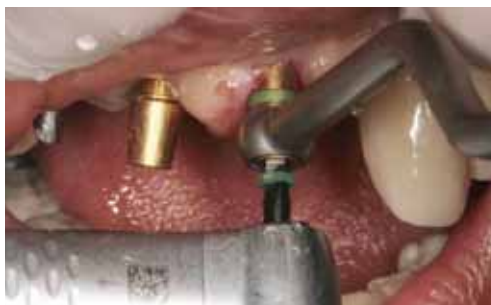

Fig.4 Drilling direction should be reversed.

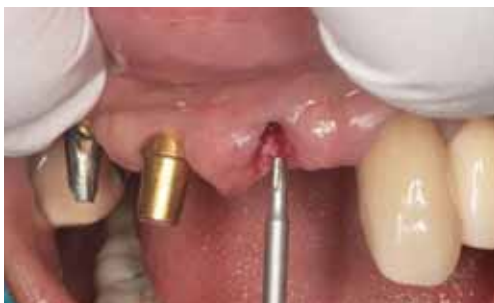

Fig.5 A Ø1.0mm screw remover matching to the same size of reverse drill.

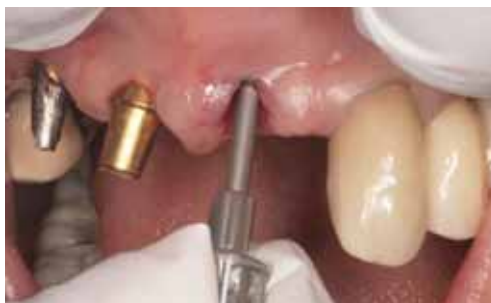

Fig.6 The fractured screw was being removed by rotating the screw in counterclockwise direction.

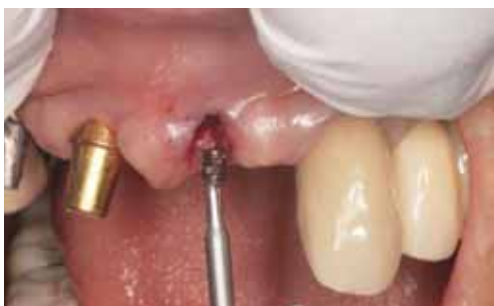

Fig.7 The fractured screw came out of the screw hole.

Intraoral Scanning System using an Encoded Healing Abutment a Scan Body

Dr. Young-Ku Heo
DDS, MSD, Ph.D



QR Code by Case

Patient information

A 65-year-old, male.

Situation

The patient came to the clinic with a periapical lesion on #24.

Tools that used in surgery

IS-III active, Neo NaviGuide Kit, Bone Trimmer

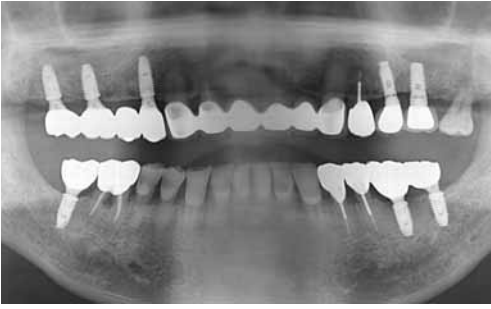

Fig.1 #24 was planned to be replaced with an implant, because it was considered hopeless after a half year of the endodontic treatment.

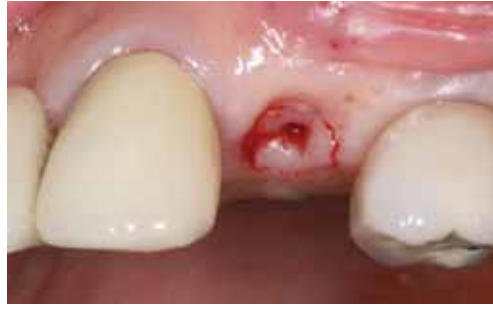

Fig.2 After 1 months of #24 extraction, flapless implant surgery was performed by tissue punching.

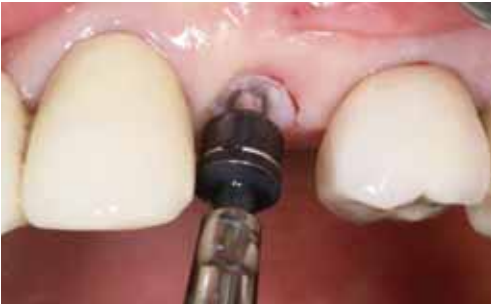

Fig.3 The implant bed was drilled 4-5mm deeper than the fixture height using an initial point drill and a Ø2.2 drill. Its purpose was to place the implant 3mm below the gingival zenith.

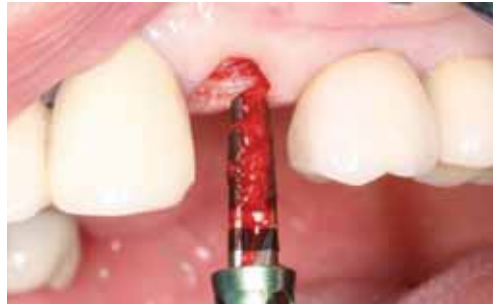

Fig.4 A narrow final drill was used to place a Ø4.0X11.5mm implant fixture. Final drilling in an extraction socket is usually performed with an one size narrower drill.

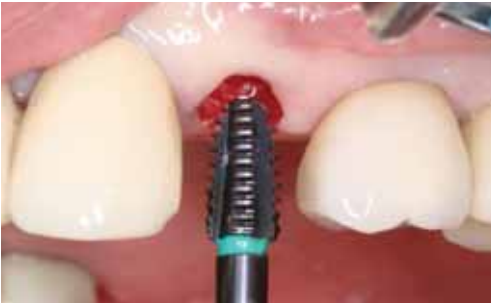

Fig.5 Ø4.0 profile tapping was performed as it was D1 Dense bone. The implant site was tapped 3mm below the gingiva by using a profile tap.

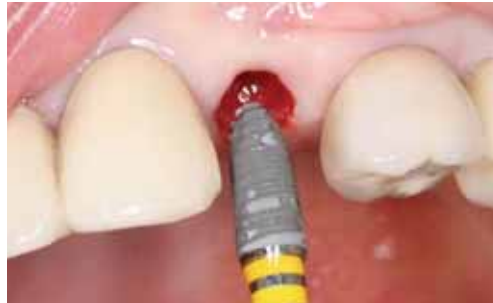

Fig.6 A Ø4.0X11mm IS II active implant soaked in saline was placed. The implant was placed 3mm below the gingival zenith as placed it up to the 2nd marking on a fixture driver.

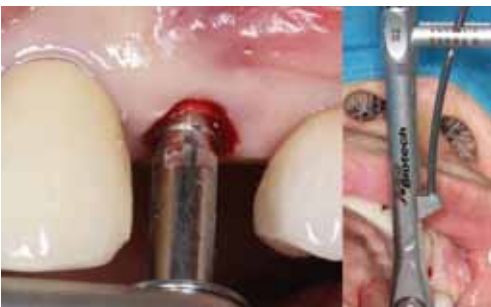

Fig.7 The implant was placed 3mm below the gingiva, and 40Ncm of primary stability was obtained.

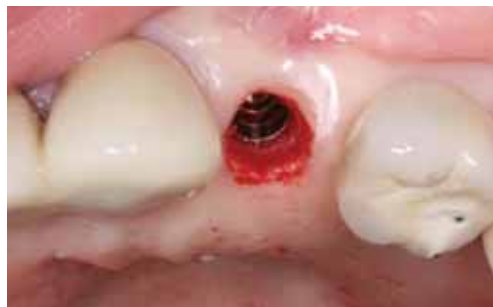

Fig.8 The surrounding bone could be an obstacle of abutment connection.

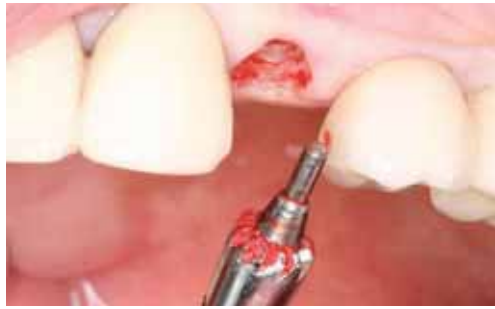

Fig.9 Neobiotech Bone Profile was used at 80rpm to trim the surrounding bone.
*Bone profile must be used under 80rpm.

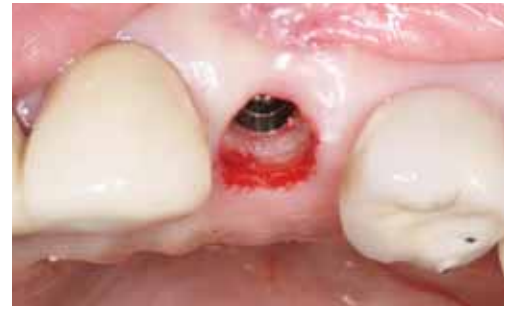

Fig.10 The implant site trimmed with a bone profile.

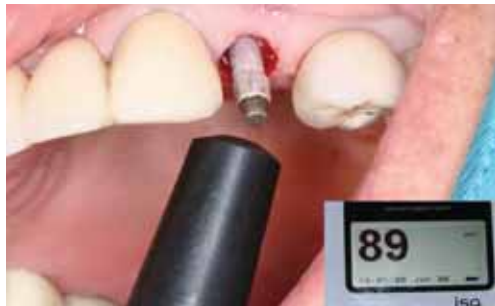

Fig.11 89 of sufficient ISQ value was obtained. The implant was able to avoid compaction and have a good stability through tapping. It was ready to immediately load an implant.

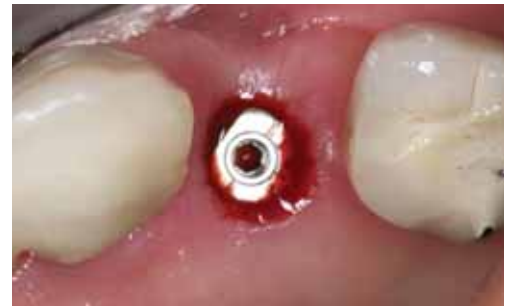

Fig.12 A Ø4.5 Encoded healing abutment was placed on #24. Through intraoral scanning, the length and the diameter of an encoded healing abutment, and the position of its hexagon were able to be recognized.

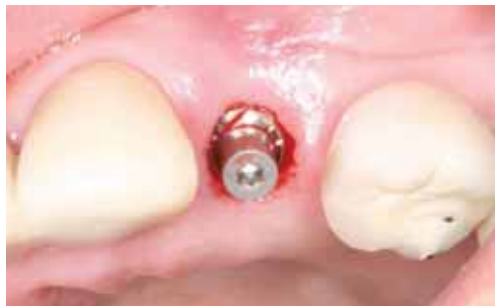

Fig.13 A scan body pin was placed on the encoded healing abutment for more detailed scanning.

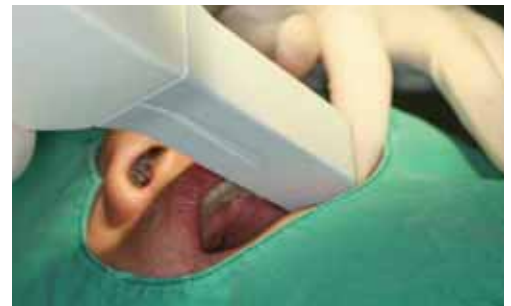

Fig.14 Intraoral scanning using Trios.

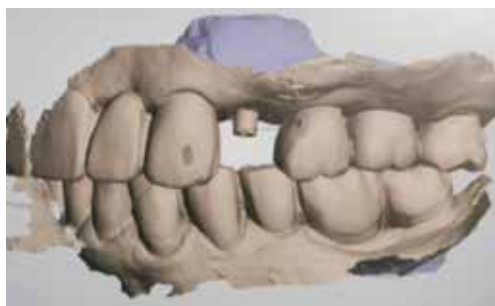

Fig.15 Side view of the intraoral scan: Intraoral scanner (Trios) enables positioning of an implant and milling of prosthetics on the computer.

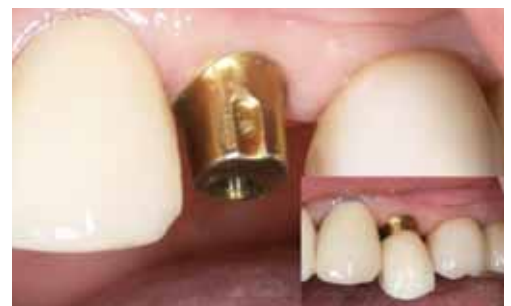

Fig.16 The customized abutment was fabricated without using a model.

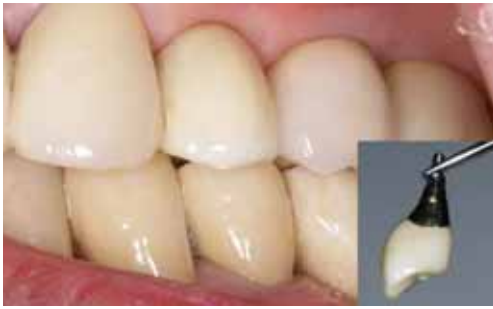

Fig.17 The final SCRП zirconia crown was delivered a week after the intraoral scanning.

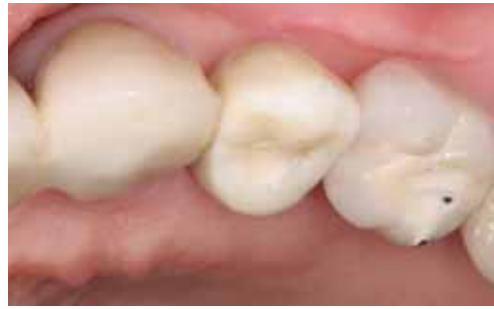

Fig.18 Occlusal view shows the screw hole filled with composite.

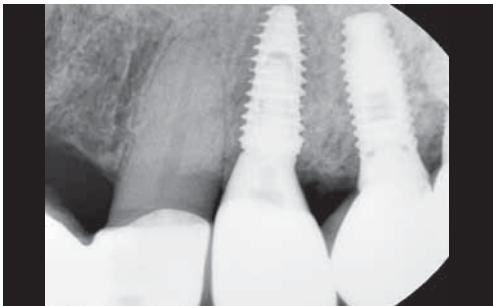


Fig.19 Periapical view of the final prosthesis.

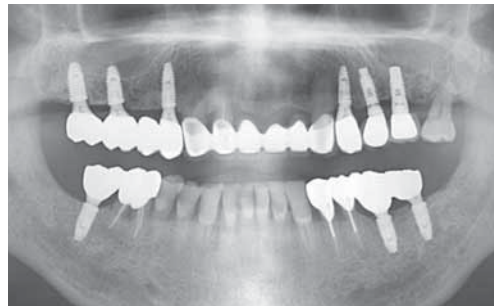


Fig.20 Radiographic panoramic view.

Immediate loading of anterior maxilla with Neo NaviGuide



Dr. Joong-Min Kim
DDS, MS, Ph.D



QR Code by Case

Patient Information

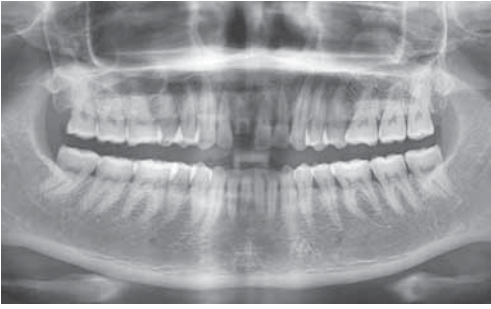
A 45-year-old, female.

Treatment Plan

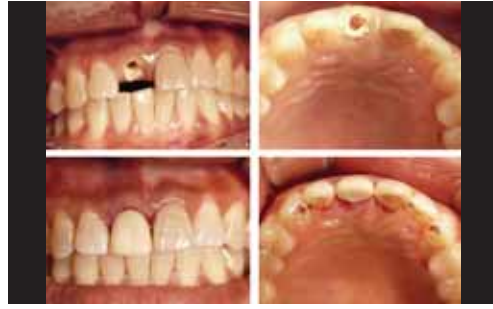1. Extraction of root rest. (#11)
2. flapless fixture (BIS4011A) installation with Neo NaviGuide kit.
3. bone graft with CalPore & autogenous bone obtained during drilling.
4. Immediate loading with custom abutment (hex) & acrylic temporary crown.

Tools that used in surgery

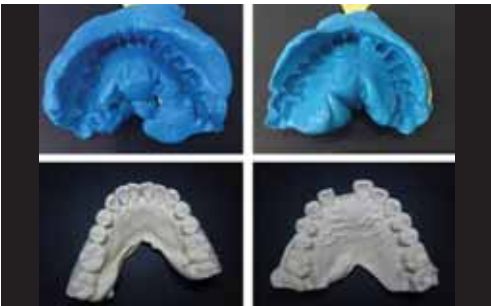
IS-II Active, Neo NaviGuide Kit



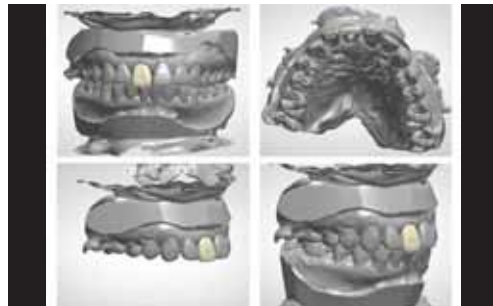| Fig.1



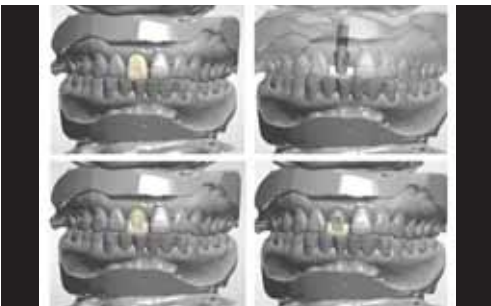
| Fig.2 Pre-operative & post-operative intra-oral photo.



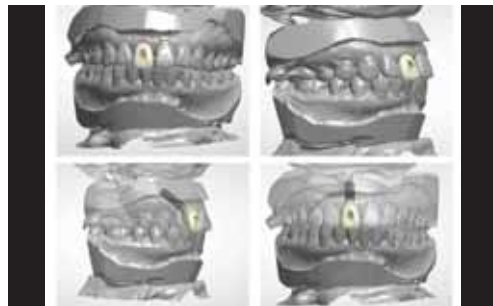
| Fig.3 Impression and Model for Neo NaviGuide.



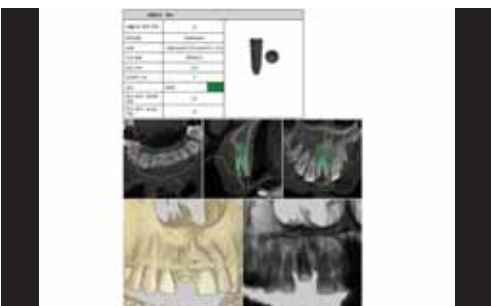
| Fig.4



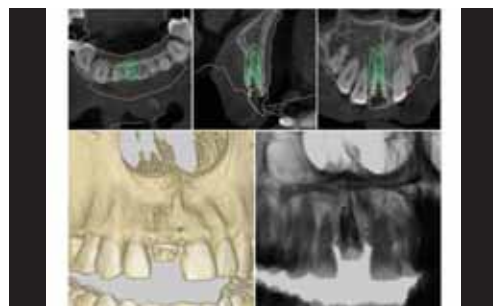
| Fig.5



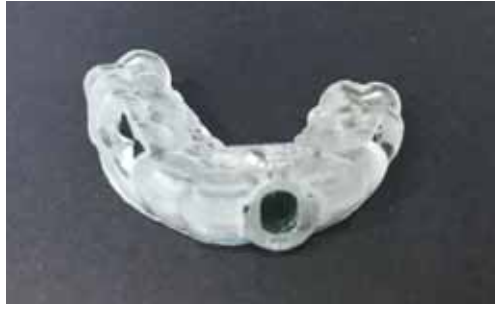| Fig.6 Pre-operative planning with Implant Studio.




| Fig.7 Surgical report.



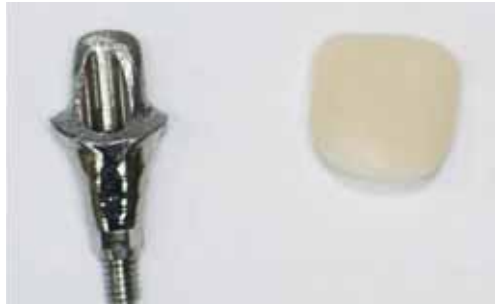| Fig.8 Surgical report.



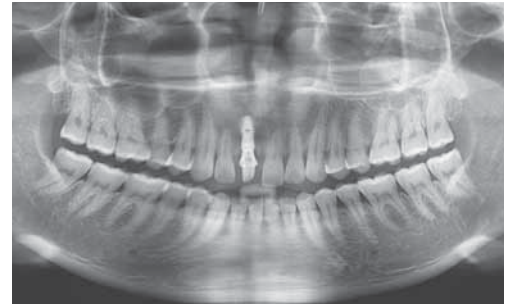| Fig.9 Surgical guide.



| Fig.10 3D printing model for temporary prosthesis.



| Fig.11 Custom abutment & temporary crown.



| Fig.12 Post-operative panorama.

Utilization of PickCap Impression Kit with mandibular anterior restorations



Dr. Chonghwa Kim
DDS, MS



QR Code by Case

Patient Information

A 61-year-old, male.

Chief complaint : "The bottom front teeth are mobile and painful on chewing."

Diagnosis : approximately 60-70% bone loss around the mandibular incisors. (#11)

Treatment Plan

1. Left side sinus graft with lateral approach and an 8 month waiting period for healing.
2. Sinus graft and implant placement #26 #27.
3. Implant placement #22, #35, #37, #45, #46, #47.
4. Implant placement after reduction of inferior part of the residual bone.
5. Restore all then teeth except #41, #42, #43.

Tools that used in surgery

IS-III active, PickCap Impression Coping, Neo Surgical Kit

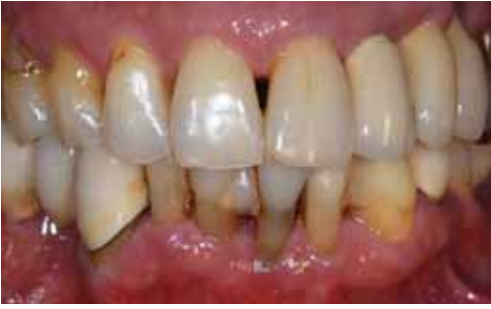

Fig.1

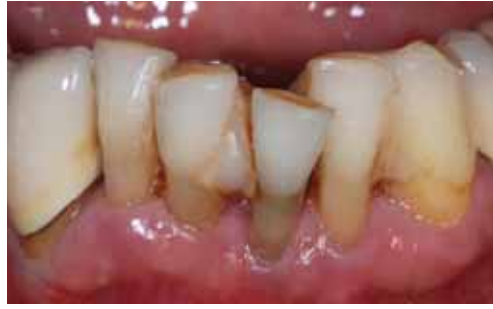

Fig.2

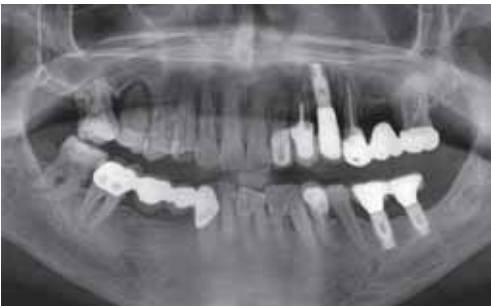

Fig.3

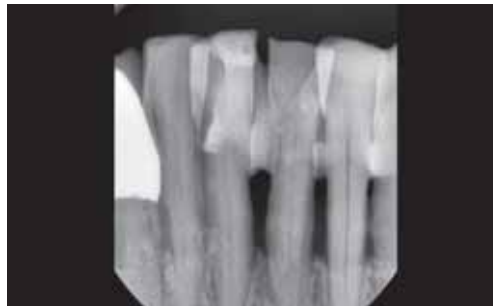


Fig.4

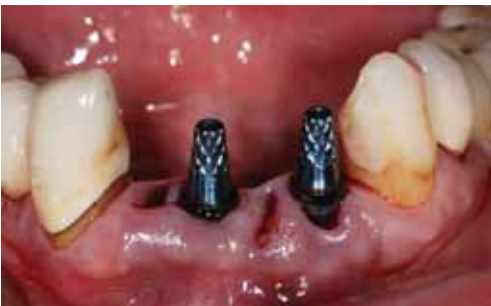

Fig.5 Two 3.5 x 13.0 mm implants were placed immediately after extractions. Implant direction pins were connected for verification of fixture alignment.

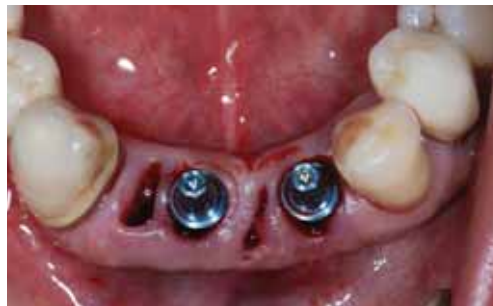

Fig.6 ISQ values were measured at 4 different locations of each implant at the time of surgery. #32 : 67/71/67/71, #41: 68/71/71/69.

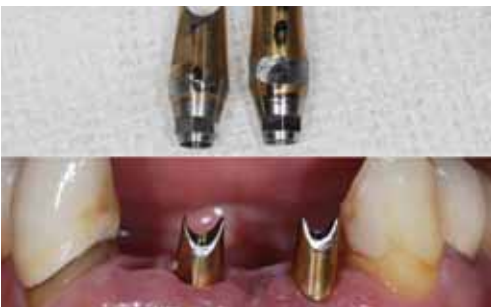

Fig.7 Prefabricated abutments were modified to be used to fabricate provisional restorations.

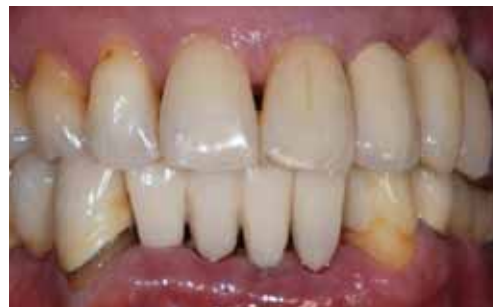

Fig.8 3 days post-op.

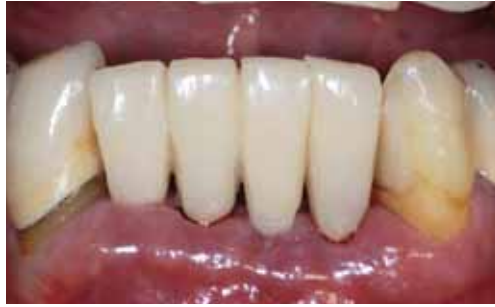

Fig.9 Close-up of provisional restorations.

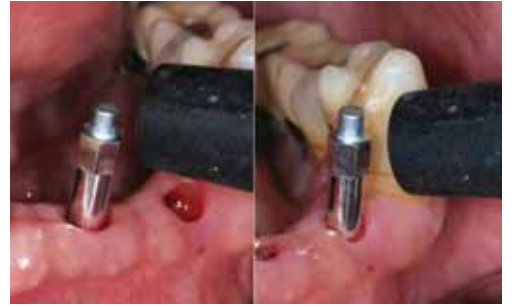

Fig.10 ISQ value was measured at 10th week.
#32 : 67/65/68/67, #41: 73/72/73/73.

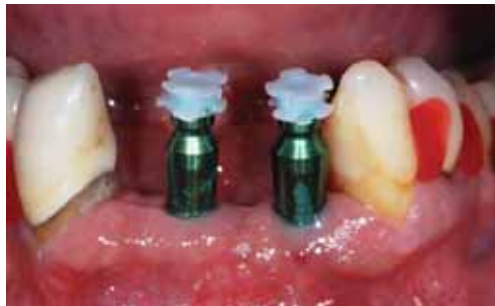

Fig.11 Impression was made using PickCap system.

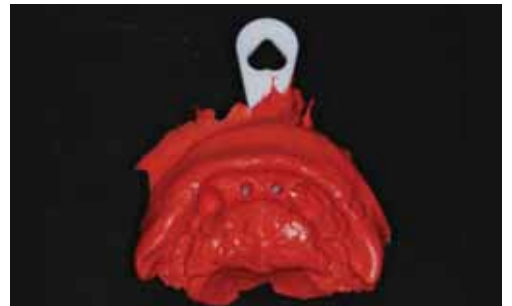

Fig.12

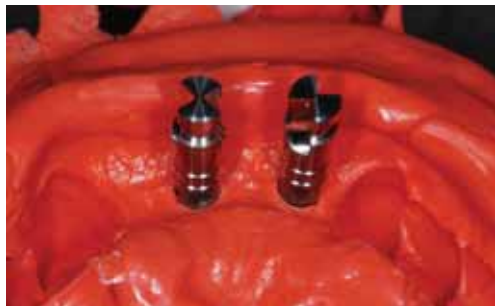

Fig.13 Lag analogs are positioned in impression.

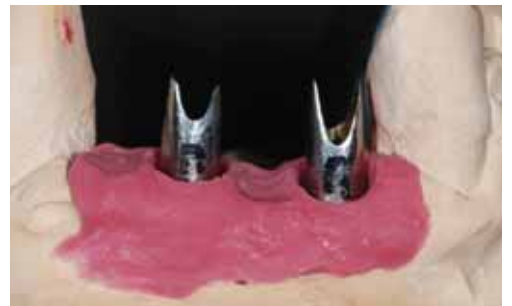

Fig.14 New set of prefabricated abutments were prepared for final restorations.

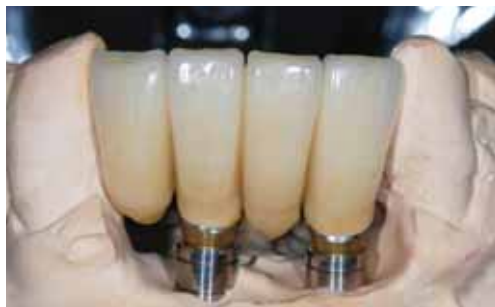

Fig.15 Final restorations on the working cast.

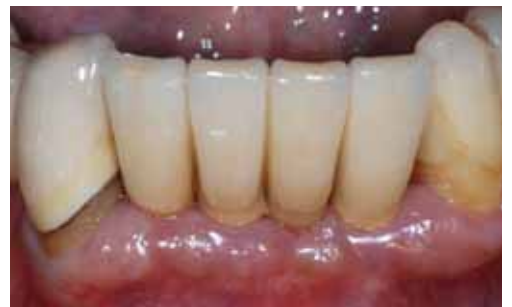

Fig.16 Intraoral view of the final restorations.

Immediate implant placement using the Neo NaviGuide in the maxillary anterior site

Dr. Young-Ku Heo
DDS, MSD, Ph.D



QR Code by Case

Patient information

47 years old / Male.

Treatment Plan

1. Immediate placement following the extraction of #11, 13, 22 and 23.
2. Preparing Neo NaviGuide for accurate path of implant placement.
3. Use of bone trimmer if flattening the bone is needed.
4. Bone grafting if needed.
5. One-stage approach if possible.

Tools that used in surgery

IS-III active, Neo NaviGuide Kit, Bone Trimmer, Bone Profile

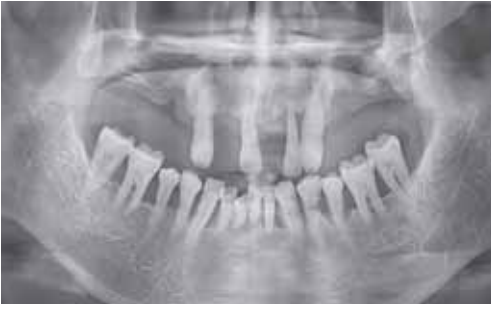

Fig.1 Pre-op panorama.

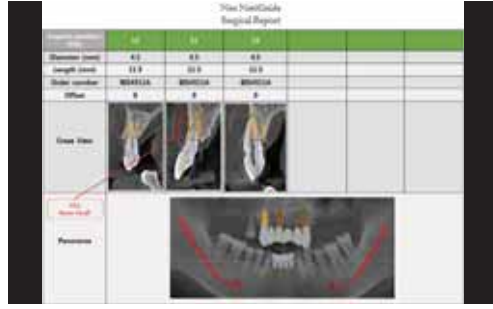


Fig.2 It was planned to immediately place implants following the extraction of #11, #13, #22 and #23.

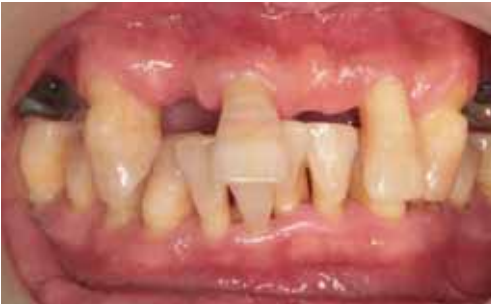

Fig.3 Intra-oral photograph.

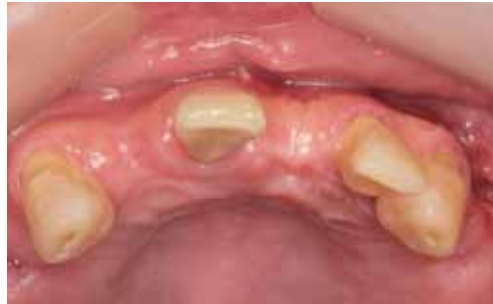

Fig.4 Intra-oral photograph.

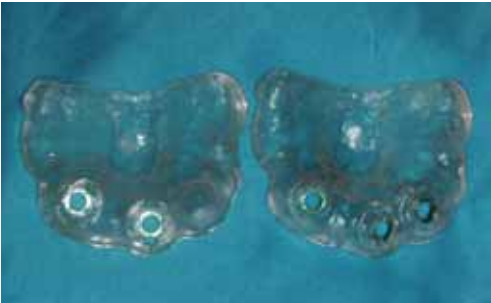

Fig.5 Precision Neo NaviGuide were fabricated.

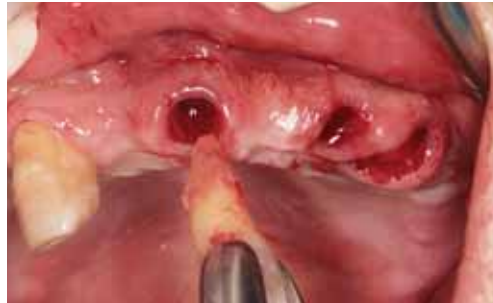

Fig.6 #11 was extracted.

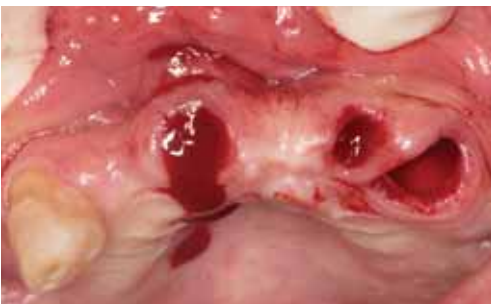

Fig.7 Immediately after the extraction of #11, #22 and #23.

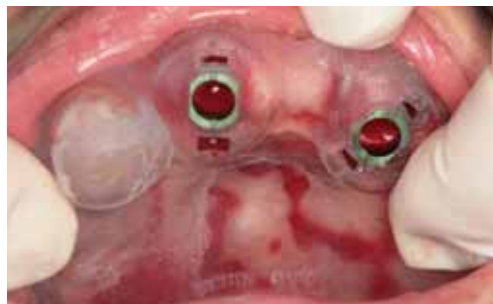

Fig.8 The Neo NaviGuide was placed in the mouth.

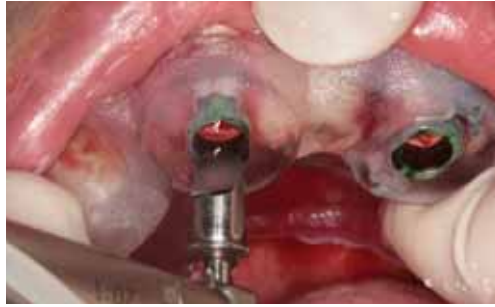

Fig.9 Bone trimmer was used removing residual alveolar bone and flattening the bone level.

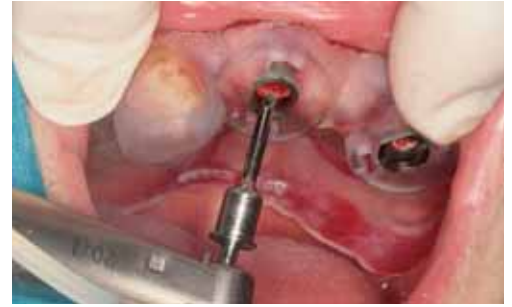

Fig.10 Ø2.2 drill. (200rpm)

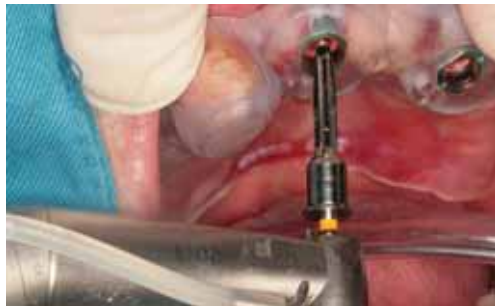

Fig.11 Ø3.0 drill. (50rpm)

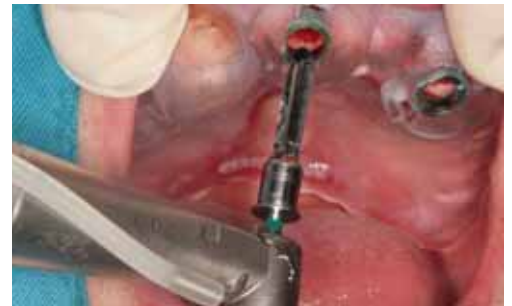

Fig.12 Ø3.5 drill. (50rpm)

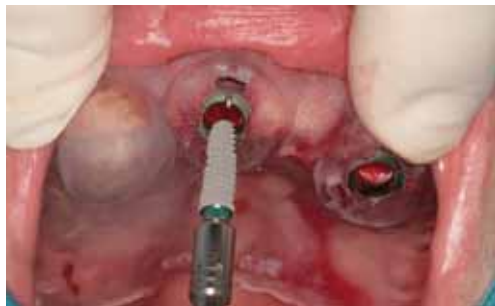

Fig.13 Neobiotech IS-III active 4.0*13mm fixture was placed in the area of #11.

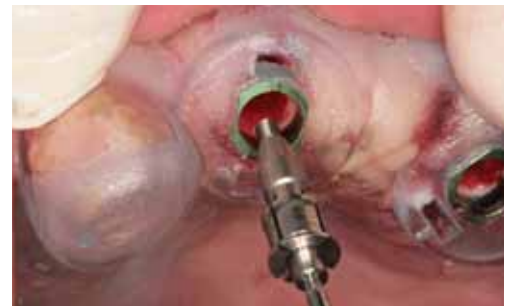

Fig.14 Fixing the Neo NaviGuide, with vertical anchor (in fixture) connected to the fixture.

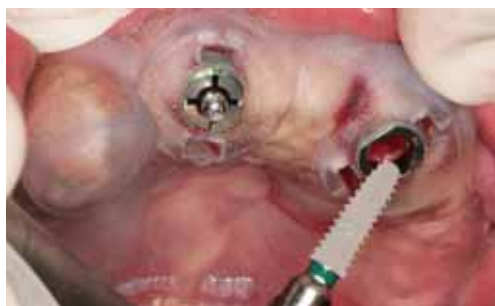

Fig.15 Neobiotech IS-III active 4.0*13mm fixture was placed in the area of #23.

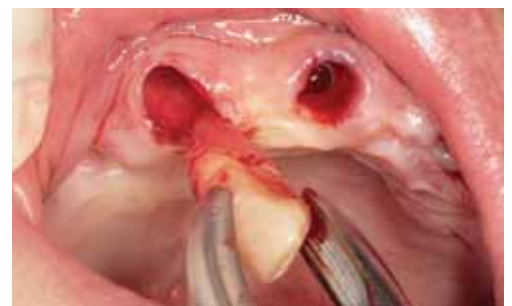

Fig.16 #13 was extracted.

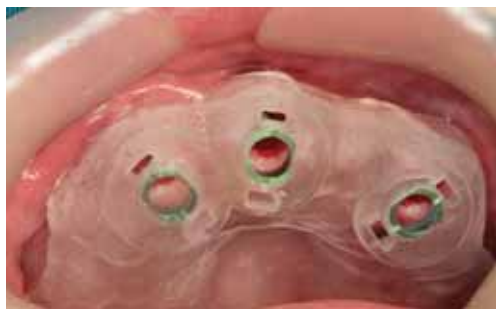

Fig.17 The Neo NaviGuide was placed in the mouth.

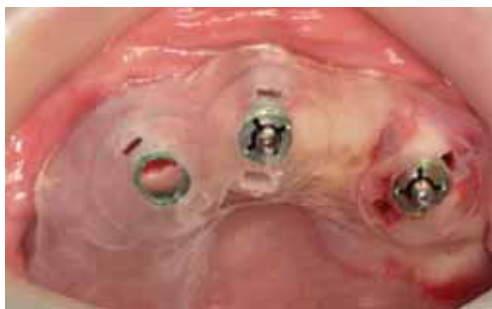

Fig.18 Fixing the Neo NaviGuide, with vertical anchor(in fixture) connected to the fixture.

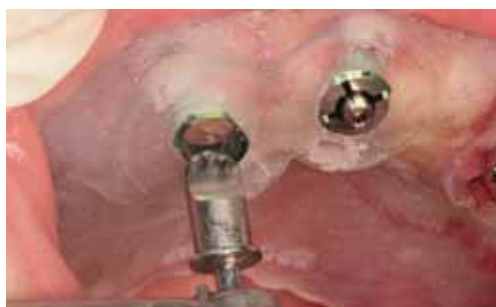

Fig.19 Bone Trimmer. (200rpm)

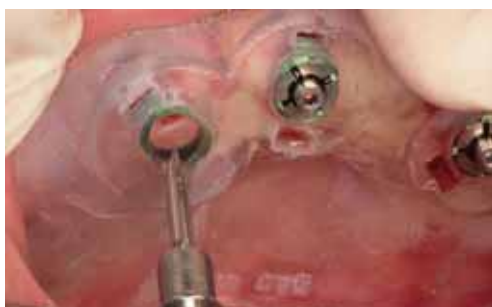

Fig.20 Ø2.2 drill. (200rpm)

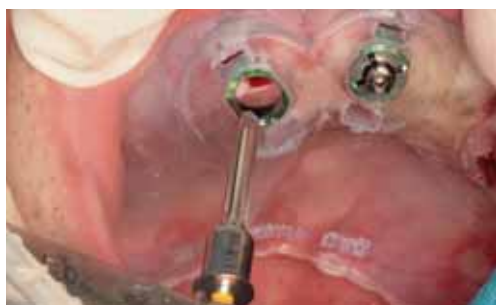

Fig.21 Ø3.0 drill. (50rpm)

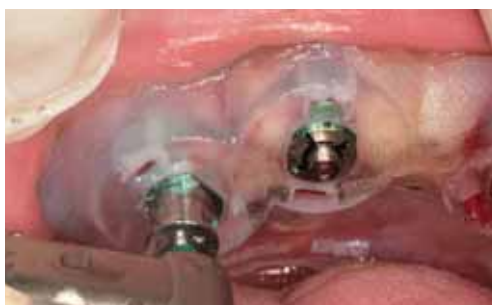

Fig.22 Ø3.5 drill. (50rpm)

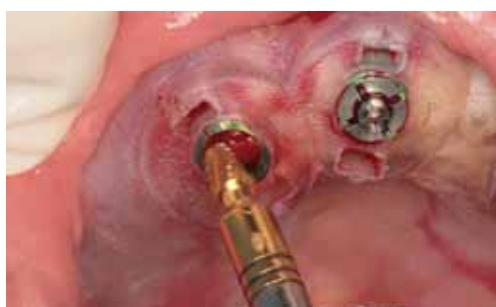

Fig.23 Ø3.5 drill. (50rpm)

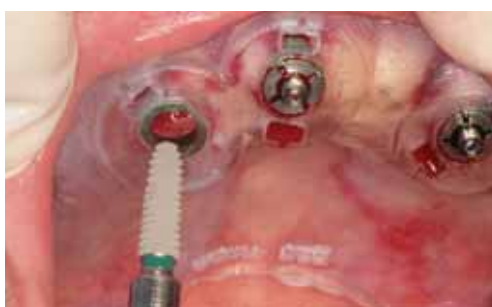

Fig.24 Neobiotech IS-III active 4.0*13mm fixture was placed in the area of #13.

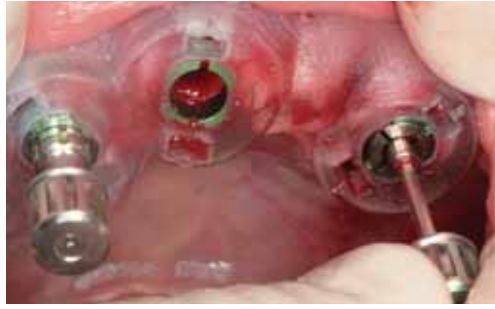

Fig.25 Removed vertical anchor with a hex driver.

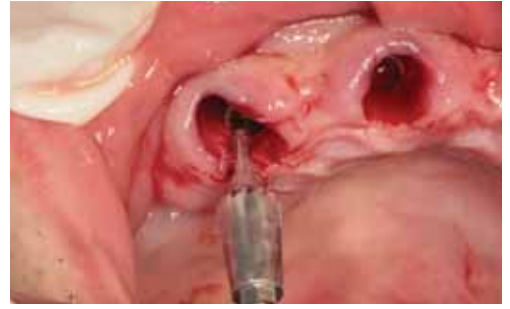

Fig.26 Surrounding bone was trimmed with a bone profile. (50rpm)
Must use Bone Profile after removing the guide.

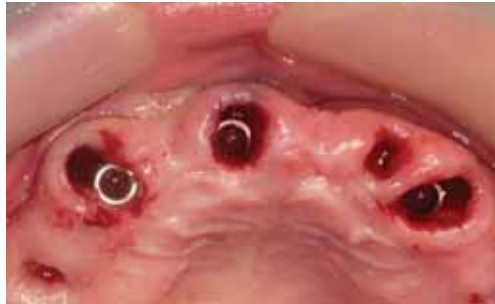

Fig.27 3 implants were placed successfully.

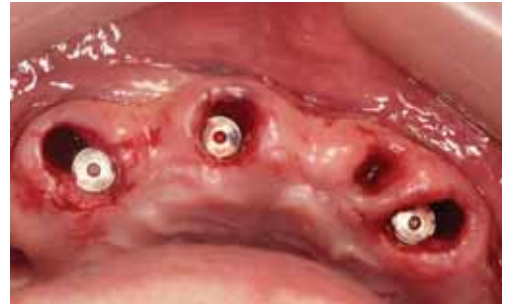

Fig.28 Cover screws were connected to the fixtures.

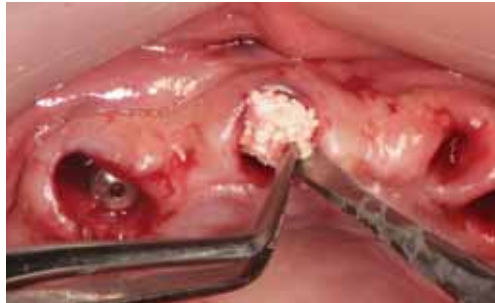

Fig.29 Bone graft was performed.

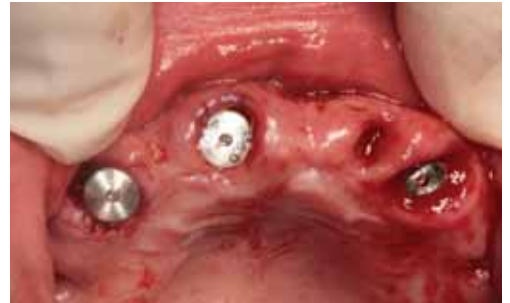

Fig.30 Healing abutments were connected to the fixtures.

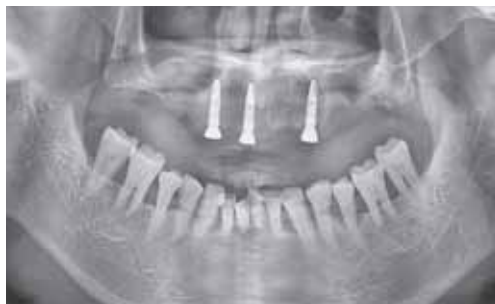

Fig.31 Post-op panorama.

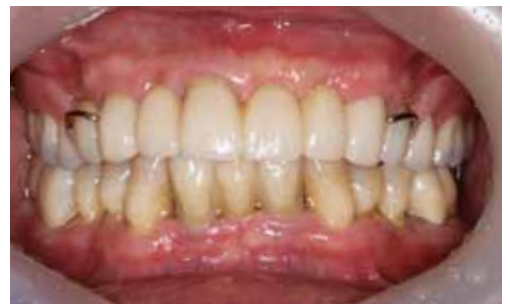

Fig.32 Final prosthesis after 5 months.
(zirconia fixed denture)

CASE 1. Implant placement using the Neo NaviGuide in the Maxillary 2nd Premolar Area

Yongkwan Choi
DDS, MSD, Ph.D



QR Code by Case

Patient information

Case 01. 49 years old / Male.

Treatment Plan

Case 01.

1. Implant placement of #15 using surgical stent.
2. Placing a healing abutment.
3. Delivery of final prosthesis. (SCRIP type)

Tools that used in surgery

IS-II Active, Neo NaviGuide Kit, PickCap Impression Coping

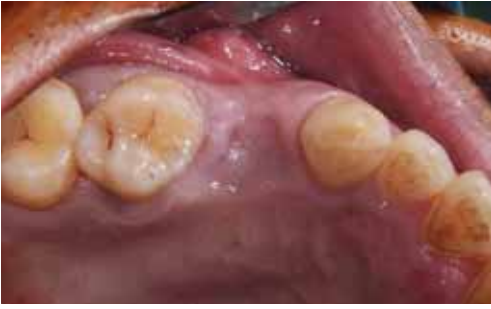

Fig.1 Implant placement using the Neo NaviGuide in the Maxillary 2nd Premolar Area.

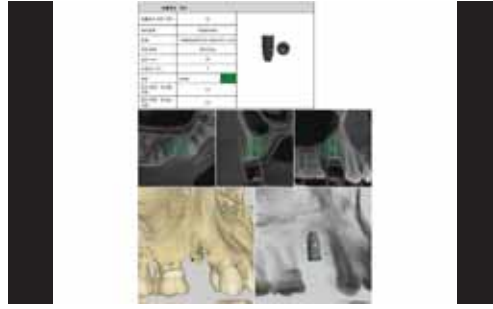


Fig.2 Surgical report.

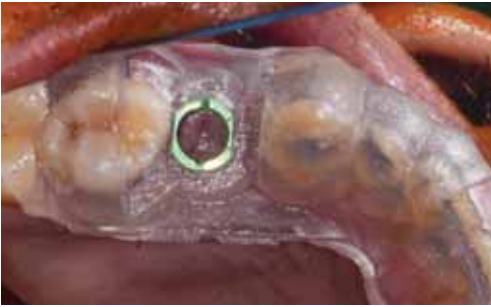

Fig.3 Surgical guide application.

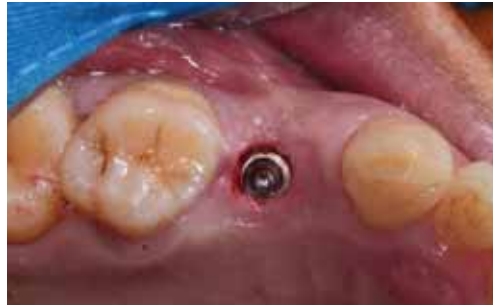

Fig.4 Implant placement by surgical stent.

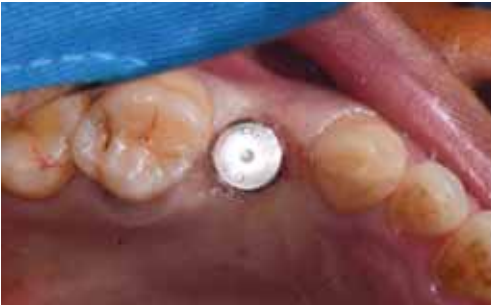

Fig.5 Healing abutment. (no suture)

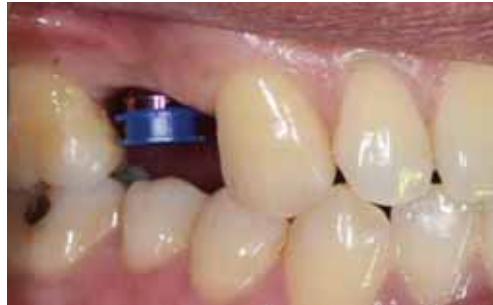

Fig.6 Bite tray impression using PickCap.

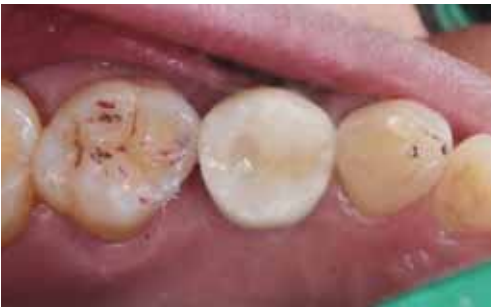

Fig.7 Implant crown restoration. (SCR type)

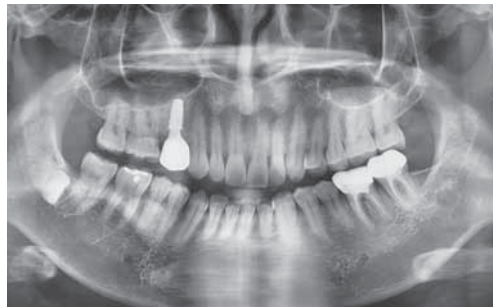

Fig.8 A panoramic radiograph after the final delivery of the prosthesis.

NEO-NAVIGUIDE usage in compromised bone width of All-on-4 case with NEOBIOTECH implant

Dr. MONGKOL THAVEEPRUNGSIPORN
DDS



QR Code by Case

Patient Information

A 59-year-old, female, Healthy Australian patient.

Treatment Plan

1. 1st appointment : All remaining teeth extraction & 4 Lower implants placement.
2. 2nd appointment : Upper implants placement.
3. 3rd appointment : Try-in framework & bite registration.
4. 4th appointment : Upper & Lower Teeth Try-in.
5. 5th appointment : Upper & Lower Teeth insertion.
6. 6th appointment : Recheck. (after insertion 1 day)

Tools that used in surgery

IS-III Active, Transfer Impression Coping, Neo NaviGuide Kit

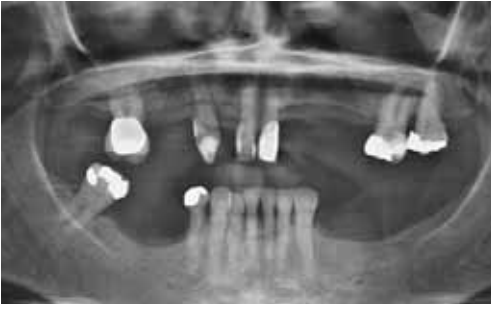

Fig.1 This case presents full mouth teeth replacement with All-on-4 concept treatment.

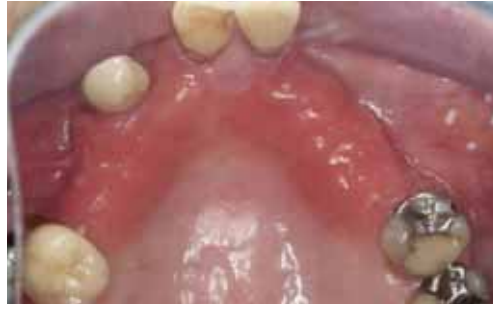

Fig.2 Preoperative Photographs.

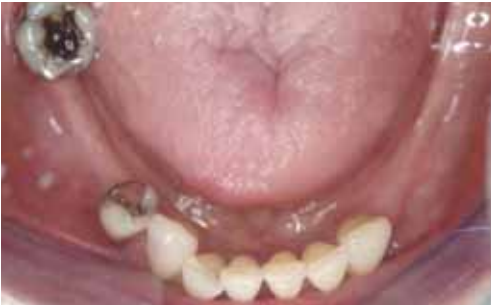

Fig.3 Preoperative Photographs.

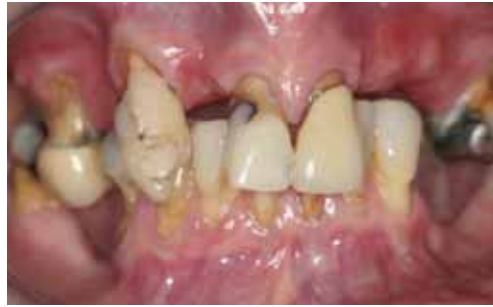

Fig.4 Preoperative Photographs.

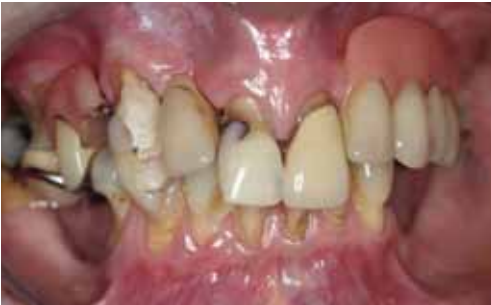

Fig.5 Preoperative Photographs.

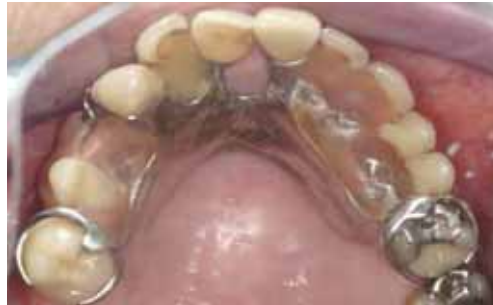

Fig.6 Preoperative Photographs.

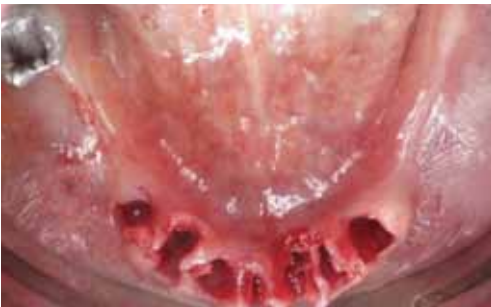

Fig.7 1st appointment : All remaining teeth extraction & 4 Lower implants placement.

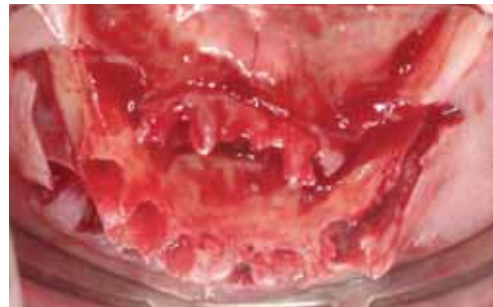

Fig.8 1st appointment : All remaining teeth extraction & 4 Lower implants placement.

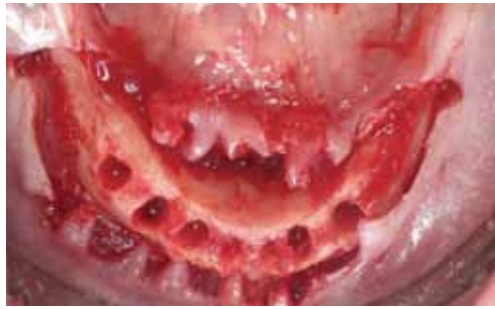

Fig.9 1st appointment : All remaining teeth extraction & 4 Lower implants placement.

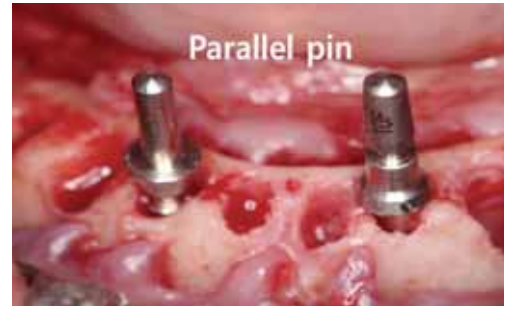

Fig.10 2 diameter sizes in 1 Parallel pin.

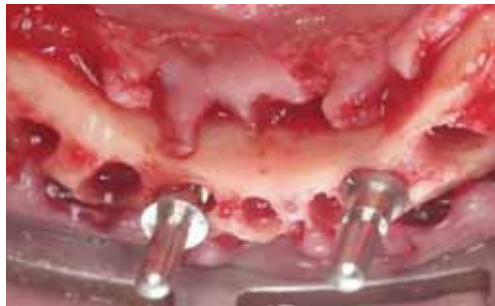

Fig.11 2 diameter sizes in 1 Parallel pin.

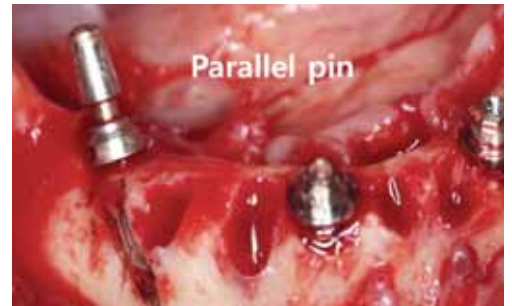

Fig.12 17 Tilted distal implant Q4.

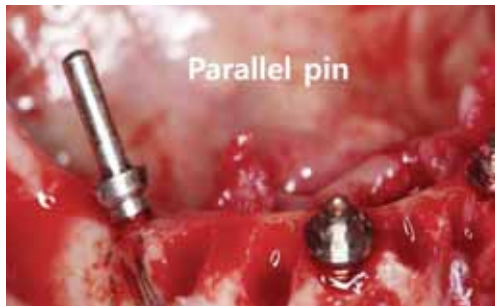


Fig.13

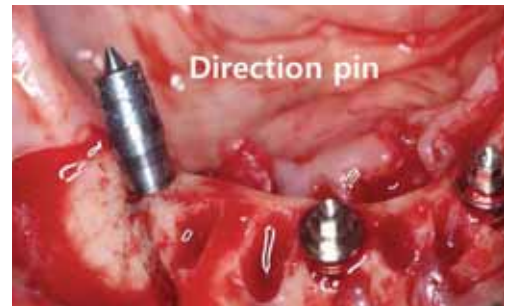

Fig.14

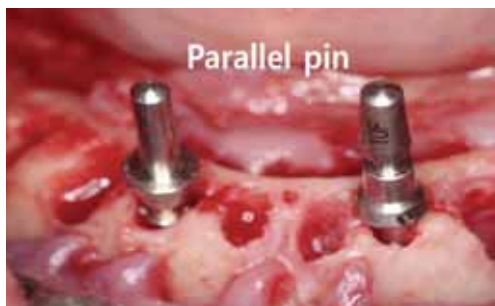

Fig.15 2 diameter sizes in 1 Parallel pin.

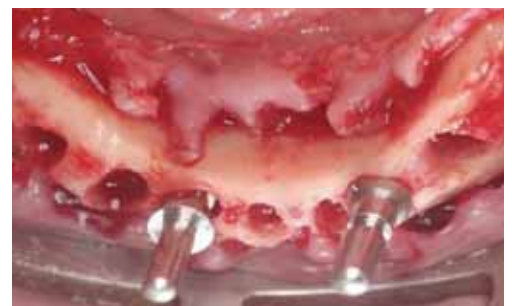

Fig.16 2 diameter sizes in 1 Parallel pin.

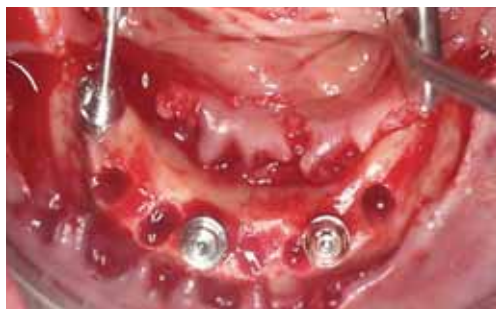

Fig.17 Multiunit Angled Abutment : Different point of engagement = Different prosthesiss screw hole axis.

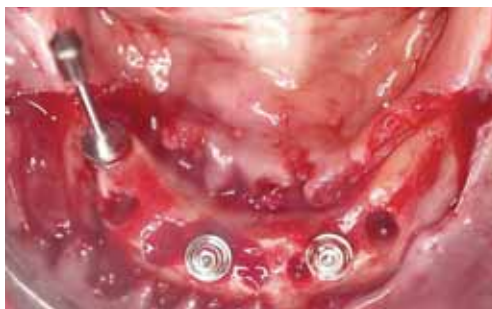

Fig.18

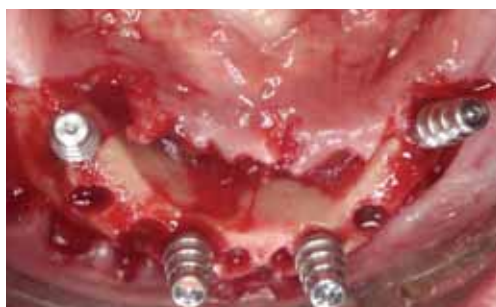

Fig.19 Closed tray impression technic with Transfer impression coping.




Fig.20 GBR with Sticky bone + CGF.

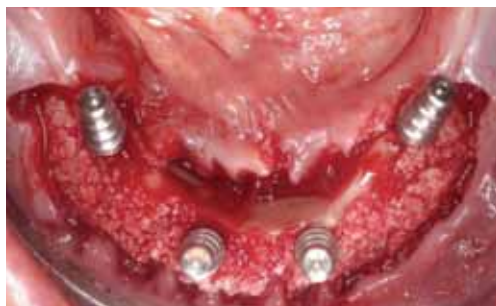

Fig.21

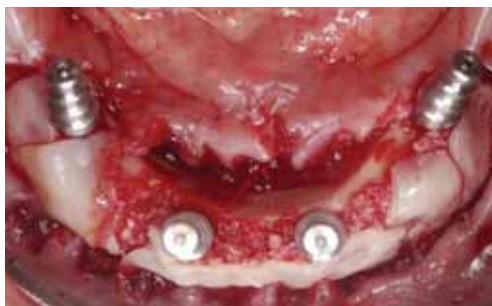

Fig.22

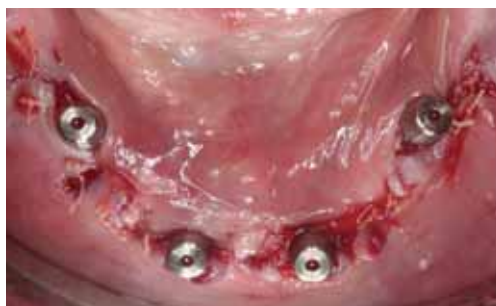

Fig.23 After operatio.

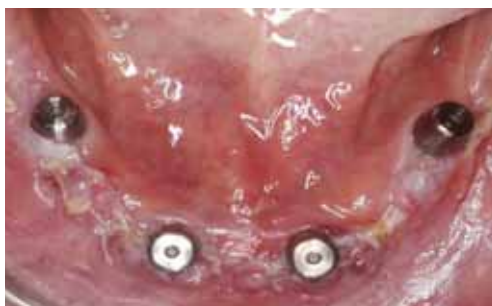

Fig.24 After 1 day.

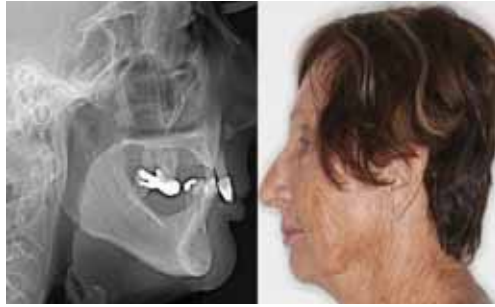

Fig.25 2nd appointment : Upper implants placement : In Skeletal Class 2 patient, one of concern is... "Upper front screw access holes on Screw-retained implant restoration".



Fig.26 Surgical guide + NEO NAVIGUIDE Kit drilling.

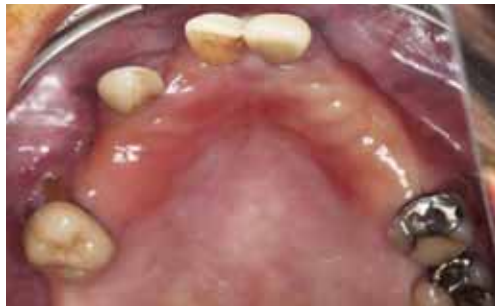

Fig.27



Fig.28 Surgical guide for upper jaw.



Fig.29

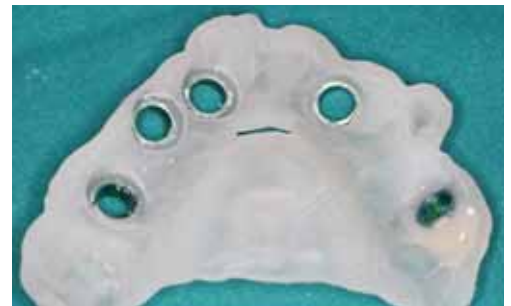

Fig.30

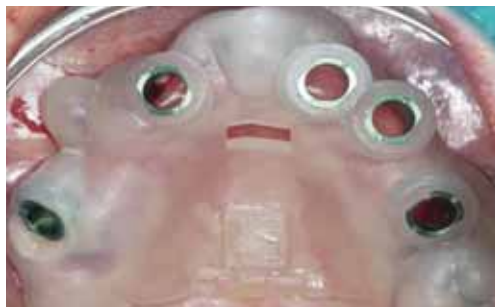

Fig.31 Surgical guide for upper jaw.

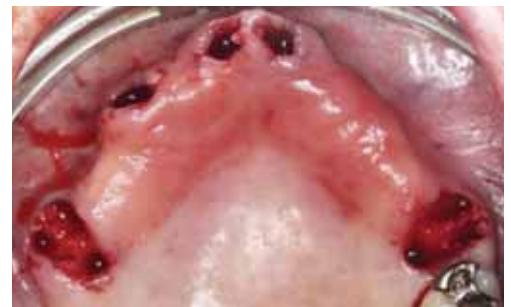

Fig.32

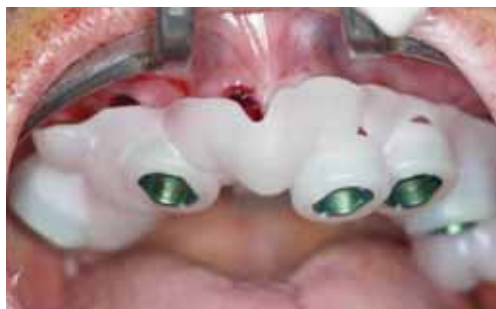

Fig.33

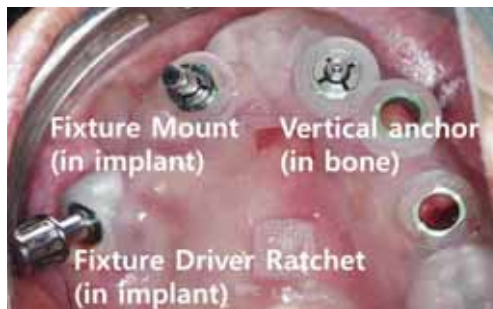


Fig.34 Main concern: Surgical Guide stability during drilling.

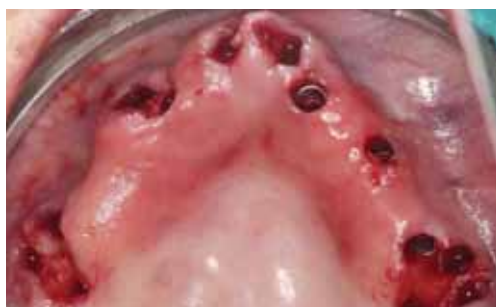

Fig.35 After 5 dental implants placement with NEO NAVI GUIDE. (Surgical guide usage for Proper position of implant placement)

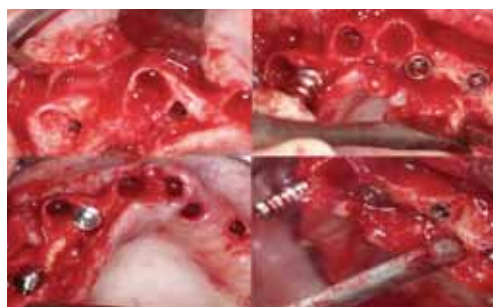

Fig.36 Compromised bone width can be augmented with bone graft materials after placement.

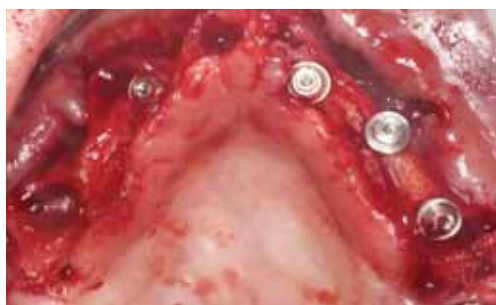

Fig.37 3 front dental implants:Multi unit straight abutment2 distal dental implants:Multi units angled abutment.

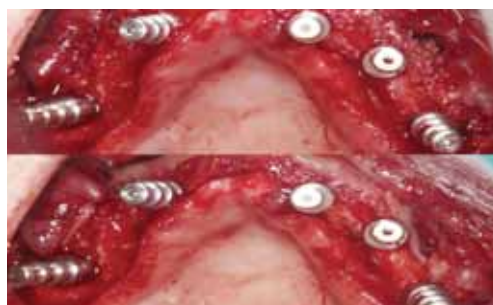

Fig.38 GBR & Socket grafting with Sticky bone (AFG + particulate bone) & CGF.

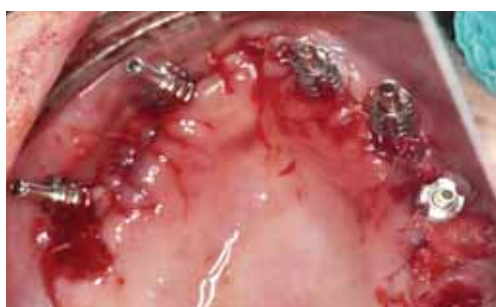

Fig.39 Open tray impression technic with pick-up impression coping.

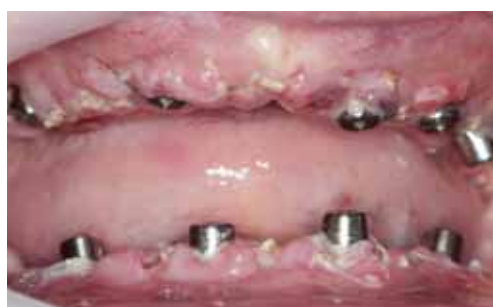
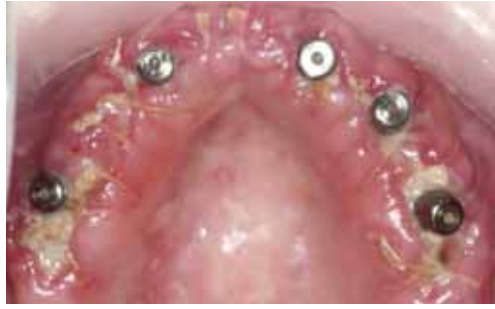
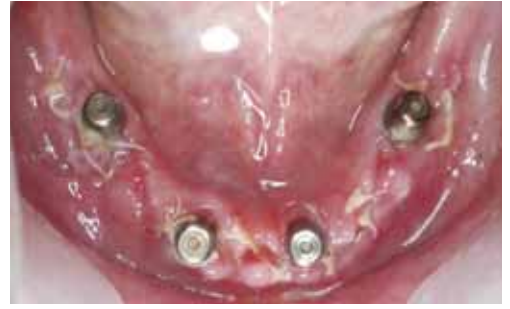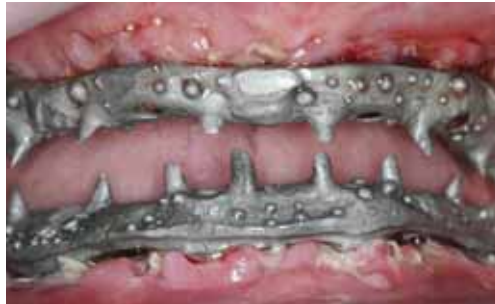Fig.40 3rd appointment : Try-in framework & bite registration : Upper jaw: After operation 1 dayLower jaw: After operation 2 days.



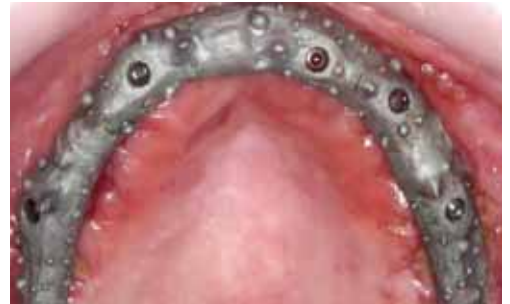| Fig.41 After operation 1 day.



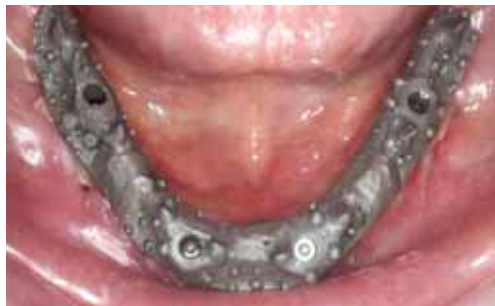| Fig.42 After operation 2 days.



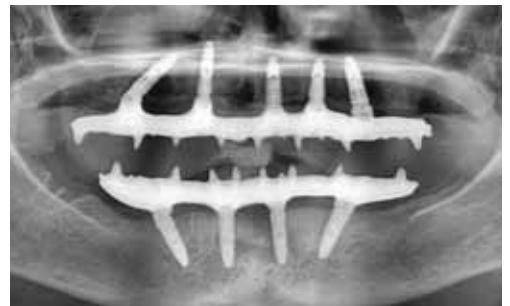| Fig.43 Try-in U&L metal framework.



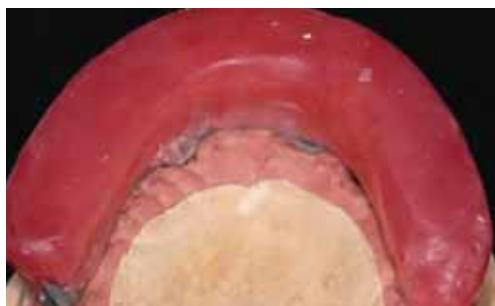| Fig.44



| Fig.45



| Fig.46 Fit checking of U&L metal framework by Panoramic X-ray + Bite registration.



| Fig.47



| Fig.48

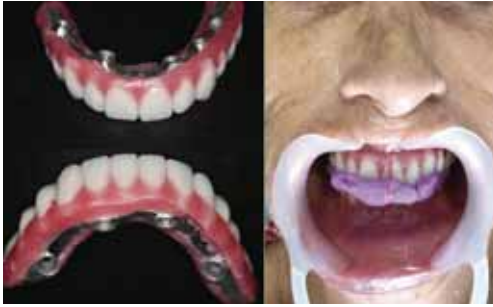

Fig.49 4th appointment : Upper & Lower Teeth Try-in : RE-BITE for mid-line correction.

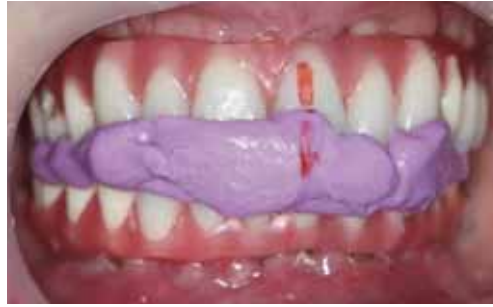

Fig.50

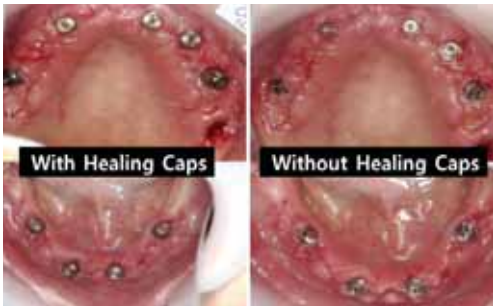

Fig.51 5th appointment : Upper & Lower Teeth insertion : Upper : After 10 days Lower: After 11 days.

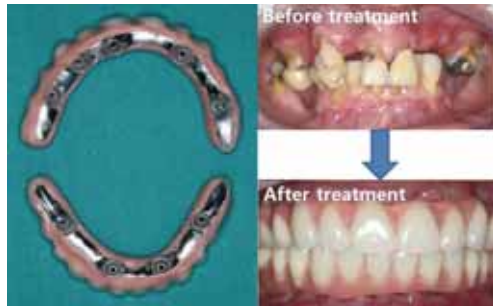

Fig.52 Smile line observation.

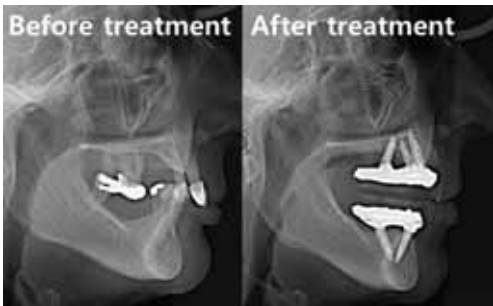

Fig.53 Observe Soft tissue profile & Maxillomandibular angle.

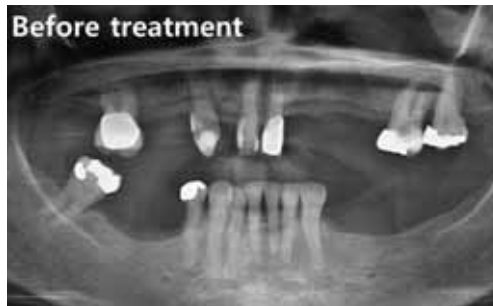

Fig.54

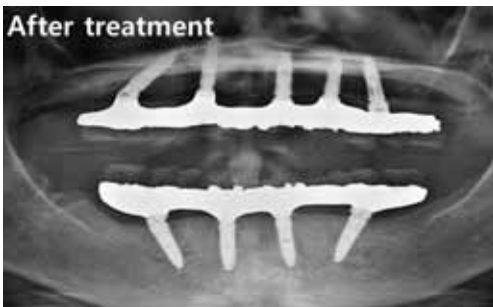

Fig.55

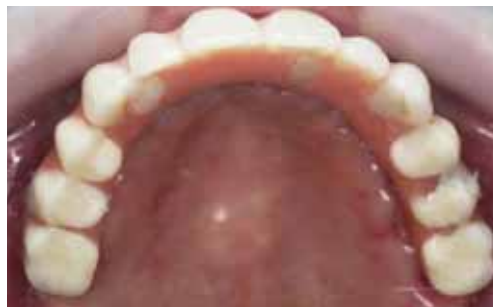

Fig.56 6th appointment : Recheck (after insertion 1 day) : After treatment.

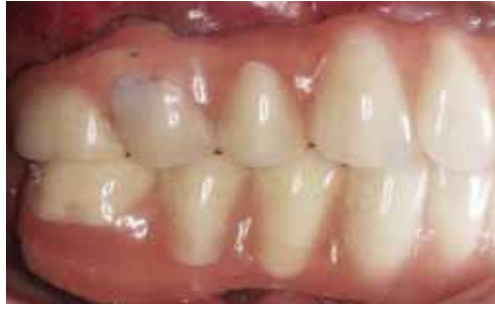

Fig.57 6th appointment : Recheck (after insertion 1 day) : After treatment.

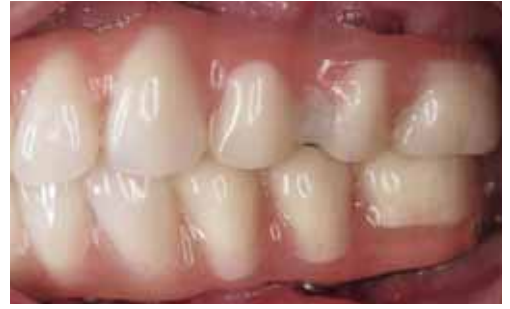

Fig.58 6th appointment : Recheck (after insertion 1 day) : After treatment.

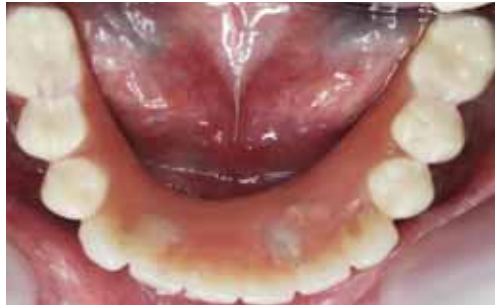

Fig.59 6th appointment : Recheck (after insertion 1 day) : After treatment.

Esthetic restoration to soft tissue defects in the anterior maxilla



Dr. MANUEL FEREGRINO MÉNDEZ
DDS



QR Code by Case

Patient Information

A 26-year-old, who received orthodontic treatment, where the ortho try to move the canine from the palatal, as you see, that was not possible, the canine and the lateral has a great mobility.

Tools that used in surgery

IS-II Active, ACM, Neo Surgical Kit

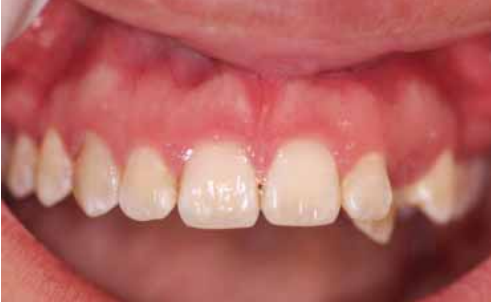

Fig.1 26 years old, who received orthodontic treatment, where the ortho try to move the canine from the palatal, as you see, that was not possible, the canine and the lateral has a great mobility.

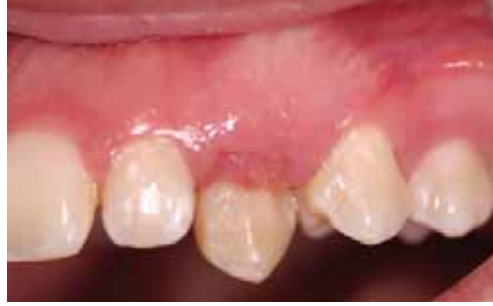

Fig.2 26 years old, who received orthodontic treatment, where the ortho try to move the canine from the palatal, as you see, that was not possible, the canine and the lateral has a great mobility.

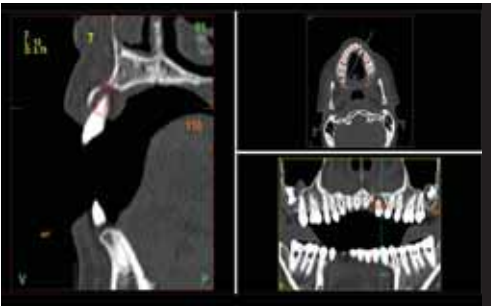


Fig.3 Tomography of the canine area.

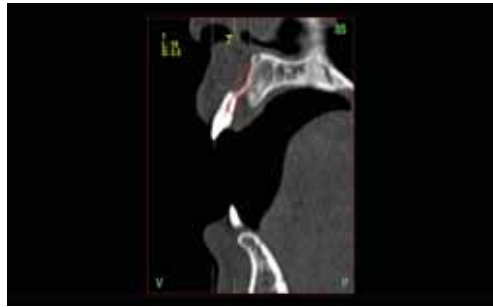


Fig.4 Tomography from the lateral.

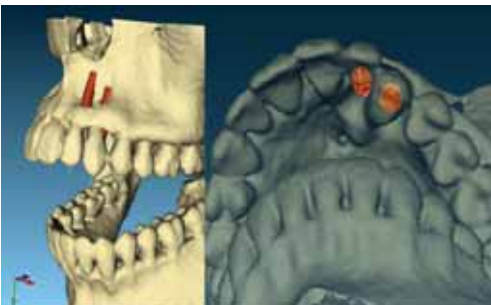


Fig.5

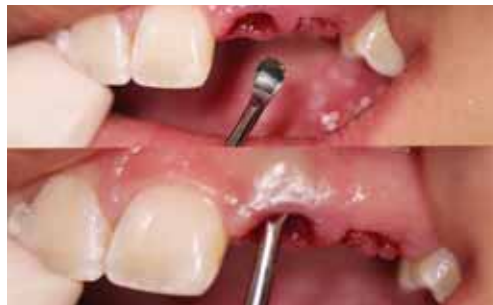

Fig.6 Extraction and socket cleaning.

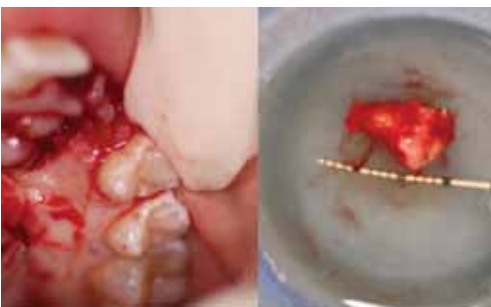

Fig.7 Soft tissue graft from the palate to fill the socket of the canine.

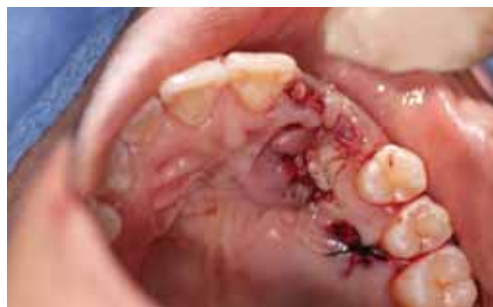
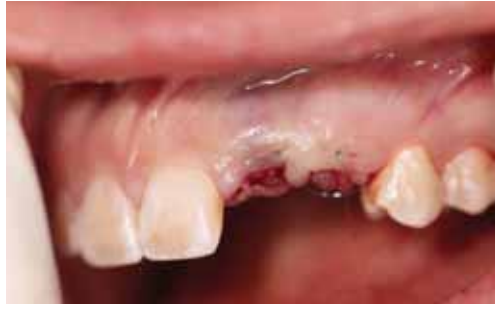
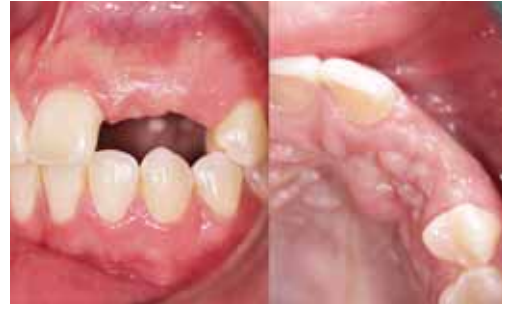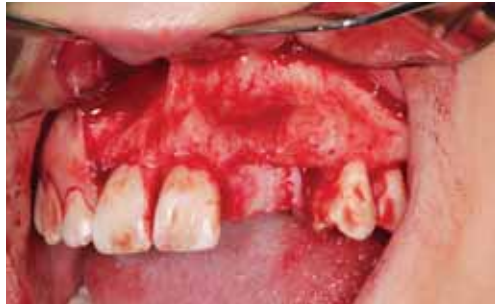Fig.8 Soft tissue graft was placed in the canine socket and PRGF clot in the lateral socket.



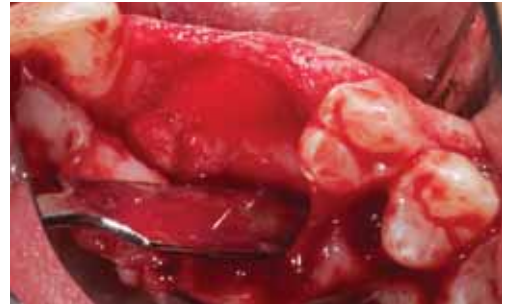| Fig.9



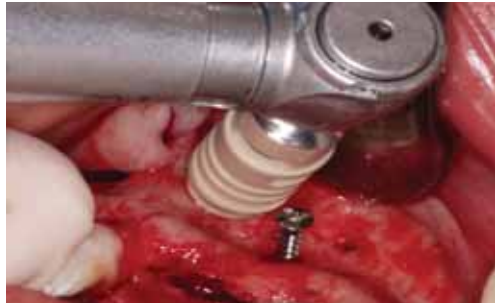| Fig.10 Healing at 2 months.



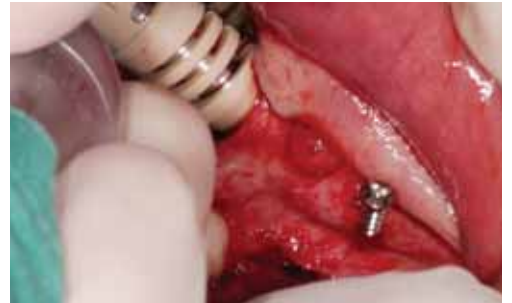| Fig.11 Flap reflection.



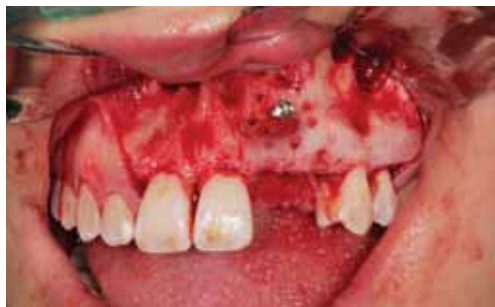| Fig.12



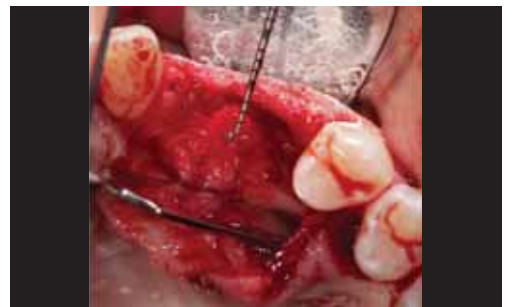| Fig.13 ACM recollecting.



| Fig.14 ACM recollecting.



| Fig.15



| Fig.16

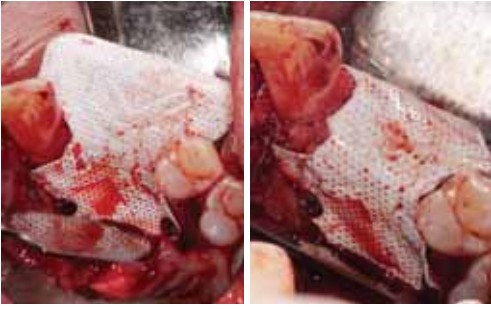


Fig.17 Eptf titanium reinforced non resorbable membrane.

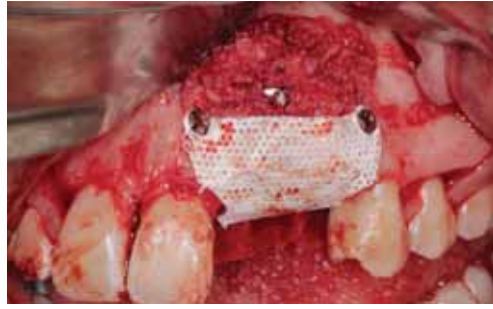

Fig.18

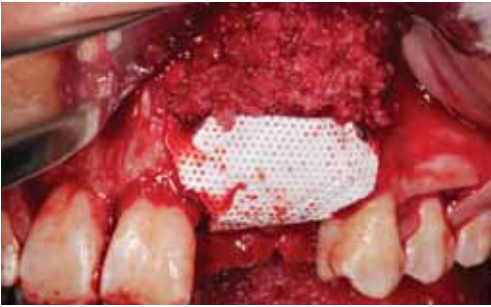


Fig.19 Collagen resorbable membrane placement at the bottom.

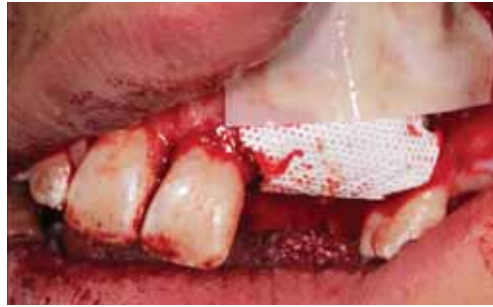

Fig.20 Collagen resorbable membrane placement at the bottom.

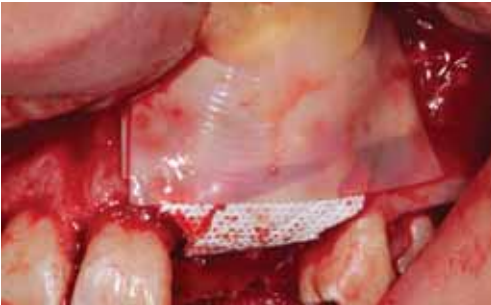

Fig.21

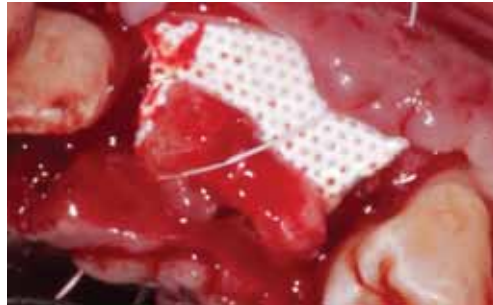

Fig.22

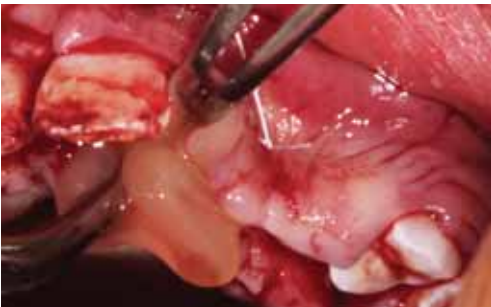

Fig.23

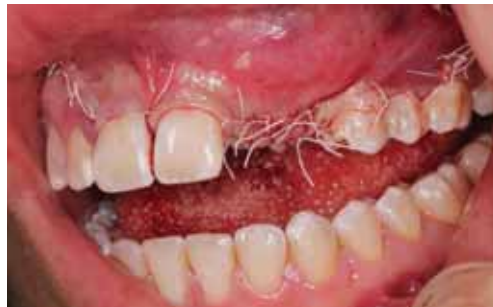

Fig.24 Horizontal mattress eptf suture.

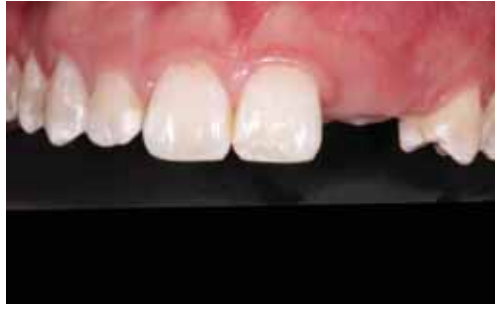

Fig.25 9 months after.

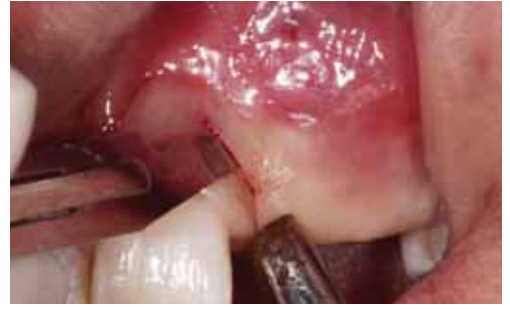

Fig.26 Reopening with 45 degree, for decrease the scar healing.

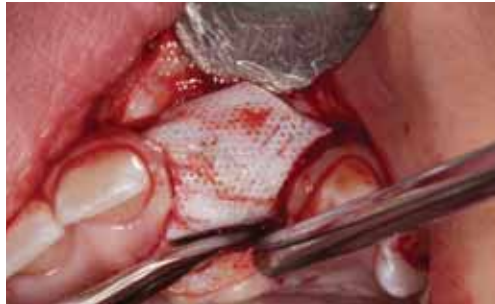

Fig.27

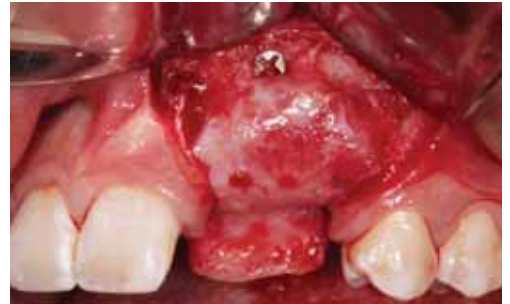

Fig.28

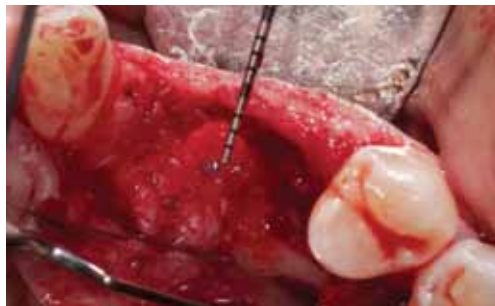

Fig.29 Before and 9 months later.

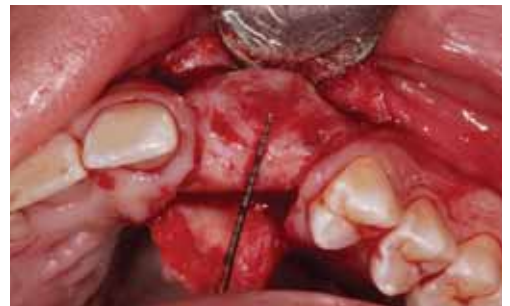

Fig.30 Before and 9 months later.

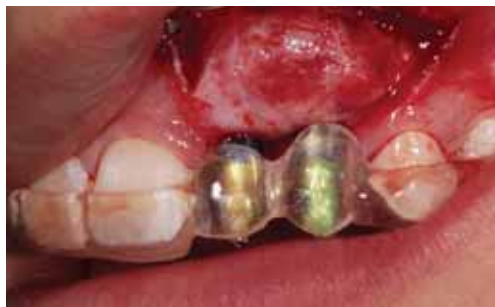

Fig.31 Surgical guide, to place 2 IS-II implants.

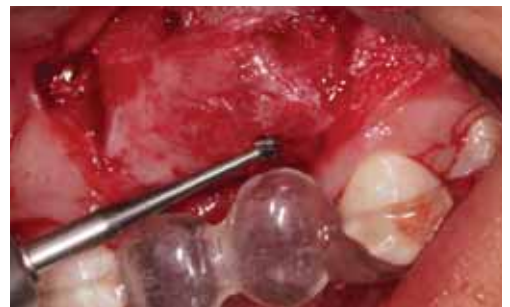

Fig.32 Removing bone until have 3 mm from crestal bone to gingival margin on the surgical guide.

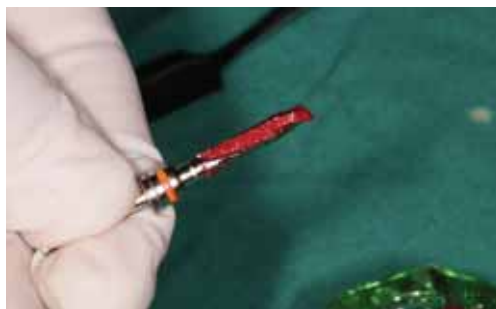

Fig.33 Biological drilling at 75 RPM to recollect autogenous bone.

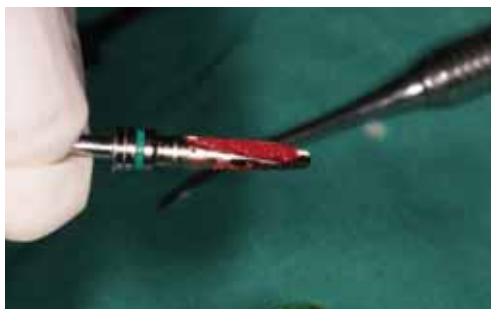

Fig.34 Biological drilling at 75 RPM to recollect autogenous bone.

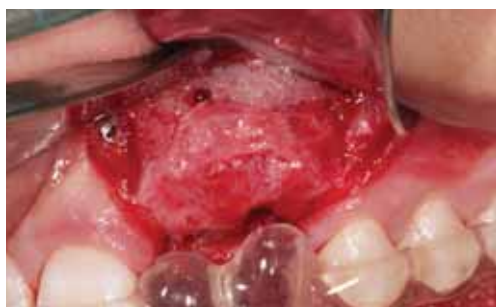

Fig.35 Implants placed with autogenous bone and PRGF.

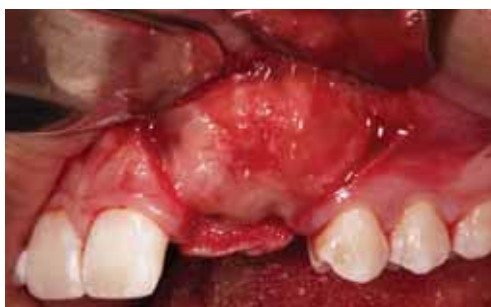

Fig.36 Implants placed with autogenous bone and PRGF.

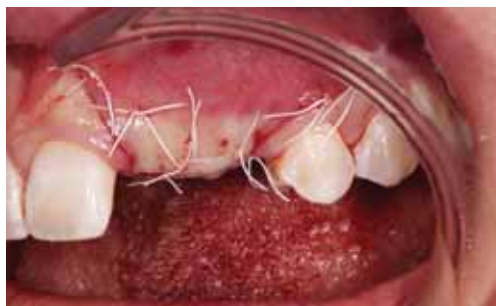

Fig.37

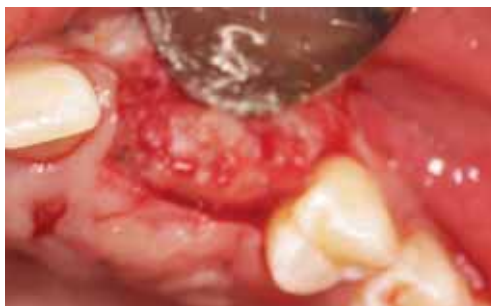

Fig.38 Uncover the implant 4 months later, you can see new bone formation over the implants platform.

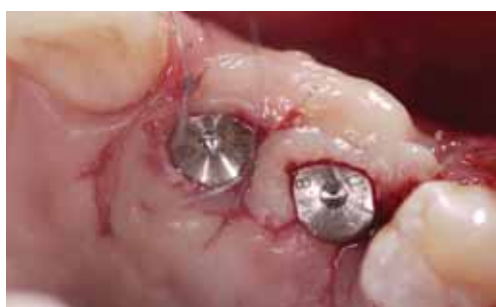

Fig.39 Uncover the implant 4 months later, you can see new bone formation over the implants platform.

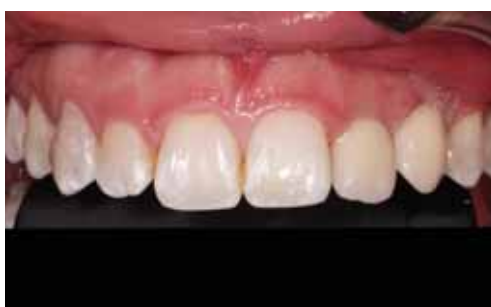
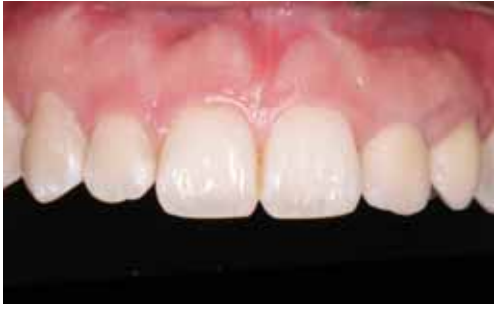
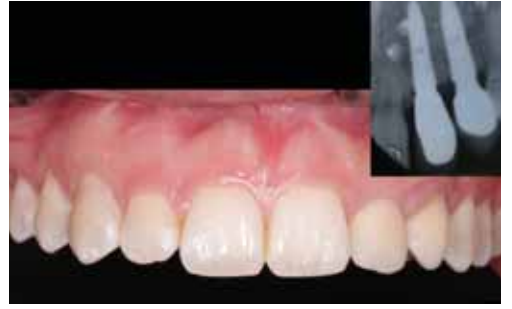Fig.40 Final prosthesis.



| Fig.41 4 years follow up.



| Fig.42 4 years follow up.



NEOBITECH
USER'S
CLINICAL
CASES

Neo
Biotech
Satisfaction to Dentists

www.neobiotech.com
Neobiotech Co., Ltd. E-space #1001, 36,
Digital-ro 27-gil, Guro-gu, Seoul, Korea, 152-789
Tel. +82-2-582-2885 Fax. +82-2-582-2883